

# Minimally Invasive “Crab-Shaped Fixation” for Treating Patients with Fragility Fractures of the Pelvis

Shin Yoshimura<sup>1)</sup>, Masahiro Inoue<sup>1)</sup>, Takayuki Nakajima<sup>1)</sup>, Go Kubota<sup>3)</sup>, Yusuke Sato<sup>1)</sup>, Takahito Arai<sup>4)</sup>, Sumihisa Orita<sup>2)</sup>, Yawara Eguchi<sup>2)</sup>, Kazuhide Inage<sup>2)</sup>, Yasuhiro Shiga<sup>2)</sup>, Atsuya Watanabe<sup>1)</sup>, Seiji Ohtori<sup>2)</sup> and Yasuchika Aoki<sup>1)</sup>

1) Department of Orthopaedic Surgery, Eastern Chiba Medical Center, Togane, Japan

2) Department of Orthopaedic Surgery, Graduate School of Medicine, Chiba University, Chiba, Japan

3) Department of Orthopaedic Surgery, Chiba Prefectural Sawara Hospital, Sawara, Japan

4) Department of Orthopaedic Surgery, Kanazawa Hospital, Yokohama, Japan

## Abstract:

**Introduction:** In the aging society, fragility fracture of the pelvis (FFP) has become a problem. Although strong and minimally invasive fixation is required in FFP surgery, reports on relevant surgical results are scarce. Crab-shaped fixation (CSF) is a spinopelvic fixation that involves reconstruction of the posterior pelvic ring using spinal instrumentation. This study aimed to evaluate the walking ability and perioperative complications of patients who underwent CSF for FFP.

**Methods:** We included patients diagnosed with unstable FFPs, including sacral fracture, who required hospitalization. Demographic data, such as age, sex, bone mineral density, and Rommens classification, were evaluated. Surgical findings included estimated blood loss, operation time, and perioperative complications. The improvement in postoperative walking ability was evaluated based on the length of the postoperative period before the initiation of walker training and whether walking aids were required at 6 months post-surgery, compared with those who received conservative treatment for FFP.

**Results:** Our study included 6 cases that received CSF and 16 cases that received conservative treatment, in which all were females and presented with sacral fractures. The average age of the surgical patients, the operation time, and the estimated blood loss were  $79.5 \pm 14.7$  years,  $180.7 \pm 28.7$  min, and  $124.2 \pm 29.4$  mL, respectively. The average length of the postoperative period prior to the initiation of walker training was  $10.8 \pm 12.3$  days, which was significantly shorter than that of conservative treatment. With regard to perioperative complications, poor reduction of fracture dislocation was observed in one case as well as surgical site infection in another case, but the walking ability improved in all cases.

**Conclusions:** We evaluated the results of the posterior pelvic ring reconstruction with CSF for patients with vertically unstable FFPs, including sacral fractures. CSF is minimally invasive and would be useful as it allowed walker training during the early postoperative period, which improved patients' walking ability even during the *in situ* pelvic ring reconstruction.

## Keywords:

Fragility fracture of pelvis, Crab-shaped fixation, Spino pelvic fixation, Osteoporosis, Rommens classification, minimally invasive surgery

Spine Surg Relat Res 2021; 5(6): 425-430

dx.doi.org/10.22603/ssrr.2020-0213

## Introduction

Fragility fractures are a problem associated with osteoporosis, where vertebral compression fractures, proximal femoral fractures, and distal radius fractures are well known as fragile fractures<sup>1)</sup>. Recently, the incidence of fragility fractures of the pelvis (FFPs) as one of the fragile fractures has been increasing. Between 1993 and 2010, there was a 24%

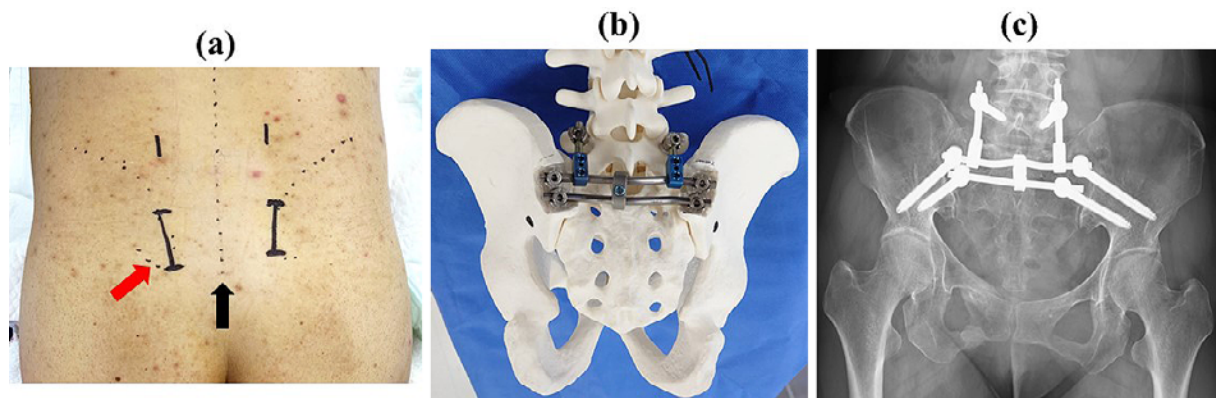
and 67% increase in the incidence of pelvic and acetabular fractures, respectively, in the United States alone<sup>2)</sup>. In addition, the mortality rate of these fracture types reached 16.3% 1 year later<sup>3)</sup>. FFPs are caused by bone fragility and are treated differently from pelvic ring injury following high-energy trauma.

The Rommens classification system is typically used to evaluate FFPs. In this classification system, FFPs are classi-

Corresponding author: Masahiro Inoue, masain\_96@hotmail.com

Received: November 20, 2020, Accepted: December 26, 2020, Advance Publication: February 9, 2021

Copyright © 2021 The Japanese Society for Spine Surgery and Related Research



**Figure 1.** (a) Indication of the skin incision. The black line indicates the skin incision, and the dotted line indicates the midline and iliac crest. The red arrow indicates PSIS. (b) Bone model after implant placement. (c) Postoperative pelvic X-ray. PSIS; posterior superior iliac spine

fied as types I-IV based on the degree of pelvic instability and sacral fracturing, which are characteristics of FFPs<sup>(4)</sup>. Moreover, the Rommens classification of FFPs usually determines the type of treatment provided. Typically, conservative therapy is provided for type I and II FFPs, whereas surgical therapy is considered in cases of type III and IV FFPs with vertical instability or for patients with persistent pain whose mobilization is apparently difficult<sup>(5-7)</sup>.

With regard to operative methods, posterior pelvic ring fixation is mainly performed. Because numerous patients with FFP have comorbidities and limited physiological reserves, invasive and long-term surgeries have non-acceptable risks for complications and enhanced mortality<sup>(8)</sup>. In addition, patients with FFP exhibit bone fragility, and their fractures gradually progress<sup>(9,10)</sup>. Therefore, fixation needs to be minimally invasive and highly stable to enable early rehabilitation. Various surgical methods for pelvic ring fractures have been reported, but most of them are intended for young people, and few accurately evaluated the complications and gait improvement of FFP surgery.

Crab-shaped fixation (CSF) is a type of spinopelvic fixation (SPF) involving the use of spinal instrumentation reported in detail by Okuda in 2019<sup>(11)</sup>. It is a minimally invasive surgery that is mainly performed for percutaneous fixation and for the treatment of unstable pelvic ring fractures caused by high-energy trauma. Because CSF is an SPF that can reconstruct the pelvic ring using spinal instrumentation, it can withstand the vertical shear force of FFP with a sacral fracture. This indicates that CSF might be useful for treating FFPs, which requires strong fixation. The current study aimed to evaluate the early return of mobility and perioperative complications of CSF patients with vertically unstable FFPs, including sacral fractures.

## Materials and Methods

### Patients and study design

This study was approved by the ethics committee of our

institution. All participants were informed of the purpose of the study and provided written informed consent.

This retrospective observational study included patients diagnosed with FFPs, including sacral fracture, who required hospitalization and were followed up for more than 6 months after treatment. Patients were diagnosed with FFPs if they had pelvic fractures caused by minor trauma, such as a fall, and a bone mineral density of the femur 2.5 standard deviations or more below the mean of young adults at the time of hospitalization, as determined *via* dual-energy X-ray absorptiometry (Discovery Ci, Hologic Inc., USA). The indications for surgery were hospitalization due to FFPs and persistent pain while performing physical movements after a 2-week bed rest. During bed rest, vitamin D supplements were administered when vitamin D deficiency was observed, and analgesics were provided to reduce pain. Moreover, range of motion training and strength training of the lower limbs were conducted to the extent that did not result in any pain. In addition, for comparison, among patients hospitalized due to FFP, those who were able to sit in a wheelchair within 2 weeks and who underwent conservative treatment were used as controls.

### Surgical procedure

CSF was performed with some modifications of the conventional procedure in all surgical cases<sup>(11)</sup>. A spinal implant (Verse-system, Depuy Synthes) was used for fixation. Surgery was performed in the prone position under general anesthesia. First, an arcuate skin incision of 4-6 cm was made along the inside of both the superior posterior iliac spines (PSISs), and the iliac crest proximal to the PSIS was excised at a length of about 3 cm and width of about 2 cm (Fig. 1a). Then, we inserted two screws under fluoroscopic guidance until the screw heads were below the iliac crest. Next, a rod was molded into a W shape and fixed between the left and right screws. However, we found that the S1 and S2 spinous processes interfered with the rod insertion. Thus, to excise the spinous processes, either a new skin incision of approximately 2 cm was made in the middle of the

**Table 1.** Characteristics of Patients Who Received CSF.

Case	Age (year)	Sex	Bone mineral density (Young adult mean) (%)	Rommens classification	Medical history
1	75	F	60	IVC	Stomach cancer, femoral neck fracture
2	91	F	60	IIIC	Hypertension
3	91	F	33	IVC	Hypertension, anemia
4	52	F	64	IVC	None
5	83	F	69	IVB	Hypertension, gallstone
6	85	F	60	IVB	Stomach cancer, colorectal cancer

CSF, Crab-shaped fixation

**Table 2.** Surgical Findings and Improvement of Postoperative Walking Ability.

Case	Operation time (min)	Estimated blood loss (ml)	Additional fixation	Bone union	Postoperative period until walker training (day)	Use of walking aids after operation
1	181	150	Anterior plate fixation	×	34	Walking cane
2	153	130	None	○	12	Walker
3	200	90	None	○	4	Walker → death
4	205	90	None	○	2	None
5	206	160	None	○	1	Walking cane
6	139	125	None	×	12	None

left and right screws or a bone chisel was inserted from the first incision. Once the W-shaped rod was inserted between both iliac crests, an L4 and/or L5 pedicle screw was inserted percutaneously through another skin incision. Then, another rod was passed through the pedicle screw until it met the W-shaped rod. Both rods were then connected and fixed using a connector (Fig. 1b, c).

#### Patient and surgery characteristics

We evaluated patients' age, sex, bone mineral density, history of osteoporosis treatment, and cause of injury. In addition, to analyze the characteristics of FFPs, we evaluated the imaging findings, fracture type, Rommens classification, and presence of sacral fractures. Furthermore, surgery was evaluated based on the estimated blood loss, operation time, additional fixation, perioperative complications, and degree of bone union at 6 months following surgery. The judgment of bone union was defined as the bone union of the posterior elements (sacrum, sacroiliac joint, and ilium) involved in the instability of the pelvic ring. Finally, improvements in postoperative walking ability were evaluated based on the length of the postoperative period prior to the start of weight-bearing, the length of the postoperative period prior to the start of walker training, and whether walking aids were required at 6 months following surgery. Moreover, the improvements in post-injury walking ability were compared between the surgery and conservative treatment groups. For the conservative treatment group, improvement in postoperative walking ability was evaluated based on the length of the period from admission to the start of walker training and whether walking aids were required at 6 months after the admission.

#### Statistical analysis

Patient characteristics and post-injury walking ability between the CSF and conservative treatment groups were compared using the Wilcoxon rank-sum test and independent *t*-test depending on whether the measured data followed a normal distribution. Categorical variables were expressed as frequency (%) and compared using Pearson's chi-squared test and Fisher's exact test. Statistical significance was set at  $p < 0.05$ . All statistical analyses were conducted using the JMP<sup>®</sup> 13 software (SAS Institute Inc., Cary, NC, USA). All data are expressed as mean ± standard deviation unless otherwise indicated.

## Results

#### Patients' clinical and demographic characteristics

Our study included 6 cases that received CSF and 16 cases that received conservative treatment. Table 1 presents the demographic data of patients that received CSF. The average age of the patients was  $79.5 \pm 14.7$  years, and all patients were female. The patients' mean bone mineral density of the femur was  $57\% \pm 12.6\%$  of that of young adults. Osteoporosis was observed in all patients; however, only two patients were taking anti-osteoporosis drugs before their injuries. With regard to the cause of injury, one patient fell from a low table, and five patients fell while standing. We also observed the following preoperative fracture types (Rommens classification): IIIC in one case, IVB in two cases, and IVC in three cases. Sacral fractures were present in all cases.

Table 2 presents the surgical and postoperative walking

**Table 3.** Comparison of Post-injury Walking Ability Between the CSF and Conservative Treatment Groups.

	CSF	Conservative treatment	P-value	
No. of patients	6	16		
Age, mean (range), yr	79.5±14.7 (52-91)	82.6±10.5 (61-95)	0.590	
Sex (male/female)	0/6	2/14	0.364	
Rommens classification	IIC	IIB	2	
	IVB	IIC	5	
	IVC	IIIB	1	
		IVB	1	
		IVC	7	
Period until the start of walker training (day) *1	10.8±12.3	19.5±7.8	0.033	
Use of walking aids after operation	Wheel chair	0	Wheel chair	3
	Walker	2	Walker	3
	Walking cane	2	Walking cane	7
	None	2	None	3
Bone union (union/nonunion (%))	4/2 (67%)	8/8 (50%)	0.484	

\*1 The postoperative period was described in CSF, and the period from admission was described in conservative treatment.

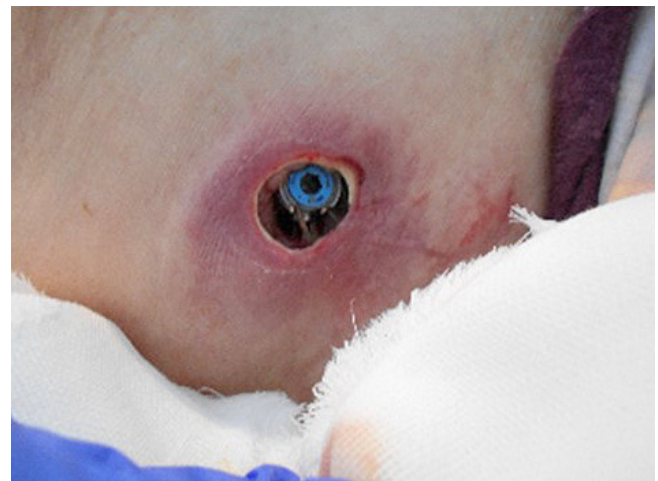CSF, Crab-shaped fixation

ability findings of patients who received CSF. The average operation time was 180.7±28.7 min (range, 147-206 min), and the average estimated blood loss was 124.2±29.4 mL (range, 90-160 mL). Only in case 1, Since dislocation of iliac fracture and vertical shear were found, anterior and posterior fixation was performed in two steps. Anterior fixation (two pelvic plates on the right wing of the ilium and pubic symphysis plate) was performed in the first stage, whereas CSF was performed in the second stage. The average length of the postoperative period prior to the start of weight-bearing was 7.8±11.5 days (range, 1-31 days), and the average length of the postoperative period prior to the start of walker training was 10.8±12.3 (range, 1-34 days). Only one patient (Case 1) had weight-bearing limitations due to dislocation in the vertical shear. Except for Case 1, the average lengths of the postoperative period prior to the start of weight-bearing and walker training were 3.2 and 6.2 days in five cases, respectively. Bone union was observed in four cases at 6 months post-surgery. At 6 months post-surgery, two patients did not require walking aids, two required a cane, and one required a walker. The last patient was healthy enough to use a walker; however, she died of pneumonia after the 6-month postoperative period (Case 3).

Table 3 presents the comparison of the post-injury walking ability between the CSF and conservative treatment groups. No significant differences in age, sex, or bone fusion were observed. However, walker training could be started early in patients who underwent CSF. No difference was observed between CSF and conservative treatment regarding the need for waking aid at 6 months, but walking was difficult in some patients who received conservative treatment.

### Complications

We observed one case of poor reduction of dislocation in



**Figure 2.** Local findings indicating skin disorders. The screw head was found on the skin (Case 3).

the vertical shear (Case 1) and one case of aggravation of the surgical site (Case 3).

Case 1 involved a patient with vertical dislocation. In this case, more than 2 months had passed since the FFP occurred, and a callus was observed. Because iliac and pubic fractures with dislocations were observed, posterior fixation was performed after anterior fixation in two stages. We fixed the FFP *in situ* without any reduction of fracture dislocation and limited the patient's weight-bearing. The walking ability of this patient improved by using a cane, but the fracture site became a pseudo-joint.

Case 3 involved a thin elderly patient. In this case, due to the thinness and fragility of the skin surrounding the PSIS, wound necrosis and infection occurred at the surgical site (Fig. 2). In the patient, surgical wound healed after surgery; however, the thin skin was continuously irritated by the iliac screw head. Two months after surgery, the patient was able

to walk using a walker and was discharged from our hospital. Then, the wound exhibited no clinical signs of infection and necrosis, although skin irritation occurred. After discharge from our hospital, she moved to another hospital to receive nursing care. Three months after surgery, she was transferred to our hospital due to wound necrosis and pneumonia. After the patient achieved bone union, all implants that fixed the fracture were removed, and the wound improved; however, she eventually died of pneumonia.

## Discussion

In the current study, we evaluated the results of CSF in patients with vertically unstable FFPs, including sacral fractures. A slight intraoperative bleeding occurred during CSF, and surgery was possible for walker training during the early postoperative period. Although some patients eventually required walking aids, their walking ability improved. Furthermore, bone union was observed in most cases.

In the current case series, patients with vertically unstable FFPs, including sacral fractures, who received CSF exhibited stabilized pelvic ring and improved walking ability. With regard to surgical treatment for FFP, Henrik reported that fixation with iliosacral screws resumed good function<sup>12</sup>. However, there was a risk of screw misplacement, and in patients with osteoporosis, there was a risk of screw loosening due to low bone stock<sup>13</sup>. Sacroiliac rod fixation and SPF have previously been found to be capable of reducing the vertical displacement of unstable pelvic ring fracture due to high-energy trauma<sup>14,15</sup>. Futamura et al. reported a method of reducing vertical dislocations using a Schanz screw and then fixing the fracture within the pelvis<sup>16</sup>. Moreover, Koshimine et al. reported that the minimally invasive Galveston method can reduce the vertical displacement of pelvic ring fractures<sup>17</sup>. With CSF, reduction was possible with small dislocations<sup>11</sup>. In this series, dislocation was poorly reduced in one case. However, as surgery for FFPs involves fragile bone fixation, the reduction of dislocation using screws may cause implant failure and further fracturing<sup>18</sup>. Therefore, FFPs should be fixed *in situ* as much as possible. In a cadaver study, the combination of SPF and the transiliac-transsacral screw was reported to have the strongest fixation to the sacral fracture<sup>19</sup>. CSF is a minimally invasive method that combines pelvic ring reconstruction and SPF as described above. From this perspective, CSF is a good, if not optimal, treatment for FFPs as it was found to improve walking ability even in cases with dislocation.

In the current study, we observed one case of aggravation of the surgical site. The posterior iliac crest is a thin subcutaneous tissue where body pressure is applied. Because the initial incision site of the CSF procedure is near the posterior iliac crest, patients with poor nutrition and very thin skin may develop skin disorders, such as pressure ulcers, if postoperative gait training is not advanced. Yano et al. reported that a midline one-incision approach was useful for CSF<sup>20</sup>. By locating the optimal site for skin incision for

CSF, the incidence of skin disorders caused by skin fragility, which is common among elderly patients, can be reduced.

Our case series study had some limitations. First, this study was a retrospective study, and CSF was performed on cases that did not exhibit improvement with conservative treatment. Moreover, the factors that did not improve with conservative therapy have not been evaluated. Therefore, an accurate two-group evaluation of surgical and conservative treatments was not possible. Thus, a randomized study on conservative and surgical treatments is needed in the future. Second, our study evaluated a small number of cases. To accurately evaluate the perioperative complication rates and postoperative physical movement, evaluation of more cases is necessary. Moreover, our follow-up period was short. Long-term follow-ups are necessary to enable comparison between CSF and other surgical and conservative treatments.

Reports on surgical results and postoperative walking ability in patients with FFP are scarce, and the current study evaluating walking ability 6 months following surgery is important. The problems of surgery for FFPs include body fragility due to aging and fixation of osteoporotic bone. In the current study, CSF for patients with FFPs allowed early ambulation and bone union, even during *in situ* pelvic ring reconstruction. Furthermore, despite the abovementioned limitations, CSF is considered a useful surgical method for the treatment of patients with FFP.

## Conclusion

We evaluated the results of the posterior pelvic ring reconstruction with CSF in patients with vertically unstable FFPs, including sacral fractures. CSF is minimally invasive and useful as bone union was observed in most cases. Moreover, it allowed walker training during the early postoperative period, which helped improve the walking ability of patients, even during *in situ* pelvic ring reconstruction.

**Disclaimer:** Sumihisa Orita is one of the Editors of Spine Surgery and Related Research and on the journal's Editorial Committee. He was not involved in the editorial evaluation or decision to accept this article for publication at all.

**Conflicts of Interest:** The authors declare that there are no relevant conflicts of interest.

**Acknowledgement:** We gratefully acknowledge the work of past and present members of our hospital.

**Author Contributions:** SY wrote the article and MI, SuO, KI, YE, YaS and SeO provided critical comments on the draft of the manuscript. MI, NT, GK, YuS, TA, AW, YA treated the patient. All authors read and approved the final version of the manuscript.

**Ethical Approval:** The approval code is No.115 of Eastern chiba medical center.

## References

1. Oinuma T, Sakuma M, Endo N. Secular change of the incidence of four fracture types associated with senile osteoporosis in Sado, Japan: the results of a 3-year survey. *J Bone Miner Metab.* 2010; 28:55-9.
2. Sullivan MP, Baldwin KD, Donegan DJ, et al. Geriatric fractures about the hip: divergent patterns in the proximal femur, acetabulum, and pelvis. *Orthopedics.* 2014;37(3):151-7.
3. Krappinger D, Kammerlander C, Hak DJ, et al. Low-energy osteoporotic pelvic fractures. *Arch Orthop Trauma Surg.* 2010;130(9): 1167-75.
4. Rommens PM, Hofmann A. Comprehensive classification of fragility fractures of the pelvic ring: recommendations for surgical treatment. *Injury.* 2013;44(12):1733-44.
5. Rommens PM. Is there a role for percutaneous pelvic and acetabular reconstruction? *Injury.* 2007;38(4):463-77.
6. Rommens PM, Wagner D, Hofmann A. Minimal invasive surgical treatment of fragility fractures of the pelvis. *Chirurgia (Bucur).* 2017;112(5):524-37.
7. Wagner D, Ossendorf C, Gruszka D, et al. Fragility fractures of the sacrum: how to identify and when to treat surgically? *Eur J Trauma Emerg Surg.* 2015;41(4):349-62.
8. Lin HS, Watts JN, Peel NM, et al. Frailty and post-operative outcomes in older surgical patients: a systematic review. *BMC Geriatr* 2016;16:157.
9. Rommens PM, Arand C, Hopf JC, et al. Progress of instability in fragility fractures of the pelvis: an observational study. *Injury.* 2019;50(11):1966-73.
10. Ueda Y, Inui T, Kurata Y, et al. Prolonged pain in patients with fragility fractures of the pelvis may be due to fracture progression. *Eur J Trauma Emerg Surg.* 2019.
11. Okuda A, Maegawa N, Matsumori H, et al. Minimally invasive spinopelvic “crab-shaped fixation” for unstable pelvic ring fractures: technical note and 16 case series. *J Orthop Surg Res.* 2019; 14(1):51.
12. Henrik E, Egger A, Hasler RM, et al. Good functional outcome in patients suffering fragility fractures of the pelvis treated with percutaneous screw stabilisation: assessment of complications and factors influencing failure. *Injury.* 2017;48(12):2717-23.
13. Kim, JW, Oh CW, Oh JK, et al. The incidence of and factors affecting iliosacral screw loosening in pelvic ring injury. *Arch Orthop Trauma Surg.* 2016;136(7):921.
14. Schildhauer TA, Ballabarba C, Nork SE, et al. Decompression and lumbopelvic fixation for sacral fracture-dislocations with spinopelvic dissociation. *J Orthop Trauma.* 2006;20(7):447-57.
15. Jones CB, Sietsema DL, Hoffmann MF. Can lumbopelvic fixation salvage unstable complex sacral fractures? *Clin Orthop Relat Res.* 2012;470(8):2132-41.
16. Futamura K, Baba T, Mogami A, et al. “Within ring”-based sacroiliac rod fixation may overcome the weakness of spinopelvic fixation for unstable pelvic ring injuries: technical notes and clinical outcomes. *Int Orthop.* 2018;42:1405-11.
17. Koshimune K, Ito Y, Sugimoto Y, et al. Minimally invasive spinopelvic fixation for unstable bilateral sacral fractures. *Clin Spine Surg.* 2016;29(3):124-7.
18. Weiser L, Huber G, Sellenschloh K, et al. Insufficient stability of pedicle screws in osteoporotic vertebrae: biomechanical correlation of bone mineral density and pedicle screw fixation strength. *Eur Spine J.* 2017;26(11):2891-7.
19. Jazini E, Klocke N, Tannous O, et al. Does lumbopelvic fixation add stability? A cadaveric biomechanical analysis of an unstable pelvic fracture model. *J Orthop Trauma.* 2017;31(1):37-46.
20. Yano S, Aoki Y, Watanabe A, et al. Less invasive lumbopelvic fixation technique using a percutaneous pedicle screw system for unstable pelvic ring fracture in a patient with severe multiple traumas. *J Neurosurg Spine.* 2017;26(2):203-7.

Spine Surgery and Related Research is an Open Access journal distributed under the Creative Commons Attribution-NonCommercial-NoDerivatives 4.0 International License. To view the details of this license, please visit (<https://creativecommons.org/licenses/by-nc-nd/4.0/>).