

## Original Article

# Feasibility of micro-computed tomography to detect and classify proximal caries lesions *in vitro*

Karla Rovaris<sup>1</sup>, Liana Matos Ferreira<sup>1</sup>, Thiago Oliveira Sousa<sup>1</sup>, Leonardo Vieira Peroni<sup>1</sup>, Deborah Queiroz Freitas<sup>1</sup>, Ann Wenzel<sup>2</sup>, Francisco Haiter-Neto<sup>1</sup>

<sup>1</sup>Department of Oral Diagnosis, Division of Oral Radiology, Piracicaba Dental School, State University of Campinas, São Paulo, Brazil, <sup>2</sup>Department of Dentistry, Section of Oral Radiology, University of Aarhus, Aarhus, Denmark

## ABSTRACT

**Background:** Micro-computed tomography (micro-CT) has been widely described as a nondestructive *in vitro* imaging method although its accuracy for caries detection is still unclear. The aim of this study was to investigate the feasibility of micro-CT to detect and classify proximal caries lesions in posterior teeth, using different protocols.

**Materials and Methods:** In this *in vitro* study, crowns of 122 human teeth were scanned with Skyscan 1174 (Bruker, Kontich, Belgium) using the full-scan mode (360°). Reconstruction of 900 basis images was performed using NRecon Software (Bruker, Kontich, Belgium) for the protocol 1 (full-scan mode 360°), and 450 basis images were used to reconstruct the protocol 2 (half-scan mode 180°). Three observers analyzed the reconstructed images concerning the presence and depth of proximal caries lesions (244 surfaces). To determine the presence/absence and depth of caries lesions, histological examination was conducted as reference standard level of significance McNemar and McNemar-Bowker tests compared the methods studied and the gold standard ( $P < 0.05$ ).

**Results:** The intra- and inter-observer agreement for both methods ranged from moderate to excellent. There was no difference between both micro-CT methods and histology for the presence of lesions ( $P > 0.05$ ). However, both methods differed with the reference standard for depth ( $P < 0.05$ ). The disagreement occurred mostly in cases of enamel lesions. The highest diagnostic values were found for 180° rotation. Micro-CT performed well in detecting caries lesions compared to histology, meanwhile the classification of their depth presented lower values. Scan mode did not influence the detection.

**Conclusion:** Both protocols of micro-CT tested presented an overall satisfactory performance in detecting proximal caries lesions; however, for the depth classification, the method was not accurate.

**Key Words:** Caries detector, dental caries, diagnosis, X-ray micro-computed tomography

Received: August 2016  
Accepted: October 2017

### Address for correspondence:

Dr. Thiago Oliveira Sousa,  
Department of Oral  
Diagnosis, Division of Oral  
Radiology, Piracicaba Dental  
School, State University  
of Campinas, Avenida  
Limeira, P.O. Box 52,  
Zip Code 13414-903  
Piracicaba, São Paulo, Brazil.  
E-mail: thiagoodonto@  
hotmail.com

## INTRODUCTION

The use of micro-computed tomography (micro-CT) in dental research has widely increased in the past few years.<sup>[1-3]</sup> This imaging modality allows the examination of dental hard tissues<sup>[4]</sup> *in vitro* without destruction of samples, and after acquisition, the images can be stored

and re-evaluated at different times.<sup>[4,5]</sup> In contrast, histological examination causes total destruction of the analyzed tooth, apart from being a method that demands time.<sup>[4,6,7]</sup> Although micro-CT cannot be used

This is an open access article distributed under the terms of the Creative Commons Attribution-NonCommercial-ShareAlike 3.0 License, which allows others to remix, tweak, and build upon the work non-commercially, as long as the author is credited and the new creations are licensed under the identical terms.

**For reprints contact:** reprints@medknow.com

**How to cite this article:** Rovaris K, Ferreira LM, Sousa TO, Peroni LV, Freitas DQ, Wenzel A, *et al.* Feasibility of micro-computed tomography to detect and classify proximal caries lesions *in vitro*. Dent Res J 2018;15:123-9.

### Access this article online



Website: [www.drj.ir](http://www.drj.ir)  
[www.drjjournal.net](http://www.drjjournal.net)  
[www.ncbi.nlm.nih.gov/pmc/journals/1480](http://www.ncbi.nlm.nih.gov/pmc/journals/1480)

clinically, it provides laboratory findings that support clinical studies, especially those related to endodontics and caries diagnosis.<sup>[8]</sup>

Micro-CT shares some principles with cone-beam CT (CBCT). However, it provides images with considerably higher resolution than CBCT, being therefore more accurate for visualizing small structures.<sup>[9]</sup> Micro-CT implies in spatial resolution with voxel size usually smaller than 10  $\mu\text{m}$ <sup>[10]</sup> while CBCT resolution ranges from 76  $\mu\text{m}$  to 400  $\mu\text{m}$ .<sup>[9,11-13]</sup>

Image acquisition with high resolution leads to long scanning times and large file sizes, which represent much time dedicated to the development of research and large memory space for storage in computers and other devices. However, micro-CT units allow the operator to vary the settings in the scanning that may directly interfere in the performance and consequently in the result of the acquisition.<sup>[14]</sup>

One of the adjustments available in both CBCT and micro-CT devices is the scan mode selection, which can be set as 180° (half scan) or 360° (full scan).<sup>[15-17]</sup> In case, this does not affect the diagnostic performance, the scan mode of 180° should be preferred due to reduced acquisition time, and lesser storage space required. The use of 180° protocol for CBCT scans has been encouraged in literature; however, for micro-CT, the impact of this modification is still unclear.

Given the importance of micro-CT as a nondestructive method and considering the possibility of validating it as a gold standard for caries diagnosis, the aim of this study was to investigate the feasibility of micro-CT to detect and classify proximal caries lesions in posterior teeth, using different protocols.

## MATERIALS AND METHODS

This *in vitro* study, study was conducted after approval in local Ethical Research Committee (protocol no. 145/2012).

### Specimens

After proper disinfection using glutaraldehyde 2% for 2 h, 140 extracted human teeth were handled. Molars and premolars were selected and the exclusion criteria were anomalous teeth and partial or total coronal destruction ( $n = 18$ ). Teeth with sound surfaces or clinically visible proximal caries lesion surfaces (i.e., demineralization) were kept hydrated in distilled water and used in this study.

Both proximal surfaces were included in the final sample ( $n = 244$ ).

### Micro-computed tomography examination

Crowns were scanned using a Skyscan 1174 device (Bruker, Kontich, Belgium) with the following settings: 50 kV, 800  $\mu\text{A}$ , 28.15 pixel size, filter 1.0 mm aluminum, rotation step 0.4°, and 4 frames. The full-scan mode 360° was performed for each tooth and resulted in 1 h 50 min scanning time.

Reconstruction of 900 basis images was performed using NRecon Software (Bruker, Kontich, Belgium) generating 352 sections for the full mode, and 450 basis images were used to reconstruct the half-scan mode 180°, resulting in 352 sections. The parameters of reconstruction were smoothing “1,” ring artifacts reduction between “5” and “10,” beam hardening correction “0,” and automatic misalignment correction.

Three experienced oral radiologists analyzed the reconstructed images using Data Viewer Software (Bruker, Kontich, Belgium). Observers were previously trained and instructed to score the presence or absence of caries lesions: (0) absence and (1) presence. Lesions were considered present when there was a density difference in the proximal surface both in sagittal and axial sections. In case of a score 1, depth was also registered: (1) lesion involving only the external half of the enamel, (2) lesion involving the internal half of the enamel, and (3) lesion involving dentine. The teeth were randomized before the evaluation.

### Histological examination

To determine the presence of a caries lesion, the teeth were individually embedded in acrylic (VIPI Cril, VIPI, São Paulo, Brazil) and serially sectioned into 1000  $\mu\text{m}$  thick sections in the mesiodistal direction, using a 300  $\mu\text{m}$  diamond band. The tooth sections were cleaned of dust and glued to microscope slides using transparent varnish. Two experienced precalibrated observers (different from those who examined the radiographic images) examined the tooth sections using a light microscope Leica DMLP (Leica Microsystems Inc., Wetzlar, Germany). The same classification system was used for registration of presence/absence and depth of the lesions.

### Statistical analysis

Software SPSS Statistics for Windows, Version 22.0 (IBM Corp., Armonk, NY, USA), was used for analysis. Intra- and inter-observer

reproducibility for presence/absence and depth was evaluated by kappa and weighted kappa tests, respectively, with the following interpretation for the values: 0–0.39 poor agreement, 0.40–0.59 moderate agreement, 0.60–0.74 good agreement, and 0.75–1.00 excellent agreement.

Contingency cross-tables including the scores recorded from all examiners with both imaging modalities (micro-CT 180° and 360°) and the gold standard (histological examination) were created. McNemar and McNemar-Bowker tests compared the methods studied and the gold standard for presence/absence and lesion depth, respectively; the significance level was set at 5%. The null hypothesis considered that there was no differences between the two imaging modalities tested and between each and the gold standard.

The diagnostic accuracy (sensitivity, specificity, and positive and negative predictive values) of the two micro-CT protocols regarding the presence of caries lesions was also calculated.

## RESULTS

Based on the histological analysis (reference standard), 127 (52.04%) proximal surfaces were sound, 26 (10.65%) had a carious lesion in the outer half of the enamel, 43 (17.62%) had a carious lesions in the inner half of the enamel, and 48 (19.67%) had a carious lesion in dentine, which is shown in Figures 1-3, respectively.

The scores obtained with the two micro-CT modalities were compared to the reference standard in Tables 1 and 2, in terms of presence and depth, respectively. There was no difference between both protocols, and the reference standard for detecting the lesions was  $P > 0.05$  [Table 1]. McNemar-Bowker test indicated that both micro-CT modalities disagreed with the reference standard regarding

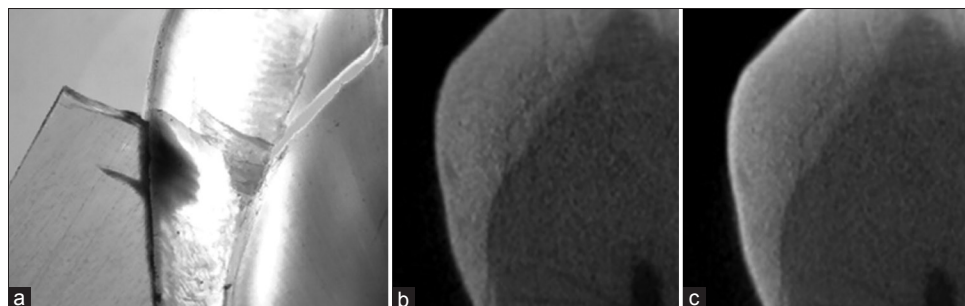
lesion depth ( $P < 0.05$ ) [Table 2]. Overall, more lesions were detected through micro-CT protocols compared to histology. However, both protocols agreed with the reference standard when there was no lesion or when the lesion was in dentin. Considering those two conditions, 180° scan mode showed a higher percentage of agreement with histology. The disagreement occurred mostly in cases of lesions restrict to enamel; when the lesion was initial (in the outer half), it was classified as absent in almost half of cases, but when the lesion was in inner half, it was observed as in dentine in the micro-CT images in almost half of cases.

Sensitivity, specificity, accuracy, and positive and negative predictive values are shown in Table 3. The highest diagnostic accuracy values were found for 180° micro-CT rotation, despite the difference between the protocols was not significant.

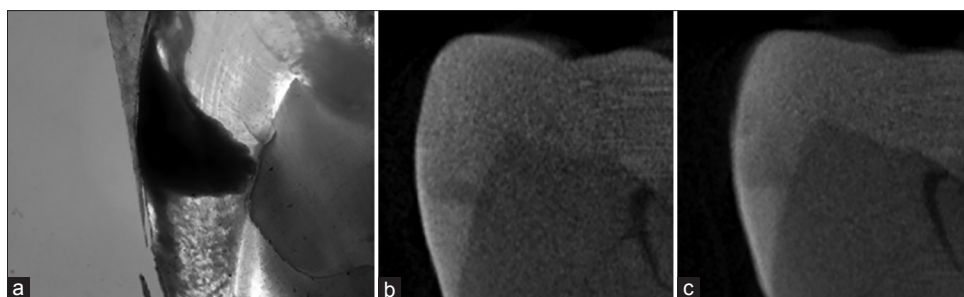
Kappa coefficients for intra-observer agreement of the presence/absence of lesion detection ranged from moderate to excellent for both protocols: 180° (0.55–0.97) and 360° (0.50–0.83). Inter-observer agreement ranged from moderate to good for both rotations (0.59–0.70 and 0.49–0.70, respectively). Regarding lesion depth, intra-observer agreement ranged from good to excellent for 180° rotation (0.60–0.98) and from moderate to excellent for 360° (0.45–0.85). Inter-observer agreement was good for 180° rotation (0.61–0.71) and from moderate to good for 360° rotation (0.46–0.68).

## DISCUSSION

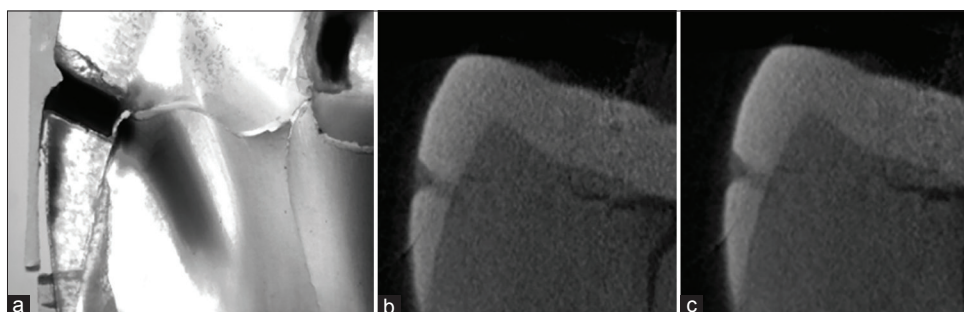
New imaging methods are often created, and before being considered a gold standard, they must be tested. To the best of the authors' knowledge, this is the largest study in terms of sample that aimed to validate micro-CT method for detection of proximal caries lesions and the first one that tested different



**Figure 1:** Outer half of enamel. (a) Histological image. (b) Half-scan mode 180°. (c) Full-scan mode 360°.



**Figure 2:** Inner half of enamel. (a) Histological image. (b) Half-scan mode 180°. (c) Full-scan mode 360°.



**Figure 3:** Dentin. (a) Histological image. (b) Half-scan mode 180°. (c) Full-scan mode 360°.

**Table 1: Contingency table confronting the responses of the three observers obtained with the methods 180° and 360° micro-computed tomography to histological reference regarding presence of caries lesions**

Observers responses	Gold standard	
	Absence (%)	Presence (%)
180°		
Absence	<b>331 (45.2)</b>	46 (6.3)
Presence	50 (6.8)	<b>305 (41.7)</b>
<i>P</i> -value	0.627	
360°		
Absence	<b>306 (41.8)</b>	64 (8.8)
Presence	75 (10.2)	<b>287 (39.2)</b>
<i>P</i> -value	0.305	
Total	381 (52.2)	351 (48.0)

Bold letters indicate agreement between methods

acquiring protocols. Aiming this purpose, the overall results from both scanning protocols did not differ from histology (reference standard) regarding the detection of caries lesions. However, when evaluating lesions with different depths separately, caries strict to the outer half of enamel showed disagreement with histology. Difference was also found between histology and micro-CT concerning the classification of lesion depth.

The present study evaluated caries lesions in proximal surfaces of posterior teeth, which are clinically challenging in terms of diagnosis. Kamburoğlu

*et al.*,<sup>[18]</sup> in 2011, found more reproducible results measuring occlusal caries lesions with micro-CT than with intraoral charge-coupled device (CCD) and CBCT systems. However, this study focused only on the repeatability of the measurements. Either way, studies comparing the detection and measurement of caries lesions in different faces of human teeth should be considered.

In a previous study,<sup>[19]</sup> the authors tested the effect of scan protocol on the detection of root fractures in endodontically treated teeth using CBCT and found differences between 180° and 360° scans only for specificity results. They explained that full-scan mode led to a significant decrease in false-positive rate. This particular finding of specificity agrees with our results; however, our overall diagnostic test results were better for 180° rotation that included accuracy, sensitivity, and predictive values.

Images must be relatively dense, with an optimum contrast to provide a base for the detection of proximal carious lesions. Detection of caries lesions may occur when the density difference between the hard tissues of the tooth and the demineralization area becomes high enough to be detected by radiographic methods, as a result of interactions between X-rays and mineral in tooth structure. In the proximal enamel lesions, the limit between pathological and healthy tissue may present low radiographic contrast hindering

**Table 2: Contingency table confronting the responses of the three observers obtained with the methods 180° and 360° micro-computed tomography to histological reference regarding localization of caries lesions**

Observers responses	Gold standard			
	Absence (%)	Outer half on enamel (%)	Inner half on enamel (%)	Dentin (%)
<b>180°</b>				
Absence	<b>331 (45.1)</b>	30 (4.1)	9 (1.2)	7 (1.0)
Outer half on enamel	22 (3.0)	<b>28 (3.8)</b>	17 (2.3)	1 (1)
Inner half on enamel	10 (1.4)	13 (1.8)	<b>36 (4.9)</b>	10 (1.4)
Dentin	19 (2.6)	7 (1.0)	70 (9.6)	<b>123 (16.8)</b>
<i>P</i> -value			<0.001	
<b>360°</b>				
Absence	<b>306 (41.8)</b>	36 (4.9)	15 (2.0)	13 (1.8)
Outer half on enamel	27 (3.7)	<b>29 (4.0)</b>	11 (1.5)	3 (4)
Inner half on enamel	23 (3.1)	11 (1.5)	<b>48 (6.6)</b>	13 (1.8)
Dentin	25 (3.4)	2 (3)	58 (7.9)	<b>112 (15.3)</b>
<i>P</i> -value			<0.001	
Total	381 (52.0)	78 (10.7)	132 (18.0)	141 (19.3)

Bold letters indicate agreement between methods.

**Table 3: Diagnostic values for the 180° and 360° in determining presence of caries lesions**

Diagnostic tests	180°	360°
Sensitivity	0.86	0.82
Specificity	0.85	0.80
Accuracy	0.85	0.81
Positive predictive value	0.84	0.79
Negative predictive value	0.86	0.83

their perception.<sup>[20]</sup> Those findings are in consonance with the present study, which found difficulty in establishing the depth of these lesions, mostly those affecting enamel tissue.<sup>[4,18,21]</sup>

Micro-CT images contain noise and artifacts not related to the real scanned object, which occurs due to low signal-to-noise ratio (SNR). This is explained by the nature of enamel/phantom and/or noise from the micro-CT system, such as enamel density and structure, scanning technique and X-rays efficiency, scattered radiation, and image generation process.<sup>[5]</sup> At the present study, high resolution was needed to detect proximal caries lesion properly. However, when high resolution increases, high ionizing radiation dose is required to keep the SNR high for adequate image quality. Although improvements at the SNR can introduce scanning artifacts such as beam hardening and ring patterns resulting from the tested sample.<sup>[22]</sup> Image-processing techniques were used to reduce noise and artifacts.

Ring artifact reduction tool was determined in a try-and-error method. This postprocessing tool is efficient for most scans with small variation in pixel

intensity during the acquisition. Nevertheless, it may result in contrast reduction and blurred final images.<sup>[23]</sup> In the present study, some ring artifacts could not be removed. We decided not to use the ring artifact correction because when evaluating images from a pilot study, we realized that this tool homogenized pixels with different densities and also tended to attenuate and blur regions of decalcification, which would be a bias to this study.

To compare our study with recent investigations on how feasible micro-CT can be to detect caries lesions, we compared the results to histological examination of tooth sections, usually considered the gold standard for caries evaluation. The results were in consonance with those found by Soviero *et al.*<sup>[24]</sup> in 2012. In their study, they concluded that micro-CT can be used as the gold standard for detection of proximal caries. Other relevant issue addressed in the same study was the lack of correlation between the depths of the lesion when comparing these modalities. The same could be observed in our findings, showing difference between micro-CT and histology for lesion depth. We also believe that the sectioning during the histological procedures may abrade carious regions or comprehend different regions than those with lesions. It is an important finding since the depth of lesions is clinically related to the decision making of treatment.<sup>[4]</sup>

In our study, 180° scan presented slightly higher diagnostic values compared with 360°. Even representing only a tendency, it can be explained by the fact that a full scan implies a greater amount

of radiation and consequently higher production of scattered radiation, which can interfere in the final image. Besides, values of inter- and intra-observer agreement were considered higher for 180° than 360°.

Since micro-CT uses *in vitro* samples, radiation dose is not an important factor, as in CBCT acquisition. In despite, micro-CT device works with a quite long scanning time, which may gradually shorten the life of the machine in constant use and require longer time devoted for the acquisitions. As the results showed no difference between the 180° and 360° protocols, the half-scan rotation should be used instead of full scan. Considering the difference between micro-CT and histology depth findings, other studies should be performed testing other parameters of scanning/reconstruction/processing, with the objective of establishing the best protocol.

Histology, despite being widely used as the gold standard in many diagnostic studies of carious lesions, also has its weaknesses and susceptibility to error. These weaknesses are inherent in the method, which analyzes three-dimensional alterations using a two-dimensional method. Therefore, some characteristics can be lost during the sample preparation, which can be particularly critical for the analysis of caries depth. Because of the limitations found in both methods, it is not possible to state that the depth differences shown in the results are due to micro-CT overestimating lesion depth or histology underestimating lesion depth. It would be necessary to provide a third and new test to compare and verify if the results would change using histology or micro-CT as the gold standard.

## CONCLUSION

Micro-CT using both protocols (180° and 360°) presented high accuracy in detecting proximal caries lesions. However, detection of outer enamel caries was not as feasible as in the other regions. Both micro-CT scan protocols failed in classifying lesion depth, especially those located exclusively in enamel. The 180° scan mode should be preferred over 360° due to its advantages, such as shorter time and storage space savings and eventually increasing the lifetime of the micro-CT machine.

## Acknowledgments

We thank CAPES Foundation (Ministry of Education of Brazil, Brasília/DF – Brazil) for granting individual PhD scholarships to the authors during this research.

The authors deny any conflicts of interest related to this study.

## Financial support and sponsorship

Nil.

## Conflicts of interest

The authors of this manuscript declare that they have no conflicts of interest, real or perceived, financial or non-financial in this article.

## REFERENCES

- Hamba H, Nikaido T, Sadr A, Nakashima S, Tagami J. Enamel lesion parameter correlations between polychromatic micro-CT and TMR. *J Dent Res* 2012;91:586-91.
- Borba M, Miranda WG Jr., Cesar PF, Griggs JA, Bona AD. Evaluation of the adaptation of zirconia-based fixed partial dentures using micro-CT technology. *Braz Oral Res* 2013;27:396-402.
- Freire LG, Gavini G, Cunha RS, Santos Md. Assessing apical transportation in curved canals: Comparison between cross-sections and micro-computed tomography. *Braz Oral Res* 2012;26:222-7.
- Mitropoulos P, Rahiotis C, Stamatakis H, Kakaboura A. Diagnostic performance of the visual caries classification system ICDAS II versus radiography and micro-computed tomography for proximal caries detection: An *in vitro* study. *J Dent* 2010;38:859-67.
- Huang TT, Jones AS, He LH, Darendeliler MA, Swain MV. Characterisation of enamel white spot lesions using X-ray micro-tomography. *J Dent* 2007;35:737-43.
- Ricketts DN, Watson TF, Liepins PJ, Kidd EA. A comparison of two histological validating techniques for occlusal caries. *J Dent* 1998;26:89-96.
- Jablonski-Momeni A, Stachniss V, Ricketts DN, Heinzl-Gutenbrunner M, Pieper K. Reproducibility and accuracy of the ICDAS-II for detection of occlusal caries *in vitro*. *Caries Res* 2008;42:79-87.
- Özkan G, Kanli A, Başeren NM, Arslan U, Tatar İ. Validation of micro-computed tomography for occlusal caries detection: An *in vitro* study. *Braz Oral Res* 2015;29:S1806-83242015000100 309.
- Van Dessel J, Huang Y, Depypere M, Rubira-Bullen I, Maes F, Jacobs R, *et al.* A comparative evaluation of cone beam CT and micro-CT on trabecular bone structures in the human mandible. *Dentomaxillofac Radiol* 2013;42:20130145.
- de Faria Vasconcelos K, Dos Santos Corpas L, da Silveira BM, Laperre K, Padovan LE, Jacobs R, *et al.* MicroCT assessment of bone microarchitecture in implant sites reconstructed with autogenous and xenogenous grafts: A pilot study. *Clin Oral Implants Res* 2017;28:308-13.
- Acar B, Kamburoğlu K, Tatar İ, Arıkan V, Çelik HH, Yüksel S, *et al.* Comparison of micro-computerized tomography and cone-beam computerized tomography in the detection of accessory canals in primary molars. *Imaging Sci Dent* 2015;45:205-11.

12. Bauer JS, Link TM, Burghardt A, Henning TD, Mueller D, Majumdar S, *et al.* Analysis of trabecular bone structure with multidetector spiral computed tomography in a simulated soft-tissue environment. *Calcif Tissue Int* 2007;80:366-73.
13. Van Dessel J, Nicolielo LF, Huang Y, Slagmolen P, Politis C, Lambrichts I, *et al.* Quantification of bone quality using different cone beam computed tomography devices: Accuracy assessment for edentulous human mandibles. *Eur J Oral Implantol* 2016;9:411-24.
14. Wang G, Liu Y, Lin TH, Cheng PC. Half-scan cone-beam x-ray microtomography formula. *Scanning* 1994;16:216-20.
15. Neves FS, Vasconcelos TV, Campos PS, Haiter-Neto F, Freitas DQ. Influence of scan mode (180°/360°) of the cone beam computed tomography for preoperative dental implant measurements. *Clin Oral Implants Res* 2014;25:e155-8.
16. Lennon S, Patel S, Foschi F, Wilson R, Davies J, Mannocci F, *et al.* Diagnostic accuracy of limited-volume cone-beam computed tomography in the detection of periapical bone loss: 360° scans versus 180° scans. *Int Endod J* 2011;44:1118-27.
17. Durack C, Patel S, Davies J, Wilson R, Mannocci F. Diagnostic accuracy of small volume cone beam computed tomography and intraoral periapical radiography for the detection of simulated external inflammatory root resorption. *Int Endod J* 2011;44:136-47.
18. Kamburoğlu K, Kurt H, Kolsuz E, Öztaş B, Tatar I, Çelik HH, *et al.* Occlusal caries depth measurements obtained by five different imaging modalities. *J Digit Imaging* 2011;24:804-13.
19. Bechara B, McMahan CA, Nasseh I, Geha H, Hayek E, Khawam G, *et al.* Number of basis images effect on detection of root fractures in endodontically treated teeth using a cone beam computed tomography machine: An *in vitro* study. *Oral Surg Oral Med Oral Pathol Oral Radiol* 2013;115:676-81.
20. Pontual AA, de Melo DP, de Almeida SM, Bóscolo FN, Haiter Neto F. Comparison of digital systems and conventional dental film for the detection of approximal enamel caries. *Dentomaxillofac Radiol* 2010;39:431-6.
21. Haiter-Neto F, Casanova MS, Frydenberg M, Wenzel A. Task-specific enhancement filters in storage phosphor images from the Vistascan system for detection of proximal caries lesions of known size. *Oral Surg Oral Med Oral Pathol Oral Radiol Endod* 2009;107:116-21.
22. Davis GR, Evershed AN, Mills D. Quantitative high contrast X-ray microtomography for dental research. *J Dent* 2013;41:475-82.
23. Skyscan NV. NRecon User Guide. Available from: <http://www.bruker-microct.com/next/NReconUserGuide.pdf>. [Last accessed on 2016 Jul 14].
24. Soviero VM, Leal SC, Silva RC, Azevedo RB. Validity of microCT for *in vitro* detection of proximal carious lesions in primary molars. *J Dent* 2012;40:35-40.