

## CLINICAL CASE CHALLENGES

# ATTR Cardiomyopathy Meets Multiple Myeloma



## The Importance of Cardiac Biopsy

Anthony J. Kanelidis, MD,<sup>a</sup> Patrick Miller, MD,<sup>a</sup> Nicole Prabhu, MD,<sup>a</sup> Mark Joshua Dela Cruz, MD,<sup>a</sup> Francis J. Alenghat, MD/PhD,<sup>a</sup> Phillip McMullen II, MD/PhD,<sup>b</sup> Nitasha Sarswat, MD,<sup>a</sup> Benjamin A. Derman, MD,<sup>c</sup> Tamar S. Polonsky, MD, MSCI,<sup>a</sup> Jeanne M. DeCara, MD<sup>a</sup>

### CASE REPORT

A 74-year-old man with a past medical history of IgG Kappa multiple myeloma (MM) and persistent atrial fibrillation presented for consideration of autologous stem cell transplantation (ASCT). He was diagnosed with MM after he was found to have anemia, renal failure, and hypercalcemia. His laboratory studies revealed an IgG Kappa monoclonal protein on serum protein electrophoresis and immunofixation with kappa/lambda ratio 96. Bone marrow biopsy revealed 40% monotypic plasmacytosis. He began chemotherapy (bortezomib, lenalidomide, dexamethasone, and later carfilzomib) for his MM and achieved a very good partial response by the end of induction therapy: K/L ratio 5.6 and repeat bone marrow biopsy with 5%-8% residual plasmacytosis.

Before proceeding with ASCT, he developed signs and symptoms of heart failure (HF), including lower extremity edema, jugular vein distension, and dyspnea on exertion with New York Heart Association functional class II. He was seen in clinic by a cardio-oncologist who noted that the electrocardiogram demonstrated atrial fibrillation and low voltage. In addition, the transthoracic echocardiogram demonstrated normal left ventricular systolic function, concentric left ventricular hypertrophy with an increased wall thickness of 16 mm, and severe biatrial enlargement. The global longitudinal strain was -8.1% with an apical sparing pattern. These findings were suspicious for cardiac amyloidosis and prompted further diagnostic testing. Both high sensitivity troponin T (122 ng/L) and N-terminal pro-B-type natriuretic peptide (5,821 pg/mL) were elevated. A cardiac magnetic resonance imaging was then performed that showed normal biventricular ejection fraction but severe biatrial enlargement, and extensive diffuse subendocardial and transmural circumferential late gadolinium enhancement. The native T1 relaxation time was elevated at 1,100 ms, T2 weighted value was 225 ms, and there was no evidence of pericardial effusion. These findings were highly suggestive of an infiltrative process, with amyloidosis highest on the differential.

Given the patient's initially elevated kappa free light chain level, there was concern that the patient may have had concurrent MM and amyloid light chain (AL) amyloidosis with cardiac involvement (AL-CA). AL-CA is known to lead to poor outcomes, and knowledge of the presence of AL amyloidosis might change post-ASCT and subsequent therapies. Additional diagnostic tests were obtained to ascertain whether there was AL amyloidosis; however, both fat pad and bone marrow biopsies were negative for amyloid by Congo Red staining. Given the high index of suspicion for cardiac amyloidosis (CA), he underwent a right heart catheterization with biopsy; this demonstrated elevated biventricular filling pressures with preserved cardiac output. An endomyocardial biopsy was performed for definitive diagnosis of CA. Ultimately, CA was confirmed because the biopsy demonstrated amyloid deposits on Congo Red stain and fluorescence microscopy (**Figure 1**),

From the <sup>a</sup>Section of Cardiology, Department of Medicine, University of Chicago Medical Center, Chicago, Illinois, USA;

<sup>b</sup>Department of Pathology, University of Chicago Medical Center, Chicago, Illinois, USA; and the <sup>c</sup>Section of Hematology/Oncology, Department of Medicine, University of Chicago Medical Center, Chicago, Illinois, USA.

The authors attest they are in compliance with human studies committees and animal welfare regulations of the authors' institutions and Food and Drug Administration guidelines, including patient consent where appropriate. For more information, visit the [Author Center](#).

as well as apple-green birefringence by polarized light microscopy. The cardiac biopsy was also sent for proteomic analysis by liquid chromatography tandem mass spectrometry.

Before ASCT, the patient was holistically evaluated in a geriatric assessment-guided multidisciplinary clinic, whose outcomes have been previously reported (1). Despite his cardiac comorbidities, he had good performance status, used a recumbent bicycle daily, with independence of his activities and instrumental activities of daily living. Though there are no set criteria for determining eligibility for ASCT among patients with amyloidosis, the patient did fall within the guidelines of Mayo Clinic's mSMART eligibility criteria (2). Thus, while his biopsy results were pending, the patient proceeded with high-dose melphalan and autologous stem cell rescue for his MM, with the goal of deepening his response. His hospitalization for ASCT was complicated by neutropenic fever, acute decompensated HF, and prolonged orthostatic hypotension. His hypotension was multifactorial, including intravascular depletion from hypoalbuminemia, volume loss after significant amounts of diarrhea, and dysautonomia attributed to amyloidosis. He also experienced multiple episodes of worsening hypotension from atrial fibrillation with rapid ventricular response that was recalcitrant to multiple therapies. The results from mass spectrometry were returned during his hospitalization, which surprisingly revealed transthyretin amyloid cardiomyopathy (ATTR-CM) rather than AL-CA. No amino acid anomaly was detected on mass spectrometry, and confirmatory TTR gene sequencing did not reveal variant ATTR, thus confirming wild-type ATTR-CM.

The patient had a robust hematopoietic recovery and was discharged home on midodrine, furosemide, metoprolol, and apixaban. Given the patient's persistent orthostatic hypotension from vasoplegia and dysautonomia, and difficult-to-control atrial fibrillation, the decision was made to maintain beta-blockade for rate control while on midodrine. He was then seen in our amyloid clinic following hospital discharge and started on tafamidis to treat wild-type ATTR-CM. His bone marrow biopsy 60 days after ASCT confirmed a complete response, with no residual disease. He resumed lenalidomide as maintenance therapy as per the standard of care for post-ASCT therapy in MM. His functional status continues to improve, and he is now able to bike 3 to 4 miles daily.

## DISCUSSION

CA is characterized by deposition of insoluble protein fibrils in the heart, most commonly from immunoglobulin light chains (AL) or transthyretin (ATTR). AL amyloidosis is a product of insoluble proteins (ie, light

### ABBREVIATIONS AND ACRONYMS

**AL** = amyloid light chain

**AL-CA** = light chain cardiac amyloidosis

**ASCT** = autologous stem cell transplant

**ATTR** = transthyretin amyloidosis

**ATTR-CM** = transthyretin amyloid cardiomyopathy

**CA** = cardiac amyloidosis

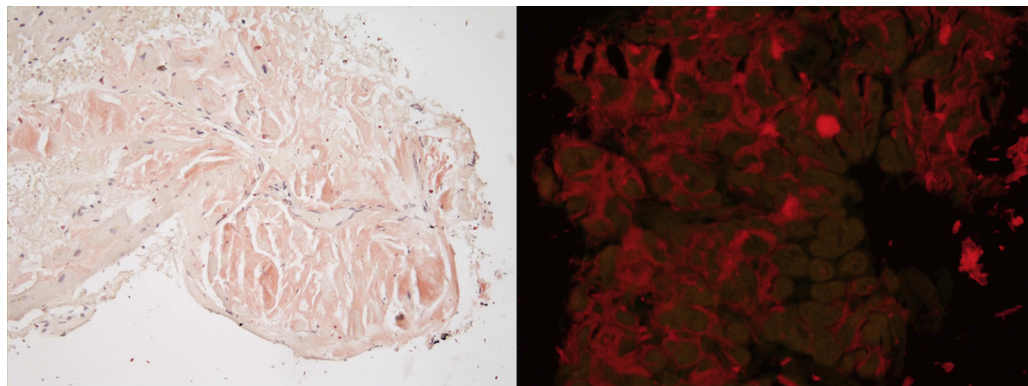
**HF** = heart failure

**MM** = multiple myeloma

**PYP scan** = <sup>99m</sup>technetium-pyrophosphate bone scintigraphy scan

**TTR** = transthyretin

**FIGURE 1** Endomyocardial Biopsy



Endomyocardial biopsy demonstrating amyloid deposits as detected by Congo Red staining (left) and fluorescence microscopy (right).

chains) produced by malignant clonal plasma cells in the bone marrow (3). In hereditary ATTR amyloidosis, a mutation occurs in the gene coding for transthyretin. ATTR-CM can also be acquired, due to age-related changes in TTR stability, known as wild-type ATTR-CM (4). Although clinical presentation and imaging studies in CA may be similar, prognosis and therapies are markedly different. AL-CA, if left untreated, has a median survival of <6 months, whereas on average, patients with clinical manifestations of ATTR-CM have an approximate survival of 3 to 5 years from diagnosis (4).

HF in patients with plasma cell dyscrasias should prompt consideration of CA. Although AL-CA is felt to be most likely when HF signs and symptoms present themselves in a patient with AL amyloidosis or other plasma cell dyscrasias, it is important to note that ATTR-CM is more prevalent than AL-CA in the general population. Autopsy data from Finland demonstrated that 25% of adults aged  $\geq 85$  years had TTR amyloid deposits in their myocardium (5). Incomplete work-up of amyloid subtyping can lead to misdiagnosis because there may be as many as 10% of older adults with a monoclonal gammopathy and ATTR-CM who are misdiagnosed as having AL-CA (3,6).

Given the high and often underappreciated prevalence of both AL amyloid and ATTR-CM, a broad screening approach is recommended within certain clinical scenarios. As outlined in a review by Witteles *et al* (4), red flags that may raise suspicion for CA are: 1) reduction in longitudinal strain with apical sparing; 2) discrepancy between left ventricular wall thickness and QRS voltage, with a lack of left ventricular hypertrophy on electrocardiogram; 3) atrioventricular block in the presence of increased left ventricular wall thickness; 4) echocardiographic hypertrophic phenotype with infiltrative features, including increased thickness of the atrioventricular valves, interatrial septum, and right ventricular free wall; 5) marked extracellular volume expansion, abnormal nulling time for the myocardium, or diffuse late gadolinium enhancement on cardiac magnetic resonance imaging; 6) symptoms of polyneuropathy and/or dysautonomia such as orthostatic hypotension (more common in AL amyloid and certain gene variants of ATTR, than in wild-type ATTR-CM); 7) history of bilateral carpal tunnel syndrome, often predating the diagnosis by up to a decade; and 8) mild increase in troponin levels on repeated occasions. Additionally, the presence of low-flow, low-gradient severe aortic stenosis should also prompt a consideration for ATTR-CM (7).

When a patient has multiple red flags for CA, this should prompt noninvasive testing to screen for AL amyloidosis with serum free light chain ratio and serum/urine protein electrophoresis and immunofixation. If this screen is negative, a  $^{99m}$ technetium-pyrophosphate bone scintigraphy scan (PYP scan) can be used as a noninvasive tool to diagnose ATTR-CM (2). If any of these initial screening tests are abnormal, however, PYP scan is contraindicated and should not be used to make the diagnosis of ATTR-CM; cardiac biopsy is recommended instead. Of note, in patients with kidney disease, mild elevations in the kappa/lambda ratio are common, and a kappa/lambda ratio up to 2.5 can typically be considered normal in the setting of a normal serum/urine protein electrophoresis and immunofixation (4). One study analyzed 857 patients with histologically proven amyloid and demonstrated that bone scintigraphy scans had a >99% sensitivity and 86% specificity for ATTR-CM, with false positives almost exclusively from uptake in patients with AL-CA (8).

Our patient was older than 65 years and had 5 red flag signs for CA, but the PYP scan was deferred because it was contraindicated in the setting of known MM and abnormal serum free light chains. Given this, we elected to proceed with endomyocardial biopsy to arrive at a definitive diagnosis. Cardiac biopsy plays an essential role in the diagnostic evaluation of suspected CA because accurate subtyping has significant implications in management and prognosis (3). Our patient was treated with chemotherapy and ASCT for MM and possible AL-CA, given the poor overall survival if AL-CA is left untreated. Without confirmatory testing with cardiac biopsy, this therapy would have been insufficient to treat his CA, because mass spectrometry revealed the subtype as ATTR-CM. After the patient's diagnosis of ATTR-CM, he was started on tafamidis, which has shown to reduce all-cause mortality and cardiovascular-related hospitalization in ATTR-CM; it also significantly attenuates the decline in functional capacity (measured by 6-minute walk test) and quality of life (as measured by Kansas City Cardiomyopathy Questionnaire Overall Summary score) (9).

This case has 3 key learning points. First, endomyocardial biopsy is essential in diagnosing CA with concomitant MM. Often times, biopsy is deferred for less invasive testing, but in the setting of either abnormal serum free light chains or in the presence of an M-spike on serum/urine protein electrophoresis with immunofixation, PYP scan is contraindicated due to the reduced specificity and possibility of false positives. The utility of cardiac biopsy also outweighs fat pad biopsy, which has limited sensitivity and does not help differentiate the type of CA, because ATTR-CM can still be present in the setting of a monoclonal

gammopathy. Second, the implications of accurate subtyping of AL-CA versus ATTR-CM in management and prognosis are profound. Avoiding anchoring bias led to a cardiac biopsy and secured an accurate diagnosis of ATTR-CM as the etiology of his HF. This led to disease-specific treatment with tafamidis, which we expect to slow the progression of his ATTR-CM. Third, genetic sequencing to characterize wild-type versus variant ATTR is also of significance because it informs the proband's family members regarding the possible need for genetic testing. This case highlights the importance of cardiac biopsy to accurately diagnose CA in a patient with MM and HF symptoms.

## FUNDING SUPPORT AND AUTHOR DISCLOSURES

---

Dr Sarswat has been a consultant and has served on advisory boards for Alnylam, Akcea, and Pfizer; and has received grant funding from Pfizer. Dr Derman has served on an advisory board for Sanofi. All other authors have reported that they have no relationships relevant to the contents of this paper to disclose.

---

**ADDRESS FOR CORRESPONDENCE:** Dr Jeanne M. DeCara, Section of Cardiology, Department of Medicine, University of Chicago Medical Center, 5758 South Maryland Avenue MC 9067, Chicago, Illinois 60637, USA. E-mail: [jdecara@medicine.bsd.uchicago.edu](mailto:jdecara@medicine.bsd.uchicago.edu). Twitter: [@KanelidisMD](https://twitter.com/KanelidisMD).

---

## REFERENCES

1. Derman BA, Kordas K, Molloy E, et al. Recommendations and outcomes from a geriatric assessment guided multidisciplinary clinic prior to autologous stem cell transplant in older patients. *J Geriatr Oncol*. 2021;12:585-591.
2. Dispenzieri A, Buadi F, Kumar SK, et al. Treatment of immunoglobulin light chain amyloidosis: Mayo Stratification of Myeloma and Risk-Adapted Therapy (mSMART) consensus statement. *Mayo Clin Proc*. 2015;90:1054-1081.
3. Roof L, Coker WJ, Lazarchick J, Kang Y. Senile transthyretin cardiac amyloidosis in patients with plasma cell dyscrasias: importance of cardiac biopsy for making the correct diagnosis. *Aperito J Cell Mol Biol*. 2014;1(1):102.
4. Witteles RM, Bokhari S, Damy T, et al. Screening for transthyretin amyloid cardiomyopathy in everyday practice. *J Am Coll Cardiol HF*. 2019;7:709-716.
5. Tanskanen M, Peuralinna T, Polvikoski T, et al. Senile systemic amyloidosis affects 25% of the very aged and associates with genetic variation in alpha2-macroglobulin and tau: a population-based autopsy study. *Ann Med*. 2008;40:232-239.
6. Lachmann HJ, Booth DR, Booth SE, et al. Misdiagnosis of hereditary amyloidosis as AL (primary) amyloidosis. *N Engl J Med*. 2002;346:1786-1791.
7. Ternacle J, Krapf L, Mohty D, et al. Aortic stenosis and cardiac amyloidosis: JACC review topic of the week. *J Am Coll Cardiol*. 2019;74:2638-2651.
8. Gillmore JD, Maurer MS, Falk RH, et al. Non-biopsy diagnosis of cardiac transthyretin amyloidosis. *Circulation*. 2016;133:2404-2412.
9. Maurer MS, Schwartz JH, Gundapaneni B, et al. Tafamidis treatment for patients with transthyretin amyloid cardiomyopathy. *N Engl J Med*. 2018;379:1007-1016.

---

**KEY WORDS** amyloidosis, cardiomyopathy, genetics, heart failure, multiple myeloma