

CASE REPORT

Behçet's pulmonary artery aneurysms treated with infliximab and monitored with the 6-min walk test

Jalpa Kotecha^{1,*}, Ajay V. Kamath¹, and Chetan Mukhtyar²¹Department of Respiratory Medicine, Norfolk and Norwich University Hospital, Norfolk, UK and ²Department of Rheumatology, Norfolk and Norwich University Hospital, Norfolk, UK

*Correspondence address. Department of Respiratory Medicine, Norfolk and Norwich University Hospital, Colney Lane, Norwich, Norfolk NR4 7UY, UK. Tel: +0044-7753-312879; Fax: +0044-1603-289640; E-mail: jalpa.kotecha@cantab.net

Abstract

Pulmonary involvement in Behçet's disease (BD) is uncommon; however, it is potentially fatal due to the risk of massive haemoptysis. We describe the case of a 36-year-old male presenting with a 2-month history of worsening dyspnoea, weight loss, haemoptysis, oral ulceration, erythema nodosum and superficial thrombophlebitis. He was diagnosed with pulmonary vasculitis secondary to BD; however, his symptoms were refractory to initial treatment with cyclophosphamide, azathioprine and prednisolone. We therefore trialled infliximab alongside methotrexate, which led to a remarkable improvement in his condition, enabling eventual discontinuation of prednisolone. Whilst not being one of the treatments currently recommended for managing pulmonary involvement in BD, infliximab has previously been successfully used in cases refractory to conventional therapy. We used the 6-min walk test (distance covered and lowest oxygen saturations) to monitor his progress, which correlated with his symptoms. This may represent a useful adjunct in monitoring the activity of pulmonary vasculitis.

INTRODUCTION

Pulmonary involvement in Behçet's disease (BD) has a prevalence of 1–7.7% [1]. Aneurysms are the commonest form of pulmonary involvement; other features include arterial and venous thrombosis and pulmonary infarction [1, 2]. Mortality rates of up to 30% are reported due to the risk of massive haemoptysis [1].

Pulmonary disease does not feature in either the International Study Group Criteria [3] or the International Criteria for Behçet's Disease (ICBD) [4] for diagnosing BD; the ICBD group only found a 2.4% prevalence of pleuro-pulmonary manifestations when studying 1278 subjects [4]. Nevertheless, given the high rate of mortality associated with it, it is important to be vigilant for signs of pulmonary vasculitis in BD and to initiate appropriate treatment.

We present a case of Behçet's pulmonary vasculitis refractory to conventional immunosuppressants that was subsequently

treated with infliximab. Disease activity was monitored with the 6-min walk test.

CASE REPORT

A 36-year-old male presented with a 2-month history of worsening dyspnoea, weight loss, haemoptysis, oral ulceration, erythema nodosum and superficial thrombophlebitis. He had a history of anterior uveitis and mild bronchiectasis (recent diagnosis on a high-resolution computerized tomography scan of the chest). Investigations revealed a raised erythrocyte sedimentation rate and C-reactive protein. Anti-neutrophil cytoplasmic antibodies were negative. A computed tomography pulmonary angiogram (CTPA) showed bilateral pulmonary arterial thrombi and aneurysmal dilatation of several pulmonary arteries, with marked hilar perivascular cuffing. The appearances were suggestive

Received: December 24, 2015. Revised: February 17, 2016. Accepted: March 21, 2016

© The Author 2016. Published by Oxford University Press.

This is an Open Access article distributed under the terms of the Creative Commons Attribution Non-Commercial License (<http://creativecommons.org/licenses/by-nc/4.0/>), which permits non-commercial re-use, distribution, and reproduction in any medium, provided the original work is properly cited. For commercial re-use, please contact journals.permissions@oup.com

of pulmonary vasculitis, which was confirmed on a computed tomography positron emission tomography scan. A diagnosis of BD was made.

He was commenced on pulsed intravenous (IV) cyclophosphamide 1.2 g/pulse and glucocorticoid treatment (initial loading of 1 g IV methylprednisolone, followed by 1 mg/kg/day oral prednisolone). At 3 months, he had received 6 pulses of IV cyclophosphamide and was switched to oral azathioprine 2 mg/kg/day. The prednisolone was weaned to 15 mg. He also received warfarin (for 6 months in total) for the pulmonary thrombi to maintain International Normalized Ratio around 2.5. At 3 months, he was asymptomatic with normal inflammatory markers. His 6-min walk test distance had improved from 405 to 510 m (Fig. 1).

Two months later, his respiratory symptoms worsened; he desaturated on the 6-min walk test for the first time since cyclophosphamide initiation. His prednisolone was increased

incrementally from 15 mg daily to 40 mg daily, and he was commenced on infliximab (5 mg/kg) every 8 weeks (after initial loading) alongside methotrexate (increased gradually to 20 mg/week). This allowed a reduction of prednisolone dose whilst maintaining symptomatic control. Prednisolone was stopped 29 months after starting infliximab. He felt that he was approaching his previous level of fitness; his 6-min walk test distance (measured at 6-monthly intervals) mirrored his symptomatic improvement, increasing to 680 m 26 months after initiating infliximab.

A follow-up CTPA (after completing cyclophosphamide therapy) showed resolution of some of the pulmonary artery aneurysms and reduced size of the others, with increased volume of thrombus of one basal segment pulmonary artery. A further CTPA (5 months after initiating infliximab) showed resolution of all previous aneurysms, with ongoing pulmonary arterial occlusion (Fig. 2).

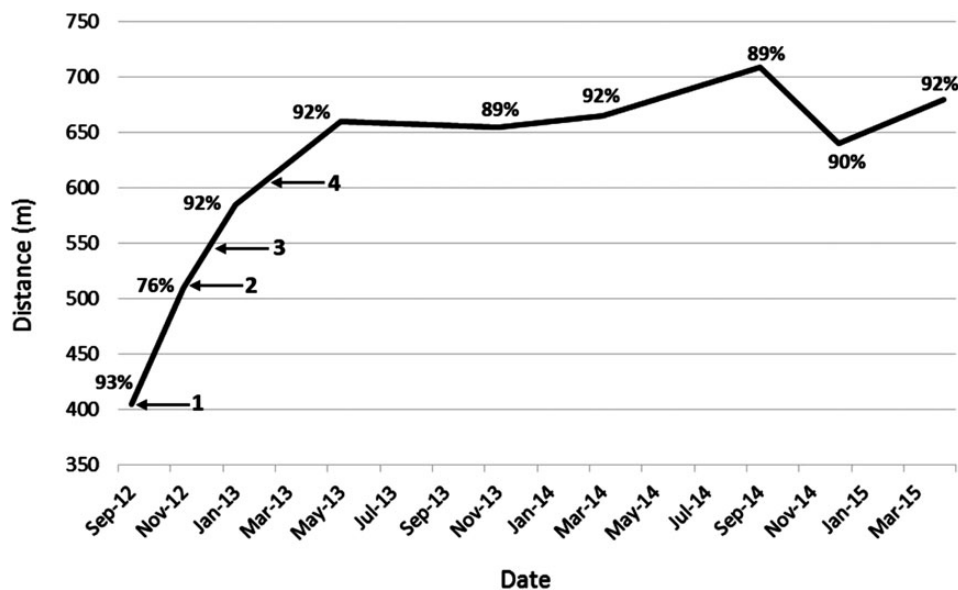


Figure 1: Six-minute walk test distance over time with the lowest oxygen saturations reached on each test. Warfarin was started in May 2012 and cyclophosphamide in June 2012. Specific time points: (1) September 2012, cyclophosphamide stopped, azathioprine started. Some worsening of symptoms, prednisolone dose increased. (2) November 2012, worsening of symptoms and desaturation to 76% on 6-min walk test. Prednisolone dose increased further. (3) December 2012, warfarin stopped. (4) February 2013, infliximab started as patient still short of breath on exertion.

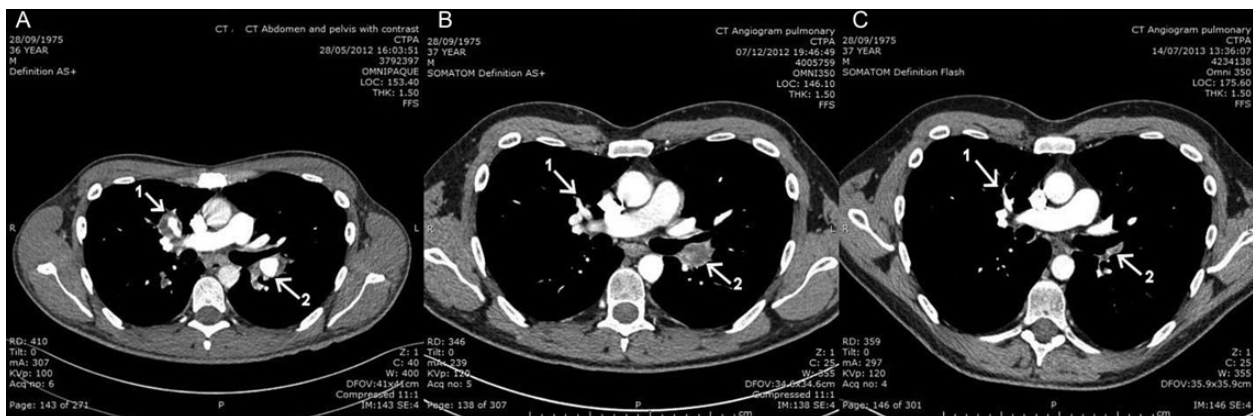


Figure 2: Progression in CTPA appearances: (A) May 2012, pre-treatment; (B) December 2012, 3 months after completion of cyclophosphamide; and (C) July 2013, 5 months after initiating infliximab. Arrow 1: Complete resolution of aneurysm from May to December 2012. No recurrence by July 2013. Arrow 2: Reduction in size of aneurysm from May to December 2012 (maximum arterial diameter 3.2 cm in May and 2.3 cm in December) with increase in volume of thrombus. Reduced volume of thrombus by July 2013.

DISCUSSION

Pulmonary involvement in BD can take the form of parenchymal disease (with findings including nodular and cavitating lesions, ground-glass opacities, pleural effusions and thickening, and lymphadenopathy) as well as pulmonary vascular involvement [2]. Pulmonary artery aneurysms (with or without thromboses) occur most frequently in young males, presenting most commonly with haemoptysis around 4 years after disease onset [1, 2]. The lower lobes of the lungs are most commonly involved, and there is a strong association with venous involvement elsewhere in the body [1, 2]. It carries a poor prognosis due to the risk of massive (>500 ml) haemoptysis, which is seen in a third of patients and is commoner in those with pulmonary artery aneurysms than those with isolated thrombi [2]. Larger-sized aneurysms (≥ 3 cm diameter) and higher pulmonary arterial pressures are associated with a poorer prognosis [2].

European League Against Rheumatism (EULAR) guidelines for managing BD [5] include using glucocorticoid and cyclophosphamide for pulmonary and peripheral arterial aneurysms. Anticoagulants, antiplatelets and antifibrinolytic agents are not recommended for managing venous thrombi, as clots adhere to vessel walls and do not generally embolize. These agents also increase the risk of fatal bleeding of any coexisting aneurysms. However, this remains a controversial issue, and anticoagulants may still be used in non-endemic regions in cases where the diagnosis is initially unclear [6].

In previous published case reports, improvement of pulmonary disease in BD has been achieved using cyclophosphamide, azathioprine, cyclosporine, mycophenolate, colchicine and glucocorticoid [1, 2]. Infliximab has been successful in two cases refractory to cyclophosphamide and two refractory to azathioprine [2, 7, 8]. Aneurysmal regression may be seen as early as 15 days after treatment initiation; resolution is seen in 68% of cases [2]. The recurrence rate for pulmonary artery involvement is around 20–25% [1, 2]. Surgical management is reserved for more severe cases.

In our case, the patient's symptoms recurred despite treatment with the recommended immunosuppressants. Infliximab was therefore trialled with good effect. Anti-tumour necrosis factor alpha (TNF α) agents are in the EULAR recommendations for managing aspects of BD such as refractory eye, skin, mucosal or neurological disease; however, they are not suggested for major vessel disease [5]. The success of infliximab in managing our patient's respiratory symptoms in the context of similar case reports suggests its utility in treating pulmonary vasculitis in BD that is refractory to conventional therapy.

In a large number of patients with BD, inflammatory markers may be normal. Recurrent CT scanning is radiation-intensive, and lung function tests are not generally affected by pulmonary thrombi or aneurysms; therefore, we used the 6-min walk test as a feasible outcome measure. The results correspond well with the symptoms. Although there are outcome measures like the Birmingham Vasculitis Activity Score (version 3) (BVAS(v3)) [9] and Behçet's Disease Current Activity Form [10] in use, they fail to address specific concerns like progression of pulmonary artery vasculitis. We found that the 6-min walk test was a useful adjunct to clinical examination; it was both easy to perform and responsive to changing phases of disease activity.

CONFLICT OF INTEREST STATEMENT

None declared.

FUNDING

No external funding was received.

ETHICAL APPROVAL

Formal ethical approval not required. The procedures followed were in accordance with the ethical standards of the Helsinki Declaration (1964, amended most recently in 2013) of the World Medical Association.

CONSENT

The patient gave informed consent for anonymized information regarding his case to be submitted for publication.

GUARANTOR

J.K. is the guarantor of this article.

REFERENCES

- Erkan F. Rare diseases bullet 12: Pulmonary manifestations of Behçet's disease. *Thorax* 2001;56:572–8. <http://thorax.bmj.com/content/56/7/572.full> (11 November 2015, date last accessed).
- Seyahi E, Melikoglu M, Akman C, Hamuryudan V, Ozer H, Hatemi G, et al. Pulmonary artery involvement and associated lung disease in Behçet disease: a series of 47 patients. *Medicine (Baltimore)* 2012;91:35–48. <http://www.ncbi.nlm.nih.gov/pubmed/22210555>.
- O'Neill TW, Rigby AS, Silman AJ, Barnes C. Validation of the International Study Group criteria for Behçet's disease. *Br J Rheumatol* 1994;33:115–7. <http://www.ncbi.nlm.nih.gov/pubmed/8162473> (19 November 2015, date last accessed).
- Davatchi F, Assaad-Khalil S, Calamia KT, Crook JE, Sadeghi-Abdollahi B, Schirmer M, et al. The International Criteria for Behçet's Disease (ICBD): a collaborative study of 27 countries on the sensitivity and specificity of the new criteria. *J Eur Acad Dermatology Venereol* 2014;28:338–47. <http://doi.wiley.com/10.1111/jdv.12107>.
- Hatemi G, Silman A, Bang D, Bodaghi B, Chamberlain AM, Gul A, et al. EULAR recommendations for the management of Behçet disease. *Ann Rheum Dis* 2008;67:1656–62. <http://ard.bmj.com/cgi/doi/10.1136/ard.2007.080432>.
- Mehta P, Laffan M, Haskard DO. Thrombosis and Behçet's syndrome in non-endemic regions. Is there a way around? *Rheumatology* 2010;49:2003–4.
- Tolosa-Vilella C, Capela CAP, Monteagudo-Jiménez M, Marí-Alfonso B. Infliximab for life-threatening pulmonary artery aneurysms in Behçet's disease. A case report. *Clin Exp Rheumatol* 2011;29 (4 Suppl. 67):S94–5. <http://www.ncbi.nlm.nih.gov/pubmed/21385550> (10 November 2015, date last accessed).
- Schreiber BE, Noor N, Juli CF, Haskard DO. Resolution of Behçet's syndrome associated pulmonary arterial aneurysms with infliximab. *Semin Arthritis Rheum* 2011;41:482–7. <http://www.ncbi.nlm.nih.gov/pubmed/21546064>.
- Mukhtyar C, Lee R, Brown D, Carruthers D, Dasgupta B, Dubey S, et al. Modification and validation of the Birmingham Vasculitis Activity Score (version 3). *Ann Rheum Dis* 2009; 68:1827–32. <http://www.ncbi.nlm.nih.gov/pubmed/19054820>.
- Bhakta BB, Brennan P, James TE, Chamberlain Ma, Noble Ba, Silman aj. Behçet's disease: evaluation of a new instrument to measure clinical activity. *Rheumatology (Oxford)* 1999; 38:728–33.