



Diagnostic Value of T1 Mapping in Detecting Iron Overload in Indian Patients with Thalassemia Major: A Comparison with T2* Mapping

Surya Pratap Singh¹ Priya Jagia¹ Vineeta Ojha¹ Tulika Seth² Nitish Naik³ Kartik P. Ganga¹ Sanjeev Kumar¹

¹ Department of Cardiovascular Radiology and Endovascular Interventions, All India Institute of Medical Sciences, New Delhi, India

² Department of Haematology, All India Institute of Medical Sciences, New Delhi, India

³ Department of Cardiology, All India Institute of Medical Sciences, New Delhi, India

Address for correspondence Priya Jagia, MD, Room 10A, Department of Cardiovascular Radiology and Endovascular Interventions, Cardiothoracic and Neurosciences Centre, All India Institute of Medical Sciences, New Delhi 110029, India (e-mail: drpjagia@yahoo.com).

Indian J Radiol Imaging 2024;34:54–59.

Abstract

Purpose T2* is the gold standard for iron quantification in liver as well as myocardium. In this study, we evaluated the diagnostic accuracy of myocardial T1 mapping for the assessment of myocardial iron overload (MIO) as compared to the T2* mapping in patients with thalassemia major (TM).

Methods Consecutive TM patients attending the thalassemia clinic were prospectively enrolled. Magnetic resonance imaging was performed on a 1.5 T scanner (Siemens Healthineers, Germany) using a gradient echo T2* as well as a T1 mapping (MOLLI) sequence done at a mid-ventricular short-axis single 8 mm slice of the left ventricle. Values were analyzed by manually drawing a region of interest in the mid-septum. T2* less than 20ms was used as the cutoff for significant MIO.

Results One-hundred three patients (58 males, mean age: 17 ± 7.8 years, mean ferritin: 2009.5 µg/L) underwent cardiovascular magnetic resonance. Median T2* of myocardium was 33.45ms. Nineteen patients (18.4%) had T2* less than 20ms. T1 value was low (<850ms) in all the patients with T2* less than 20ms. Receiver operating characteristic curve analysis revealed the best cutoff of native T1 mapping value as 850 ms which had high specificity (95.2%), sensitivity (94.2%) and negative predictive value (98.8%) for T2* less than 20ms. There was excellent agreement between T1 and T2* for diagnosis of MIO (Kappa=0.848, $p < 0.001$). We did not find any patient who had normal T1 mapping values but had MIO on T2*.

Conclusion T1 and T2* correlate well and normal T1 values may rule out presence of MIO. T1 mapping can act as additional imaging marker for MIO and may be helpful in centers with nonavailability or limited experience of T2*.

Keywords

- ▶ T1 mapping
- ▶ thalassemia
- ▶ T2* mapping
- ▶ iron overload

article published online
September 4, 2023

DOI <https://doi.org/10.1055/s-0043-1772467>.
ISSN 0971-3026.

© 2023. Indian Radiological Association. All rights reserved.
This is an open access article published by Thieme under the terms of the Creative Commons Attribution-NonDerivative-NonCommercial-License, permitting copying and reproduction so long as the original work is given appropriate credit. Contents may not be used for commercial purposes, or adapted, remixed, transformed or built upon. (<https://creativecommons.org/licenses/by-nc-nd/4.0/>)
Thieme Medical and Scientific Publishers Pvt. Ltd., A-12, 2nd Floor, Sector 2, Noida-201301 UP, India

Introduction

Iron overload is an important clinical complication that can result from iron hyperabsorption or regular blood transfusions for conditions such as thalassemia and sickle cell disease.^{1,2} Iron overload cardiomyopathy (IOC) is a major cause of premature death in patients with thalassemia major (TM), usually in their second decade.^{3,4} According to studies, 22% of thalassemia patients who underwent magnetic resonance imaging (MRI) had one or more cardiac issues, including heart dysfunction (66%), arrhythmias (14%), or both heart dysfunction and arrhythmias (14%). Heart failure and arrhythmias are responsible for more than 70% of deaths in TM.⁴⁻⁸ A study in India found that 50% of patients who received several blood transfusions had severe myocardial iron overload (MIO).³

Unless chelation therapy is drastically escalated, decompensation and death occur quickly in TM patients once cardiac symptoms appear.^{9,10} When IOC is diagnosed before the end-stage cardiac failure, appropriate medical therapy has been shown to mitigate it, emphasizing the need of early detection of IOC.¹¹ Serum ferritin has long been used to measure iron overload in the body. However, both serum ferritin and the histological liver iron concentration do not usually correlate well with the cardiac iron and hence, they should not be used to predict the risk of iron-related cardiac disease.

T2* MRI for noninvasive liver and myocardial iron quantification have been used over the last couple of decades to assess patients with numerous blood transfusions and/or suspected iron overload disorders.^{12,13} T2* MRI is now a well-established approach for assessing myocardial iron in thalassemia patients.¹⁴ This technique was first described in a seminal publication by Anderson et al, in which the authors observed that as the MIO increased, the ejection fraction decreased. Myocardial T2* value of less than 20 ms was seen in all the patients with ventricular dysfunction.¹⁴ Although currently T2* is a gold standard for MIO, there is growing interest in determining the significance of T1 mapping in detecting cardiac iron overload, particularly in detecting lower levels of cardiac iron.^{15,16} The goal of this study was to evaluate the sensitivity and specificity of myocardial T1 mapping for detecting cardiac iron overload in thalassemia patients with T2* mapping as the gold standard.

Methods

Study Design and Study Population

Consecutive TM patients attending the thalassemia clinic at our institution were prospectively enrolled between August 2019 and March 2021, after Institutional Review Board approval. Patients who did not give consent, those who had prior history of any other cardiovascular disease, and those who had contraindications to MRI were excluded. The study was performed according to the Code of Ethics (Declaration of Helsinki). Informed consent was obtained from all the patients.

MRI Acquisition

MRI was performed using a Magnetom Aera 1.5 T scanner (Siemens, Germany) using a gradient echo T2* MRI sequence done at a short-axis mid-ventricular single 8mm slice of the left ventricle (flip angle: 20 degree) for iron measurement. The T2* sequence consisted of eight echoes (range: 1.88–15.18 ms, in 1.7 ms increments). T2* values from the scanner had been validated by scanning normal controls. True-fast imaging with steady-state precession sequence was done in short axis slices (cine imaging) for the assessment of functions. Electrocardiogram (ECG) gating, phased array coils, and breath holding methods were used. T1 mapping (modified look locker inversion recovery–MOLLI sequence–Siemens) was acquired on same single 8 mm mid-ventricular short axis slice as the T2* slice using a single breath-hold ECG-gated gradient multiecho technique to generate eight images with a range of echo times. The MOLLI sequence for T1 mapping consisted of nonselective inversion recovery prepared ECG-synchronized Look-Locker trains performed consecutively in a 5s (3s) 3s pattern within a single breath-hold.

MRI Image Analysis

All MRI data was analyzed using syngo via. software (Siemens AG). Automated and semiautomated method was used for contouring the endocardial surface of the ventricle to calculate the left and right ventricular ejection fractions. T2* and T1 mapping values were analyzed by manually drawing a region of interest in the mid-septum, taking care to avoid blood volume (► Fig. 1). Analysis was performed by two blinded readers (with 8 and 6 years of CMR experience, respectively).

Statistical Analysis

The data was summarized and analyzed using statistical package for social sciences (SPSS, version 24.0) software. For the comparison of categorical data that was expressed as frequency and percentages, the chi-squared test/Fisher's exact test were used. Continuous variables were expressed as mean or median as appropriate and groups were compared using Student's *t*-test or Mann-Whitney U test depending upon normalcy of data. Sensitivity and specificity of T1 mapping to identify tissue iron overload were calculated, using T2* as the gold standard. Receiver operating characteristic (ROC) curve analysis was to establish the cutoff. A *p*-Value less than 0.05 was be used for the statistical significance of the study.

Results

A total of 103 patients (58 males and 45 females) of thalassemia underwent CMR. The mean age of patients was 17.08 ± 7.82 years (► Table 1). According to modified Kuppuswamy scale for socioeconomic status, 49.5% ($n = 51$) were class IV, 27.2% ($n = 28$) were class III and 21.4% ($n = 22$) were class V. Mean ferritin level of the patients was 2009.5 $\mu\text{g/L}$ (range: 105–4859; ► Table 2).

Cardiovascular Magnetic Resonance

All the patients underwent CMR without any complications. Images were of good quality and were conclusive in all the

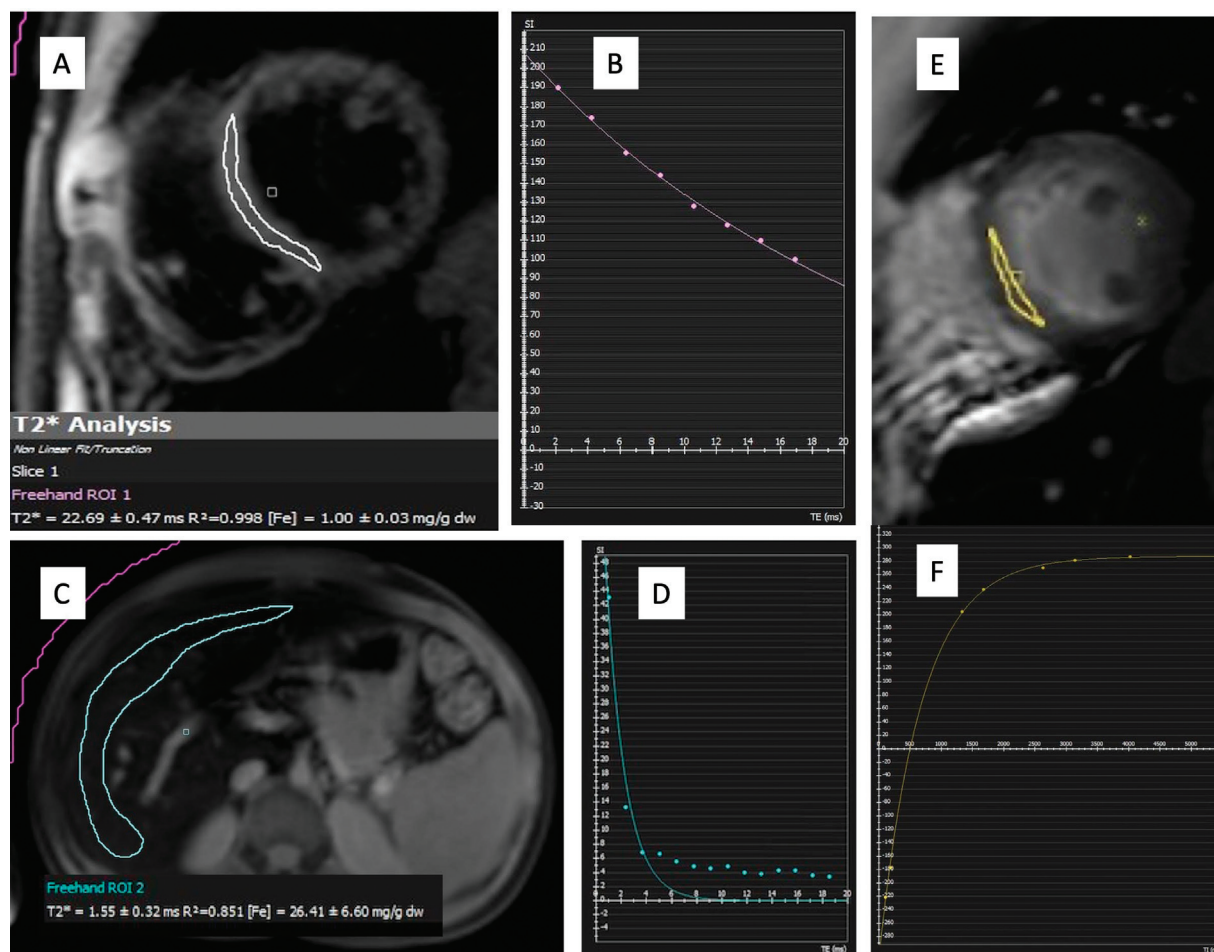


Fig. 1 T2* mapping and the decay curve of myocardium (A and B, respectively) and liver (C and D) show a T2* value of 22.69ms for myocardium (normal myocardial iron) and 1.55 ms of liver (severe iron overload). T1 map (E) and recovery curve (F) in the same patient show a T1 mapping value of 755 ms.

Table 1 Characteristics of the participants

Parameter	Total patients (n = 103)	
Age (years)	17.08 ± 7.82	
Sex	M—58 F—45	
SES (modified Kuppusswamy scale)	II	2(1.9%)
	III	28(27.2%)
	IV	51(49.5%)
	V	22(21.4%)

Abbreviation: SES, socio-economic status.

patients. Median T2* of myocardium was 33.45ms (range: 3.08–49 ms). Normal value for T2* was taken as more than 20 ms.¹⁴ Nineteen patients (18.4%) had T2* value less than 20 ms, suggesting MIO.

ROC curve analysis was done for T1 value to predict T2* less than 20ms. At a cutoff of 850 ms, T1 mapping could identify T2* less than 20ms with a sensitivity of 94.7%, specificity of 95.2% and diagnostic accuracy of 95.15% (—Fig. 2). Of note, four (4.8%) of the patients with a normal T2* (≥20ms) had an abnormally low T1 mapping value

(≤850ms; —Table 3). Only one patient with T2* less than 20ms had a T1 mapping value of more than 850 ms. However, this patient had a T1 mapping value less than 932.7 ms (normal lower limit of T1 mapping in our center). Positive predictive value (PPV) for the same was 81.8% and the negative predictive value (NPV) was 98.8%. There was excellent agreement between T1 mapping and T2* mapping for the diagnosis of MIO (Kappa: 0.848, $p < 0.001$).

No patient with T2* less than 20ms had T1 value more than 932.7 ms. Thus, no patient with T2* value of less than 20ms had normal T1 value. Twenty-three (22.3%) patients had low T1 mapping values (<932.7 ms) despite T2* values of more than 20ms and among all the patients with T2* more than 20ms, 27% had low T1 mapping value (<932.7 ms). Two patients had severe left ventricle dysfunction and both had severe iron deposition in myocardium (T2* <10ms).

Discussion

T2* is a well-established gold standard for iron quantification in liver as well as myocardium.¹⁴ In our study, we evaluated the diagnostic accuracy of myocardial T1 mapping for the assessment of MIO as compared to the T2* mapping.

Table 2 Basic biochemical and imaging characteristics of patients

	Mean ± SD	Median	Range (Min–Max)
Age	17.08 ± 7.82	15	7–47
Ferritin	2009.5	1968	105–4859
LVEF	59.99 ± 7.44	60.9	19.5–73
RVEF	55.67 ± 7.64	55.67	16.7–72
T2*(heart)	30 ± 11.04	33.45	3.08–49
T1(heart)	900.66 ± 119.74	942	507–1088
T2*(liver)	3.87 ± 4.69	2.05	0.2–27
T1(liver)	413.08 ± 65.64	412	240–620

Abbreviations: LVEF, left ventricle ejection fraction; RVEF, right ventricle ejection fraction; SD, standard deviation.

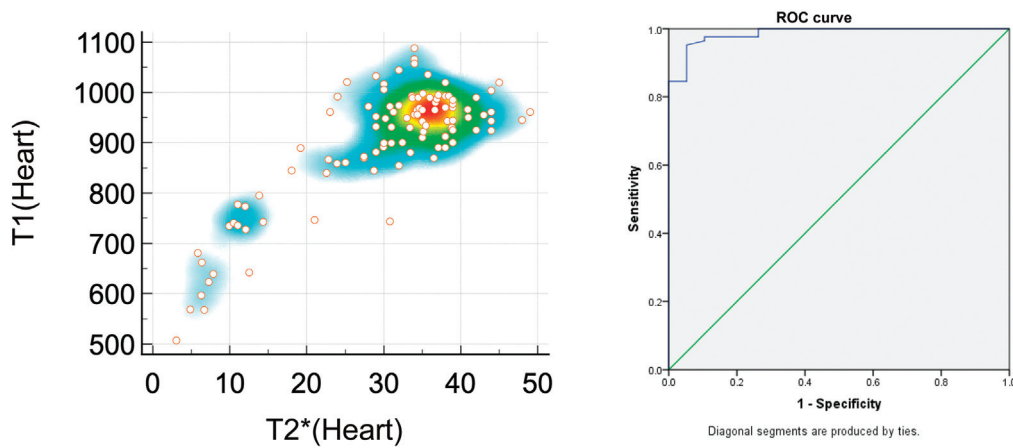


Fig. 2 Scatter diagram (left side of the panel) depicting T1 and T2* of heart. Receiver operating characteristic (ROC) curve analysis (right side of the panel) for T1 value to predict T2* < 20 ms.

Table 3 Number of patients with T1 value cutoff of 850 ms and T2* value cutoff of 20ms for the myocardium

	T2* ≥ 20ms	T2* < 20 ms	Total
T1 > 850 ms	80 (95.2%)	1 (4.8%)	81
T1 ≤ 850ms	4 (4.8%)	18 (94.7%)	22
Total	84 (100%)	19 (100%)	103

*p-Value for these measurements was <0.0001.

Our study demonstrated that T1 and T2* correlate well, and T1 value was low (<850ms) in all the patients with T2* less than 20 ms. ROC curve analysis revealed the best cutoff of native T1 mapping value as 850 ms that has high specificity (95.2%), sensitivity (94.2%), and NPV (98.8%) for diagnosing T2* of less than 20 ms. The high NPV implies that normal T1 values may rule out presence of iron in the myocardium. We did not find any patient who had normal T1 mapping values but had iron overload on T2*. This means T1 mapping value can act as additional imaging marker for presence of myocardial iron and may be helpful in centers with nonavailability or limited experience of T2*.

Shaw et al described lower cutoff (–2 standard deviation) of T1 mapping value for normal individuals as 932.7 ms in 1.5T MR scanner at our center.¹⁷ Using this value as lower

normal cutoff, 23 (22.3%) patients had low T1 mapping values, despite T2* values of more than 20ms. So, 27% patients with T2* more than 20 ms had low T1 mapping values. Torlasco et al¹⁸ also described similar findings and reported that among those with T2* more than 20 ms, 38% had low T1 with most of the subjects in the T2* range 20 to 30 ms having a low T1. The gold-standard cutpoint T2* of 20 ms for iron load assessment has been known to be conservative for prioritizing specificity. T2* may be poorly reproducible due to susceptibility artefact as iron levels leading to decreased reproducibility. Availability of second noninvasive imaging marker, I.E., T1 mapping, adds a new option for clinical application of cardiac MR.

Sado et al studied 88 patients with suspected iron overload in myocardium and reported significant correlation of

T1 mapping values with T2* ($R = 0.79, p < 0.0001$). No patient with low T2* had normal T1, but they reported that 32% ($n = 28$) of cases with a normal T2* had low myocardial T1 mapping values.¹⁷ Compared to this study, in our study, 22% of the patients with normal T2* (>20 ms) had low T1 mapping values (in >20 ms T2*). This may be due to the fact that they recruited patients with suspected MIO whereas in our study, consecutive patients of thalassemia were recruited. Also, interstudy reproducibility of T1 mapping was better than T2* in the study by Sado et al.¹⁹

A few other studies have also reported the accuracy of T1 mapping for iron overload estimation. Torlasco et al¹⁸ reported their findings in TM patients ($n = 138$). They found out that in established cardiac iron overload, T1 and T2* are concordant. However, in the T2* range of 20 to 30ms, T1 mapping appeared to detect iron overload. They suggested that T1 may detect missed iron in one out of three subjects with normal T2*, and that T1 mapping is complementary to T2*. Krittayaphong et al²⁰ derived best T1 mapping cutoff value of 887 ms for detection of MIO (T2* < 20 ms), respectively. This value is very close to the cutoff value obtained in our study. They also concluded that native T1 mapping can differentiate between severe, mild-to-moderate, and no MIO. Meloni et al²¹ ($n = 146$) studied the clinical impact of T1 mapping for detecting cardiac complications in thalassemia. They found out patients with cardiac complications had significantly lower global heart T1 values (879.3 ± 121.9 ms vs. 963.2 ± 98.5 ms; $p < 0.0001$). In patients with decreased global heart T1 value rate of cardiac complications was higher.

We found that at a T1 map cutoff of 850 ms showed high sensitivity and specificity for the diagnosis of significant MIO (T2* < 20 ms). This cutoff may be used in conjunction with T2* for determining MIO. T1 mapping provides advantage of easier clinical use as compared to T2* that usually needs offline analysis with excel sheet. Lately this analysis has been automatized with the advent of softwares such as Circle cvi42 that are not widely available and costly too. It is also important to note that T1 is less specific for MIO as compared to T2* as T1 values may be affected by presence of fat and fibrosis. Hence, in patients who have developed fibrosis, unlike T2* values, T1 mapping values may not be accurate. Hence, T2* is a more reliable marker in such patients.

Rapid CMR forms an important part of screening programs of thalassemia in India as majority of patients are from lower socioeconomic status and poorly chelated. In our study 70.9% patients were from class IV and V socioeconomic status (according to modified Kuppaswamy scale). These patients are usually poorly chelated and not on regular follow-up. We believe that T1 mapping should be included in the rapid CMR protocols for the assessment of MIO as it will identify additional cases with mild iron overload and hence improve the efficacy of the cardiac MR screening programs. These patients may require close follow-up and escalation of chelation therapy if required.

There were some limitations of our study. No histopathological correlation was performed in our cases for myocardial iron deposition. However, T2* is widely accepted as gold standard for MIO and studies have shown the correlation of

the same with histopathological iron deposition. Another limitation was that there was no follow-up of patients. Future studies with long-term follow-up are required to establish prognostic significance of T1 mapping for myocardial iron deposition.

Conclusion

Myocardial T1 mapping correlates with T2* values for quantification of MIO and has the potential to improve the iron detection in cases with normal T2* values. This would be helpful in identifying early iron deposition thus improving sensitivity of CMR protocols. We identified a cutoff of 850 ms that delivered the best sensitivity and specificity for identifying myocardial iron deposition. However, further longitudinal studies are needed in patients with low T1 map values to highlight its prognostic significance

Data Availability

The data used to support the findings of this study are available from the corresponding author upon request.

Ethical Statement

Research involved human participants The work described has been carried out in accordance with The Code of Ethics of the World Medical Association (Declaration of Helsinki) for experiments involving humans.

Ethical Approval

The study was performed according to the Code of Ethics (Declaration of Helsinki).

Informed Consent

Informed consent was obtained from all the participants.

Author Contributions

S.P.S., P.J., and V.O. wrote the manuscript and did statistical analysis. T.S., N.N., K.P.G., and M.V. helped with clinical care of the patients and conceived the study design and critically revised the manuscript for important intellectual content and final approval of the version to be submitted. S.K. helped with the images and revised the manuscript. All authors read and approved the final manuscript.

Funding

None.

Conflict of Interest

None declared.

References

- Modell B, Khan M, Darlison M, Westwood MA, Ingram D, Pennell DJ. Improved survival of thalassaemia major in the UK and relation to T2* cardiovascular magnetic resonance. *J Cardiovasc Magn Reson* 2008;10(01):42
- Marsella M, Borgna-Pignatti C, Meloni A, et al. Cardiac iron and cardiac disease in males and females with transfusion-dependent thalassemia major: a T2* magnetic resonance imaging study. *Haematologica* 2011;96(04):515–520

- 3 Merchant R, Joshi A, Ahmed J, Krishnan P, Jankharia B. Evaluation of cardiac iron load by cardiac magnetic resonance in thalassemia. *Indian Pediatr* 2011;48(09):697–701
- 4 Perifanis V, Tziomalos K, Tsatra I, Karyda S, Patsiaoura K, Athanassiou-Metaxa M. Prevalence and severity of liver disease in patients with b thalassemia major. A single-institution fifteen-year experience. *Haematologica* 2005;90(08):1136–1138
- 5 Puliyl M, Sposto R, Berdoukas VA, et al. Ferritin trends do not predict changes in total body iron in patients with transfusional iron overload. *Am J Hematol* 2014;89(04):391–394
- 6 Schmitt B, Golub RM, Green R. Screening primary care patients for hereditary hemochromatosis with transferrin saturation and serum ferritin level: systematic review for the American College of Physicians. *Ann Intern Med* 2005;143(07):522–536
- 7 Wood JC, Glynos T, Thompson A, et al. Relationship between labile plasma iron, liver iron concentration and cardiac response in a deferasirox monotherapy trial. *Haematologica* 2011;96(07):1055–1058
- 8 Brittenham GM, Griffith PM, Nienhuis AW, et al. Efficacy of deferoxamine in preventing complications of iron overload in patients with thalassemia major. *N Engl J Med* 1994;331(09):567–573
- 9 Olson LJ, Edwards WD, Holmes DR Jr, Miller FA Jr, Nordstrom LA, Baldus WP. Endomyocardial biopsy in hemochromatosis: clinicopathologic correlates in six cases. *J Am Coll Cardiol* 1989;13(01):116–120
- 10 Brittenham GM. New advances in iron metabolism, iron deficiency, and iron overload. *Curr Opin Hematol* 1994;1(02):101–106
- 11 Barosi G, Arbustini E, Gavazzi A, Grasso M, Pucci A. Myocardial iron grading by endomyocardial biopsy. A clinico-pathologic study on iron overloaded patients. *Eur J Haematol* 1989;42(04):382–388
- 12 Storey P, Thompson AA, Carqueville CL, Wood JC, de Freitas RA, Rigsby CK. R2* imaging of transfusional iron burden at 3T and comparison with 1.5T. *J Magn Reson Imaging* 2007;25(03):540–547
- 13 Ghugre NR, Coates TD, Nelson MD, Wood JC. Mechanisms of tissue-iron relaxivity: nuclear magnetic resonance studies of human liver biopsy specimens. *Magn Reson Med* 2005;54(05):1185–1193
- 14 Anderson LJ, Holden S, Davis B, et al. Cardiovascular T2-star (T2*) magnetic resonance for the early diagnosis of myocardial iron overload. *Eur Heart J* 2001;22(23):2171–2179
- 15 Pepe A, Positano V, Santarelli MF, et al. Multislice multiecho T2* cardiovascular magnetic resonance for detection of the heterogeneous distribution of myocardial iron overload. *J Magn Reson Imaging* 2006;23(05):662–668
- 16 Karamitsos TD, Francis JM, Myerson S, Selvanayagam JB, Neubauer S. The role of cardiovascular magnetic resonance imaging in heart failure. *J Am Coll Cardiol* 2009;54(15):1407–1424
- 17 Shaw M, Ojha V, Ganga KP, et al. Reference values of myocardial native T1 and T2 mapping values in normal Indian population at 1.5. Tesla scanner. *Int J Cardiovasc Imaging* 2022;38(11):2403–2411
- 18 Torlasco C, Cassinerio E, Roghi A, et al. Role of T1 mapping as a complementary tool to T2* for non-invasive cardiac iron overload assessment. *PLoS One* 2018;13(02):e0192890
- 19 Sado DM, Maestrini V, Piechnik SK, et al. Noncontrast myocardial T1 mapping using cardiovascular magnetic resonance for iron overload. *J Magn Reson Imaging* 2015;41(06):1505–1511
- 20 Krittayaphong R, Zhang S, Saiviroonporn P, et al. Detection of cardiac iron overload with native magnetic resonance T1 and T2 mapping in patients with thalassemia. *Int J Cardiol* 2017;248:421–426
- 21 Meloni A, Martini N, De Luca A, et al. Myocardial native T1 mapping and cardiac outcomes in thalassemia major. *Eur Heart J Cardiovasc Imaging* 2021;22(Supplement_1):jeaa356.311