

KID Syndrome: A Rare Genodermatosis

Sir,

Keratitis–ichthyosis–deafness (KID) syndrome is a rare congenital multisystem disorder, with a reported prevalence of less than one per 1,000,000, characterized by keratitis with corneal neovascularization, cutaneous manifestations including palmoplantar hyperkeratosis, leather grain-like keratoderma, nail dystrophy, alopecia, ichthyosiform scaling, and bilateral sensorineural hearing loss.^[1] These changes occur at or before puberty.

First described by Burns in 1915, and the KID acronym was coined by Skinner and colleagues in 1981.^[2] To date, approximately 100 cases of KID syndrome have been reported in the literature.^[3]

We report a case of a 10-year-old female who presented with widespread hyperkeratotic scaling, severe photophobia, and congenital deafness, diagnosed as KID syndrome having a classical triad. This patient is the only child of non-consanguineous parents. There was no similar family history.

There was no history of the presence of collodion membrane at birth. Within few weeks of birth, progressive, generalized xerosis developed and the entire body was covered with hyperkeratotic scales over an erythematous base giving the appearance of underlying erythroderma. Lesions over the body had a rough and grainy texture [Figure 1a]. The whole face was covered with thick yellowish scales with spared lips and periorbital regions. Presence of alopecia over the scalp as well as eyebrows and eyelashes was noticed [Figure 1b]. Few lesions had a verrucous appearance, especially over the lower limbs [Figure 1c]. The patient had severe photophobia, and ophthalmological examination showed conjunctivitis, profuse corneal vascularization, opacification, and grossly reduced visual acuity [Figure 2a and b]. The plantar and palmar surfaces presented with diffuse keratoderma having abundant and coarse scales [Figure 3a-c]. All the nails were yellowish and thickened with subungual hyperkeratosis. The patient had complete sensorineural deafness that was congenital, which eventually lead to mutism. Mucous membranes and dentition were normal. Sweating was reduced and mild mental retardation was evident. Because of blindness, deafness, and mutism, IQ test could not be done. There was no associated congenital or systemic abnormality found. Skin biopsy and Genetic study could not be done.

The patient was treated with topical emollients and keratolytics i.e., salicylic acid, which led to a significant decrease in keratotic lesions [Figure 4a-c]. She was also advised to wear a hearing aid and undergo auditory rehabilitation. Artificial tears were prescribed by an ophthalmologist. However, she was lost to follow-up after second visit.

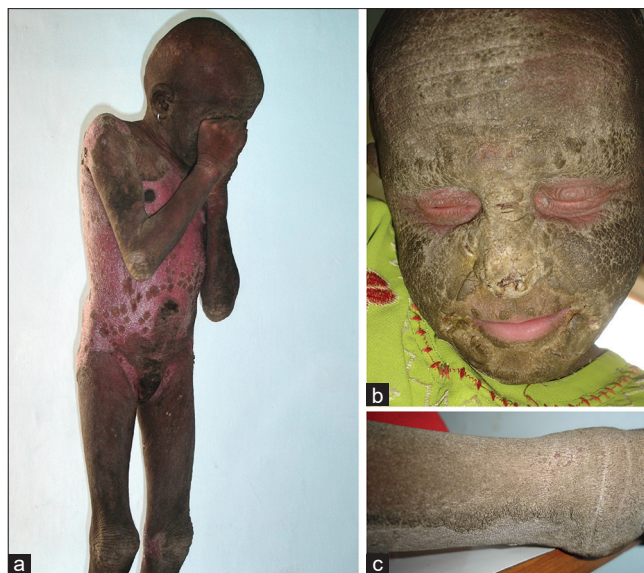

Figure 1: (a) Widespread, severe, hyperkeratotic scaly lesions over erythematous base. (b) Thick hyperkeratotic scaling on face sparing periorbital areas and lips and alopecia on scalp and eyebrows. (c) verrucous appearance of skin of leg

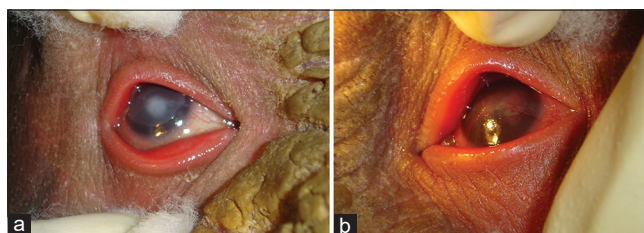


Figure 2: Ophthalmological involvement in KID syndrome (a) dense opacification of cornea (b) profuse corneal vascularization

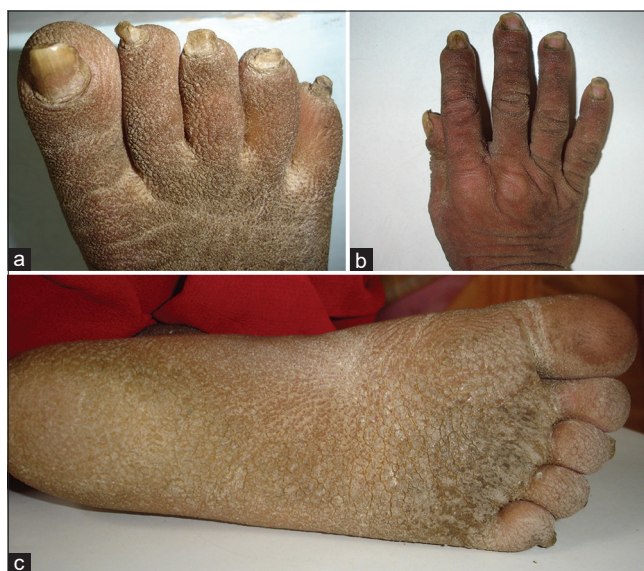

Figure 3: (a-c) Hyperkeratotic and verrucous appearance of hands and feet with yellowish and thickened nails

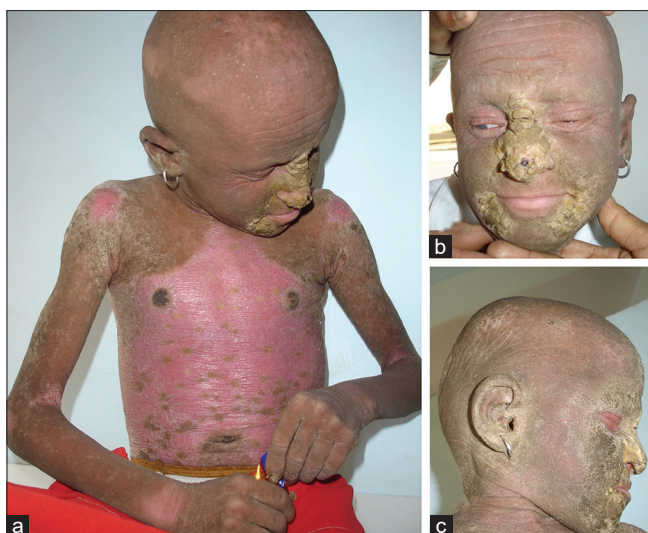

Figure 4: (a-c) Response to topical emollients and keratolytics

Cases of KID syndrome are mostly sporadic, but both autosomal recessive and dominant inheritance have been reported. It is genetically heterogeneous and is caused by missense mutations in the *GJB2* gene encoding for connexin 26 protein, which clusters at chromosome 13q12.^[4] Familial cases are rare. Only twelve families affected by this disorder were described till 2014.^[1,5]

Histopathology reveals saw-tooth epidermal morphology with basket weave hyperorthokeratosis and follicular plugs.^[6] These features are not consistent with the histopathology found in ichthyosis thus some authors suggest ichthyosis to be a misnomer in KID syndrome.

Angular cheilitis frequently develops and chronically fissured lips and gingival hyperemia have been described.^[7] Sparse hair, hypohidrosis, dystrophic nails, and abnormal dentition represent additional features. Patients have increased tendency to develop mucocutaneous infections with bacteria, fungi, and viruses.^[8]

Ocular findings, usually, start within the first year of life and are progressive. These include vascularizing keratitis, opacification of cornea, dry eyes, blepharitis, and conjunctivitis. Non-progressive, congenital, sensorineural hearing loss is consistently present.^[8] Although hearing loss is in the form of sensorineural type, conduction pathologies due to external otitis and otitis media can also be seen. Follicular occlusion triad (dissecting cellulitis of scalp, hidradenitis suppurativa, and acne conglobata) was also reported in one patient.^[9] Patients with this syndrome are considered to be at lifelong risk of development of squamous cell carcinoma of the skin or of the tongue and buccal mucosa at an unusually young age.^[1] One case of ocular surface squamous neoplasia has also been recently reported.^[10]

The treatment consists of keratolytic, topical emollients and antiseptic, antibiotic, antimycotic, and systemic

retinoids.^[1] Lubricating and anti-inflammatory agents have variable success in managing ocular disease, and cochlear implants have restored hearing in several affected individuals.^[8] Close monitoring of the skin and oral mucosa for the development of malignancy is essential.

Declaration of patient consent

The authors certify that they have obtained all appropriate patient consent forms. In the form, the legal guardian has given his consent for images and other clinical information to be reported in the journal. The guardian understands that name and initial will not be published and due efforts will be made to conceal patient identity, but anonymity cannot be guaranteed.

Financial support and sponsorship

Nil.

Conflicts of interest

There are no conflicts of interest.

**Vivek Kumar Dey, Animesh Saxena,
Shrini Parikh**


Department of Dermatology, People's College of Medical Sciences and Research Centre, Bhopal, Madhya Pradesh, India

Address for correspondence: Dr. Vivek Kumar Dey,
Department of Dermatology, People's College of Medical
Sciences and Research Centre, HIG- B/13, PCMS Campus,
Bhanpur, Bhopal, Madhya Pradesh, India.
E-mail: drvivekdey@yahoo.co.in

References

- Al Fahaad H. Keratitis-ichthyosis-deafness syndrome: First affected family reported in the Middle East. *Int Med Case Rep J* 2014;7:63-6.
- Skinner BA, Greist MC, Norins AL. The keratitis, ichthyosis, and deafness (KID) syndrome. *Arch Dermatol* 1981;117:285.
- Wolfe CM, Davis A, Shaath TS, Cohen GF. Visual impairment reversal with oral acitretin therapy in keratitis-ichthyosis-deafness (KID) syndrome. *JAAD Case Rep* 2017;3:556-8.
- Iossa S, Marciano E, Franzé A. GJB2 gene mutations in syndromic skin diseases with sensorineural hearing loss. *Curr Genomics* 2011;12:475-85.
- Markova TG, Brazhkina NB, Bliznets EV, Poliakov AV, Tavartkiladze GA. Diagnostics of keratitis-ichthyosis-deafness syndrome. *VestnOtorinolaringol* 2012;3:58-61.
- Nazzaro V, Blanchet-Bardon C, LoretteG, Civetta J. Familial occurrence of KID (Keratitis, Ichthyosis, Deafness) syndrome. *J Am AcadDermatol* 1990;23:385-8.
- Lazic T, Horii KA, Richard G, Wasserman DI, Antaya RJ. A report of GJB2 (N14K) connexin 26 mutation in two patients: A new subtype of KID syndrome. *PediatrDermatol* 2008;25:535.
- Gonzalez ME, Tloutan BE, Price HN, Patel R, Kamino H, Schaffer JV. Keratitis-ichthyosis-deafness (KID) syndrome. *Dermatol Online J* 2009;8:11.
- Maintz L, Betz RC, Allam JP, Wenzel J, Jaksche A, Friedrichs N, *et al.* Keratitis-ichthyosis-deafness syndrome in association with follicular occlusion triad. *Eur J Dermatol* 2005;15:347-52.

10. Serrano-Ahumada AS, Cortes-González V, González-Huerta LM, Cuevas S, Aguilar-Lozano L, Villanueva-Mendoza C, *et al.* Severe phenotype of keratitis–ichthyosis–deafness syndrome with presumed ocular surface squamous neoplasia. *Cornea* 2018;37:252-4.

Access this article online	
Website: www.idoj.in	Quick Response Code 
DOI: 10.4103/idoj.IDOJ_87_19	

This is an open access journal, and articles are distributed under the terms of the Creative Commons Attribution-NonCommercial-ShareAlike 4.0 License, which allows others to remix, tweak, and build upon the work non-commercially, as long as appropriate credit is given and the new creations are licensed under the identical terms.

How to cite this article: Dey VK, Saxena A, Parikh S. KID syndrome: A rare genodermatosis. *Indian Dermatol Online J* 2020;11:116-8.

Received: February, 2019. **Revised:** April, 2019.

Accepted: April, 2019. **Published:** January, 2020.

© 2020 Indian Dermatology Online Journal | Published by Wolters Kluwer - Medknow