

Computed tomography- and magnetic resonance image-based analysis of the anatomical variations of the Sylvian fissure and characteristics of the middle cerebral artery

Homajoun Maslehaty,¹
Cornelius Deuschl,² Bernadette Kleist,¹
Sophia Göricke,² Ulrich Sure,¹
Oliver Müller¹

¹Department of Neurosurgery; and

²Department of Radiology, University Hospital Essen, Germany

Abstract

The aim of this cross sectional anatomical study is to determine the distribution of the defined anatomical variations of the Sylvian fissure (SF) in a normal population and to analyze its bilateral superposable presentation. Furthermore, we examined the course of the middle cerebral artery (MCA) and the division of the MCA branches in relation to the SF types.

A total of 300 cranial CT scans - 100 CT angiography datasets and 86 MRIs of patients without intracranial pathologies - were reviewed. The SF was categorized in five types based on Yasargil's description and our previous publication. The length, diameter and branches of the MCA were measured and compared to the SF types. SPSS 23.0 for Windows® was used for statistical analysis.

We analyzed data of 300 patients (171 male, 129 female; mean age 51.6 years). Symmetric and mirror-imaged coherence of the SF was found in 266 patients (88.7%, $\chi^2(8)=3.04$, $p=0.932$). The distribution of the SF types showed significant differences in patients younger than 60 years compared to older patients. A bifurcation was observed in 72.0%. A trifurcation was observed in 12.0% and a *false bifurcation* in 16.0% of patients. There was no significant difference of the measured diameters or length of the M1 segments according to the SF types.

In this CT and MRI based anatomical study we could show that a twisted and narrow SF occurred more frequently in patients younger than 60 years of age. The SF has a high congruence intra-individually. The anatomical condition might influence the size and configuration of the proximal MCA, which in turn might influence the

surgeon's choice of the approach to the SF. Preoperative evaluation on the basis of the presented data, may help to decide for an appropriate approach to the SF.

Introduction

The Sylvian fissure (SF), or the lateral sulcus, was first illustrated in *Tabulae Pictae* by Fabrici d'Acquapendente in 1600. In 1641 Caspar Bartholin gave a detailed description of the SF. However, he attributed his work to Franciscus Sylvius, who became the eponym of this anatomical structure.¹

Anatomically, the SF is formed by the frontal, parietal and temporal lobe and can be divided in a superficial and deep part. The superficial part is composed of a stem and three rami (anterior horizontal, anterior ascending and posterior). The deep part is divided in a sphenoidal and operculoinsular portion.^{2,3} The SF gives passage to the middle cerebral artery (MCA) and enables surgical access to the insula region. Microsurgical dissection of the SF is a standard approach in neurosurgery, especially for MCA aneurysms.³⁻⁸

By his thorough intraoperative observations of the Sylvian cistern and the SF, Yasargil described four anatomical variations of the SF. The first type is defined as a straight wide SF, the second type as a straight narrow SF. The third and fourth type includes a partially herniated frontal and temporal lobe into the SF, respectively.⁹ Based on Yasargil's descriptions an adaptation of the appearance of the SF on cranial computed tomography (cCT) scanning was published before.¹⁰ For the treating neurosurgeon it is of vital importance to know about the anatomical variations when operating within or through the SF. However, this can be difficult, e.g. if an intracerebral hemorrhage or mass lesions alters the radiographic presentation. Therefore, it would be worthwhile if the surgeon could conclude from the opposite SF to the afflicted one. Hence, it is the aim of the current CT and MRI based anatomical study to determine the distribution of the defined SF types in a normal population and to analyze its bilateral superposable presentation. Furthermore we examine the course of the MCA and the division of the MCA branches in relation to the SF types.

Materials and Methods

In this cross-sectional, single center study we retrospectively reviewed plain CT

Correspondence: Homajoun Maslehaty, Department of Neurosurgery, University Hospital Essen, Hufelandstrasse 55, D - 45147 Essen, Germany.

Tel.: +49.201.7230.

E-Mail: h.maslehaty@gmx.de

Key words: Sylvian fissure; middle cerebral artery; anatomical configuration.

Conflict of interest: the authors declare no potential conflict of interest.

Received for publication: 5 September 2016.
Accepted for publication: 30 November 2016.

This work is licensed under a Creative Commons Attribution NonCommercial 4.0 License (CC BY-NC 4.0).

©Copyright H. Maslehaty et al., 2017
Licensee PAGEPress, Italy
Clinics and Practice 2017; 7:890
doi:10.4081/cp.2017.890

scans (cCT), CT angiograms (CTA) and cranial MRI of n=300 patients aged 18 years and older.

These patients were examined at our hospital for various issues others than assumed intracranial pathologies. CCT scans with evidence of intracranial aneurysms, hemorrhage, stroke and mass lesions were excluded from analysis.

The SF was classified based on our modified previous publication in five subtypes¹⁰ (Table 1 and Figure 1). Type 1 was defined as wide and straight SF, type 2 as narrow and straight SF, type 3 as a wide SF with herniation of the frontal or temporal lobe, type 4 as a narrow SF with herniation of the frontal or temporal and type 5 as a SF with herniated temporal and frontal lobe.

The classification of the SF subtypes was done bilaterally to evaluate intra-individual differences by two independent investigators (a board certified neurosurgeon and neuro-radiologist).

Additionally, a categorization of the SF was done by MRI, either using axial fluid-attenuated inversion recovery (FLAIR) or T2-weighted MR images - if available - to evaluate the comparability of the categorization of the SF types with CT and MRI.

For thorough analysis of the MCA, 100 CTA datasets were analyzed. We assessed the diameter of the M1 segment, length of the MCA from its origin from the ACI bifurcation to the distribution of the M2 branches at the limen insulae and the distribution of the M2 branches (bifurcation or trifurcation). The presence of *false bifurcation* due to an early M2 branch (mainly the temporal trunk) from the M1 segment was considered

as well. The study was approved by the local ethic committee of the University of Duisburg-Essen and conducted in accordance to the Guideline for Good Clinical Practice (15-6632-BO).

Statistical analysis

SPSS 23.0 (Statistical Package of the Social Sciences, IBM, Armonk/USA) for Windows was used for statistical analysis. Interval scaled data were displayed as means and standard deviation and categorical data as frequency and valid percent.

An inter-rater reliability analysis using Cohen’s kappa (κ) was performed to determine consistency among the raters.

To evaluate the congruence of the classification of the right and left SF, respectively of cCT and MRI, the McNemar-Bowker test was used.

Data were tested for normal distribution using the Kolmogorow-Smirnow test in addition to Q-plots. Because the assumption of normality was violated for age, the

Mann-Whitney-U Test was used to test for differences between sexes. Categorical variables were analyzed by Pearson Chi-Square test or Fisher’s exact test, if expected frequencies were below five. The assumptions of normality and homogeneity of variances were checked for one-way ANOVA (with Bonferroni *post hoc* test). If violations were observed, the Kruskal-Wallis H test was conducted.

Results

A total of n=300 plain cCT scans and n=100 CTA datasets of 129 female and 171 male patients were analyzed. Additionally, in 86 of these patients cranial MRI scans were available for further analysis. The mean age of the patients was 51.63 years (range 18-91 years; standard deviation (SD) \pm 20.09 years).

Regarding the inter-rater reliability, we

measured a Cohen’s kappa of $\kappa=0.843$ ($p<0.0001$, CI 0.761- 0.925) indicating a strong reliability.

The distribution of the SF subtypes for the total study population and for men and woman are presented in Table 2: Type 1: N=50 (16.6%), type 2: N=39 (13%), type 3: N=80 (26.6%), type 4: N=89 (29.6%) and type 5: N=42 (14%).

Sex specific distribution of the SF types showed no significant differences with $\chi^2(4)=5.44$, $p=0.247$.

Since brain atrophy may influence the categorization of the SF, we set a cut off at 60 years of age for a more specific analysis. The results are displayed detailed in Table 2. There was a significant association between age and type of the SF with $\chi^2(4) = 68.13$, $p<0.0001$. SF type 1 and 3, in terms of a wide fissure, occurred more frequently in patients older than 60 years. Vice versa, the presence of narrow SF types 2 and 4 occurred mainly in patients younger than 60 years. SF type 5 occurred almost exclusive-

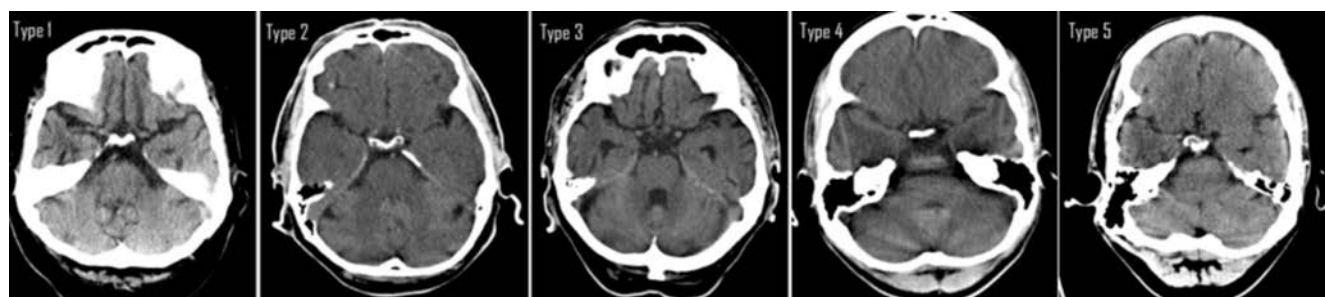


Figure 1. Definition of the Sylvian fissure types on computed tomographic scanning.

Table 1. Sylvian fissure types of the current study compared to previous description by Ngando *et al.*¹⁰

Current study		Subtypes of the Sylvian fissure (SF) Ngando <i>et al.</i>	
1	Wide straight SF	1	Straight wide or narrow SF
2	Narrow straight SF		
3	Wide SF with herniation of the frontal or temporal lobe	2	Wide SF with herniation of the frontal or temporal lobe
4	Narrow SF with herniation of the frontal or temporal	3	Narrow SF with herniation of the frontal and temporal lobe
5	Herniation of temporal and frontal lobe	4	Herniation of temporal and frontal lobe

Table 2. Distribution of the Sylvian fissure types.

	Distribution of the Sylvian fissure (SF) types					
	Total N (%)	SF 1 N (%)	SF 2 N (%)	SF 3 N (%)	SF 4 N (%)	SF 5 N (%)
	300 (100)	50 (16.7)	39 (13.0)	80 (26.7)	89 (29.7)	42 (14.0)
Male	171 (57.0)	34 (19.9)	25 (14.6)	45 (26.3)	47 (27.5)	20 (11.7)
Female	129 (43.0)	16 (12.4)	14 (10.9)	35 (27.1)	42 (32.6)	22 (17.1)
< 60 years	185 (61.7)	18 (9.7)	32 (17.3)	28 (15.1)	70 (37.8)	37 (20.0)
> 60 years	115 (38.3)	32 (27.8)	7 (6.1)	52 (45.2)	19 (16.5)	5 (4.3)

ly in patients younger than 60 years (n=37 of 42 (88.1%) (Figure 2).

Symmetric and mirror-imaged coherence of the SF was observed in 266 patients (88.7%). There was no statistically significant difference between the ratings of the SF for both hemispheres of the brain with a McNemar-Bowker chi-square value of $\chi^2(8)=3.04$, $p=0.932$. The subgroup differences in bilateral presence of the SF were inhomogeneous and showed no relevant and useful insight (n=34, each n=17 (50%) younger and older than 60 years).

Categorization of the SF types on cCT and MRI was identical in 82 of 86 patients (95.3%). There was no statistically significant differences between the ratings of the SF on cCT and MRI (McNemar-Bowker chi-square value of $\chi^2(3)=3.00$, $p=0.392$), consequently showing a comparable accuracy for determination of the SF in these two different imaging modalities.

The mean diameter of the M1 segment was 2.6 mm for all patients. The distribution of the length within the SF types is presented in Table 3. There was no significant difference between groups as determined by one-way ANOVA, $F(4, 95)=0.58$ with $p=0.680$. Additionally, the Bonferroni post-hoc test revealed no significant differences between single groups ($p>0.05$).

The mean length of the M1 segment was 16.9 mm. The distribution to the SF types is shown in Table 3. There was no significant difference in the length of the M1-segment between groups, $H(4)=5.12$, $p=0.275$.

In the majority of all cases a typical bifurcation was observed in 72.0% of 100 patients. A trifurcation was observed in 12.0% and a *false bifurcation* in 16.0%. There was no significant association between furcation and type of the SF ($p=0.611$).

Discussion

In the current CT and MRI based anatomical study we determined the distri-

bution of the anatomical variations of the SF and different characteristics of the MCA compared to the SF types.

Based on our previous work¹⁰ we made a more detailed subdivision of the SF types. In the work of Ngando *et al.*, type 1 is described as a straight wide or narrow SF. In order to analyze the presentation of a wide and narrow SF type in different age groups, the straight wide and the straight narrow SF type were examined separately in our study.

Since classification of the SF types on CT and MRI were made by two independent raters with a high Cohen's kappa of $\kappa = 0.843$, we rely on highly reliable values in the present study.

Technically, it is of note that a plain CT is well suited for classification of the SF types. However, the head of the patient has to be positioned straight without bending during scanning and reconstruction of axial slices needs to be performed carefully. Otherwise, the classification of both fissures cannot be accomplished exactly. This we observed in some trauma patients, in whom the head was bended to one side

leading to an asymmetric reconstruction of axial slices and, in consequence, making a correct classification of both SF impossible. These cases were excluded from analysis. Despite the different imaging modality of MRI, with different reconstruction techniques, classification of the SF types was equally possible with reliable results.

The distribution of the SF types has to be regarded in respect of the patient's age. We can show with our data that the distribution of the SF types differed statistically significant between patients younger than 60 years of age and those of older age. Although we observed young patients with constitutional wide fissures, SF type 1 and 3 occurred more frequently in the patient group older than 60 years. In accordance, narrow and twisted fissured (types 2, 4 and 5) occurred more frequently in younger patients. This issue can be possibly attributed to decrease of brain volume with increasing age. It can be supposed that older patients with SF type 1 and 3, might had a narrow SF type 2 or 4 in younger ages, independent of the constitutional SF type.

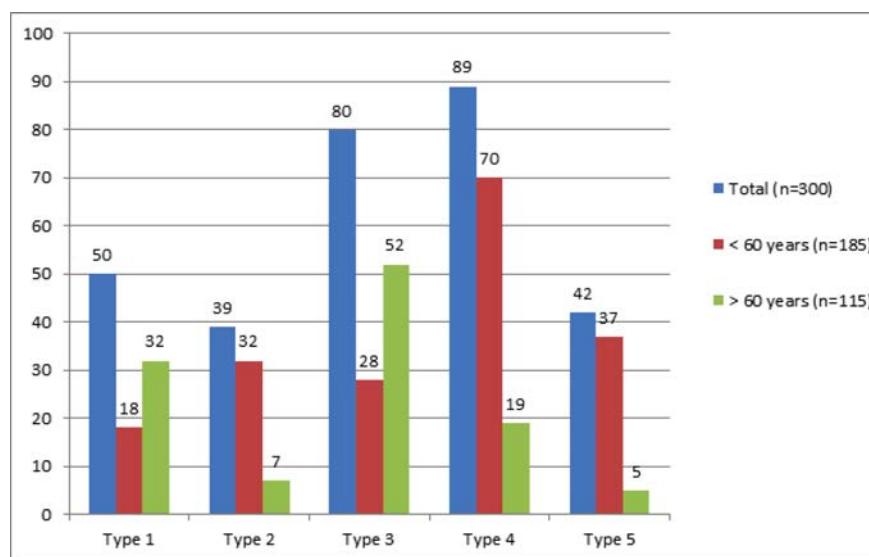


Figure 2. Graph of the distribution of the Sylvian fissure types.

Table 3. Features of the middle cerebral artery and correlation to the Sylvian fissure types.

	Total N (%)	Distribution of the Sylvian fissure (SF) types				
		SF 1 N (%)	SF 2 N (%)	SF 3 N (%)	SF 4 N (%)	SF 5 N (%)
	300 (100)	50 (16.7)	39 (13.0)	80 (26.7)	89 (29.7)	42 (14.0)
Male	171 (57.0)	34 (19.9)	25 (14.6)	45 (26.3)	47 (27.5)	20 (11.7)
Female	129 (43.0)	16 (12.4)	14 (10.9)	35 (27.1)	42 (32.6)	22 (17.1)
< 60 years	185 (61.7)	18 (9.7)	32 (17.3)	28 (15.1)	70 (37.8)	37 (20.0)
> 60 years	115 (38.3)	32 (27.8)	7 (6.1)	52 (45.2)	19 (16.5)	5 (4.3)

Hence, the SF has to be considered as a dynamic anatomical region, which underlies the alteration of the age of life. However, this is an issue, which can be analyzed in a separate study.

Idowu *et al.* showed that the left SF is longer in most humans and the angulation and course of the SF were asymmetric.¹¹ However, considering the presented classification, we found a symmetric presentation of the left and right SF, without statistically significant differences. This is of special value for the treating neurosurgeon, who can be assured that by analysis of the contralateral SF, he will be able to predict the anatomical corridor of the afflicted SF with a very high reliability (88.7%).

The diameter of the MCA was measured with mean 2.6 mm and showed no statistical differences regardless of the SF type. Considering the total length of the M1 segment, statistical analysis failed to show significant differences compared to the SF types. However, we observed the longest M1 segment in patients with SF type 4 and 5. Some short M1 segments in these SF subgroups reduced the total mean length, which led to a non-significant result. However, the SF type might influence the size and configuration of the proximal MCA in individual cases.

The insights of the current analysis have not only academic importance, but also clinical implications. Since the SF forms a corridor for surgical approach, especially for clipping of MCA aneurysms, we analyzed the occurrence of postoperative edema and ischemic lesions after microsurgery of un-ruptured intracranial aneurysms (UIA) in our earlier retrospective study. We could show a positive correlation of postoperative edema and ischemic lesions to complex in terms of narrow and twisted SF types.¹⁰ The approach to UIAs in this study was a classical pterional craniotomy with proximal opening of the SF and anterograde dissection of the M1 segment in all cases, regardless of the SF type.⁷

Considering the microsurgical treatment of MCA aneurysms, different approaches are described. To name just a few, Nathal *et al.* present a minimal invasive keyhole approach with distal opening of the SF for access the aneurysm.¹² Hernesniemi propagated the lateral supraorbital approach to access aneurysms of the anterior circulation, in which the SF is only partly opened.¹³ Dolenc presented his successful series of treating internal carotid artery (ICA) aneurysms by performing the transorbital-transclinoid and transsylvian approach, whereby the latter approach enables proximal control of the ICA.¹⁴ Pritz

and Chandler presented the transsylvian approach to MCA aneurysms and describe their experiences.¹⁵

Regardless of the different craniotomy techniques, three different types of opening the SF are provided to access MCA aneurysms. The first type is the proximal opening of the SF and anterograde dissection of the M1 segment, the second type is the distal opening and retrograde dissection of the M1 and the third type is the partial opening of the SF with direct access to the M1 segment.

It is of interest, to analyze the application of these different techniques in view of the localization of the aneurysm and the anatomical configuration of the SF. We might suggest from our data that preoperative evaluation of the SF type, might help the surgeon to decide, whether a proximal or distal opening of the SF is more suitable to reduce brain retraction or occlusion of crossing veins to prevent involuntary postoperative complications like, edema and ischemic lesions.

Conclusions

In this CT and MRI imaging based anatomical study, we could show that a twisted and narrow SF (type 2, 4 and 5) occurred more frequently in patients younger than 60 years. Vice versa wide fissured were observed significantly in older patients due to brain atrophy with increasing age. Classification of the SF types on CT and MRI was shown to be feasible and reliable. Regarding the categorization of the SF types of this study, bilateral presentation of the SF can be considered as symmetric. The anatomical condition might influence the size and configuration of the proximal MCA, which in turn might influence the surgeon's choice of the approach to the SF. Preoperative evaluation on the basis of the presented data may help to decide for a transsylvian approach or an opening of the SF from its offspring.

References

1. Collice M, Collice R, Riva A. Who discovered the sylvian fissure?. *Neurosurgery* 2008;63:623-8.
2. Tanriover N, Rhoton AL Jr, Kawashima M, et al. Microsurgical anatomy of the insula and the sylvian fissure. *J Neurosurg* 2004;100:891-922.
3. Wen HT, Rhoton AL Jr, de Oliveira E, et al. Microsurgical anatomy of the tempo-

ral lobe: part 2--sylvian fissure region and its clinical application. *Neurosurgery* 2009;65:1-35.

4. Gibo H, Carver CC, Rhoton AL Jr, et al. Microsurgical anatomy of the middle cerebral artery. *J Neurosurg* 1981;54:151-69.
5. Szikla G, Bouvier T, Hori T, Petrov V. The sylvian fissure. In: Szikla G, Bouvier T, Hori T, Petrov V, eds. *Angiography of the human brain cortex*. Berlin: Springer; 1977. pp 101-125.
6. Türe U, Yasargil DCH, Al Mefty O, Yasargil MG. Topographic anatomy of the insular region. *J Neurosurg* 1999;90:720-33.
7. Wen HT, de Oliveira E, Tedeschi H, et al. The pterional approach: Surgical anatomy, operative technique, and rationale. *Operat Techn Neurosurg* 2001;4:60-72.
8. Yasargil MG, Fox JL. The microsurgical approach to intracranial aneurysms. *Surg Neurol* 1975;3:7-14.
9. Yasargil MG. Operative anatomy. In: Yasargil MG, ed. *Microneurosurgery*. Stuttgart: Thieme Publishers; 1984. pp 252-290.
10. Ngando HM, Maslehaty H, Schreiber L, et al. Anatomical configuration of the Sylvian fissure and its influence on outcome after pterional approach for microsurgical aneurysm clipping. *Surg Neurol Int* 2013;30:129.
11. Idowu OE, Soyemi S, Atobatele K. Morphometry, asymmetry and variations of the sylvian fissure and sulci bordering and within the pars triangularis and pars operculum: an autopsy study. *J Clin Diagn Res* 2014;8:AC11-4.
12. Nathal E, Gomez-Amador JL. Anatomic and surgical basis of the sphenoid ridge keyhole approach for cerebral aneurysms. *J Neurosurg* 2005;56:178-85.
13. Hernesniemi J, Ishii K, Niemelä M, et al. Lateral supraorbital approach as an alternative to the classical pterional approach. *Acta Neurochir Suppl* 2005;94:17-21.
14. Dolenc VV. A combined transorbital-transclinoid and transsylvian approach to carotid-ophthalmic aneurysms without retraction of the brain. *Acta Neurochir Suppl (Wien)* 1999;72:89-97.
15. Pritz MB, Chandler WF. The transsylvian approach to middle cerebral artery bifurcation/trifurcation aneurysms. *Surg Neurol* 1994;41:217-9; discussion 219-20.