

# A Rare Case of an Intramedullary Spinal Cord Abscess Due to *Escherichia coli* in a Pediatric Patient

Rachel Sehgal, MD<sup>1</sup> , Elizabeth Budnik, DO<sup>2</sup>, Atul Mallik, MD, PhD<sup>3</sup>, Andrew Bonwit, MD<sup>4</sup>, and Matthew Leischner, MD<sup>4</sup>

## Abstract

Spinal cord abscess is a rare entity, particularly in the pediatric population. Spinal cord abscesses can be located in extradural, subdural and intradural (intramedullary or extramedullary) regions of the cord. Among these locations, intramedullary is extremely uncommon. There have been few case reports of intramedullary spinal cord abscess since its first description in 1830. We describe a 2 year-old boy with a history of neonatal meningitis due to *E.coli* who presented with refusal to walk and was subsequently found to have intramedullary spinal cord abscesses at multiple levels. Culture of the abscesses again revealed *E.coli*. The patient was noted to have a pit located just superiorly to his sacral spine. Imaging revealed the presence of a dorsal dermal sinus tract. It is important to evaluate anatomical abnormalities, especially in the setting of serious bacterial infections, such as meningitis, as they have the potential to serve as a reservoir for infection.

## Keywords

spinal cord abscess, dermal sinus tract, spinal MRI

Received April 30, 2020. Received revised February 1, 2021. Accepted for publication March 23, 2021.

## Brief History of Present Illness

A 2 year-old male with a history of neonatal meningitis due to *Escherichia coli* presented with refusal to walk for one week. The child was described as increasingly fussy with an intermittent limp in the few weeks prior. A review of systems was positive for weight loss (0.5 kg over the preceding 5 months), bouts of inconsolable crying, and increased irritability. Parents denied any history of recent infections, upper respiratory symptoms, or other illness.

## Past Medical, Family and Social History

The patient's medical history was significant for developmental delay and neonatal meningitis, for which he had received appropriate antibiotic therapy. In addition, he was hospitalized at our institution 5 months prior with fussiness and intermittent refusal to walk for one week. However, his refusal to walk at that time was attributed to a viral illness consistent with herpangina. His neurologic examination was normal throughout

his 2 day hospitalization and he began walking without difficulty prior to discharge.

As for his development, parents described him as a "late walker" but he had been walking without difficulty since sixteen months of age. His birth, family and social history were otherwise unremarkable. He had not travelled recently and did not attend daycare.

<sup>1</sup> Department of Pediatric Neurology, C S Mott Children's Hospital – Michigan Medicine, Ann Arbor, MI, USA

<sup>2</sup> Department of Pediatric Emergency Medicine, C S Mott Children's Hospital – Michigan Medicine, Ann Arbor, MI, USA

<sup>3</sup> Department of Radiology, Loyola University Medical Center, Maywood, IL, USA

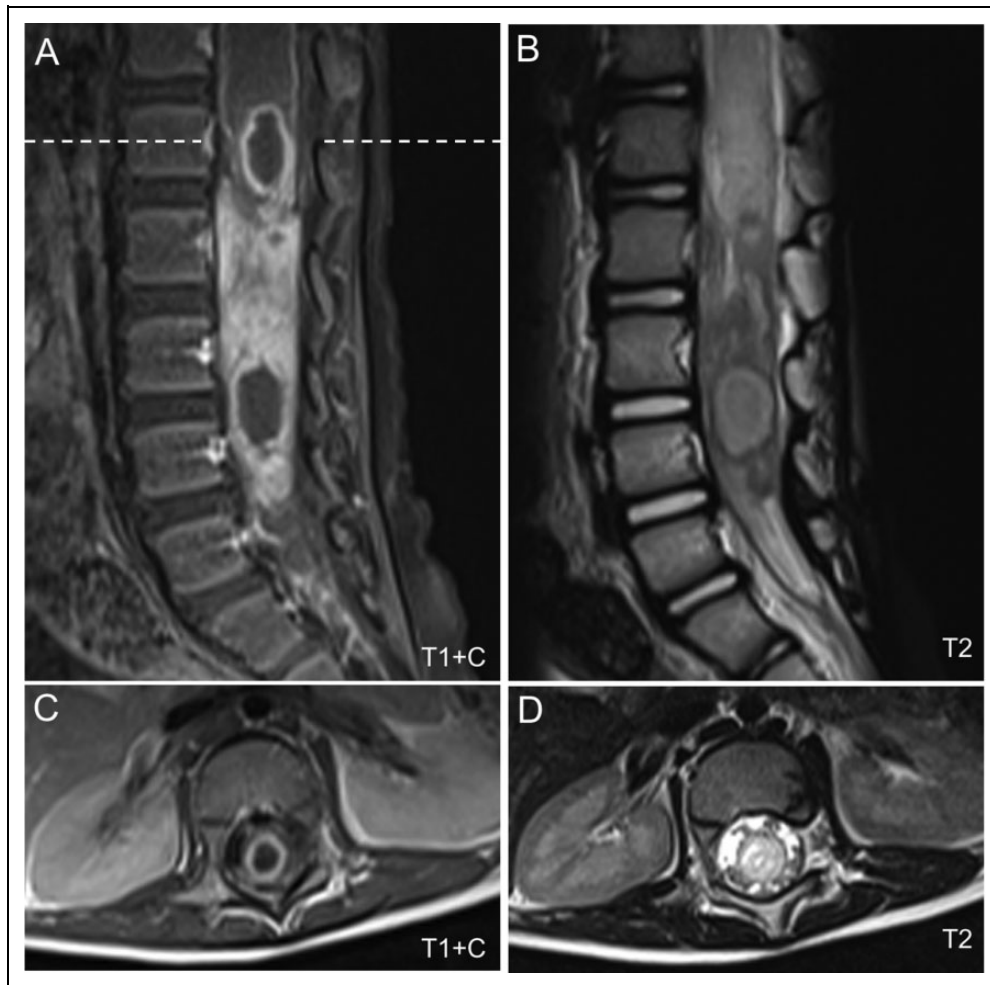<sup>4</sup> Department of Pediatrics, Loyola University Medical Center, Maywood, IL, USA

## Corresponding Author:

Rachel Sehgal, MD, C.S Mott Children's Hospital - Michigan Medicine, Department of Pediatric Neurology, 1540 E Hospital Dr, Ann Arbor, MI, 48109, USA.

Email: [rsehgal@med.umich.edu](mailto:rsehgal@med.umich.edu)





**Figure 1.** A and B: Sagittal T1 postcontrast and Sagittal T2 images 2 rim enhancing intradural abscesses. The more superior abscess is an intramedullary abscess in the conus medullaris. C and D, Axial T1 postcontrast and Axial T2 images (at the level of the dotted line in A) demonstrate the intramedullary abscess within the conus.

### Physical Examination, Initial Laboratory and Imaging Findings

In the emergency department, vital signs revealed an elevated temperature of 38.3 degrees Celsius. All other vital signs were within normal limits for age. Weight was noted to have decreased from the 25th to the 5th percentile for his age since his admission 5 months prior.

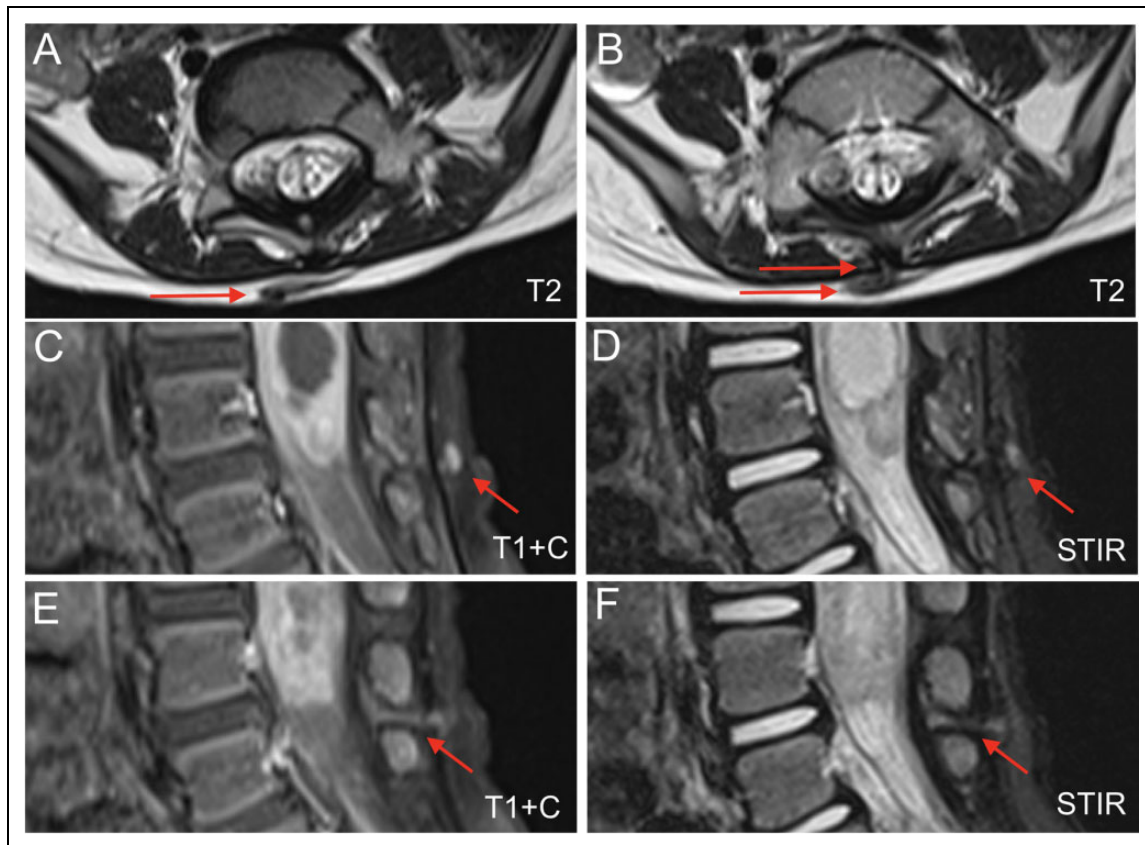
Initial physical examination was remarkable for irritability elicited by palpation of his lower extremities or attempts to bear weight. Additional examination also revealed atrophy of the musculature of his lower extremities and the presence of a pit over his midline sacral spine. There was no tuft of hair, hemangioma, or any other dermatologic abnormality associated with the sacral pit. The remainder of his physical examination was normal.

An evaluation of laboratory values revealed an elevated white blood cell count of 14.7 k/uL (reference range 4.0 - 11.0 k/uL) (48% granulocytes, 37% lymphocytes, 14% monocytes, 1% eosinophils). His sedimentation rate was 25mm/hour (reference

range 0 – 25 mm/hour). The results of C reactive protein, creatine kinase and complete metabolic panel were all unremarkable. X-rays of his lower extremities were unremarkable.

### Clinical Course during Hospitalization

The patient continued refusal to bear weight on his lower extremities. Magnetic resonance imaging of his spine revealed multiple intradural spinal abscesses including an intramedullary at the conus medullaris and extramedullary at the L4-L5 spinal level (Figure 1). The inferior extent of the spinal cord was initially not well evaluated, but was confirmed with posttreatment images (not shown). Imaging also revealed a tract that communicated between the skin and posterior spinal canal consistent with a dorsal dermal sinus tract (Figure 2). The patient underwent a laminectomy with open biopsy and spinal culture. The biopsy containing intramedullary parenchyma was consistent with reactive cell types. The spinal culture results were positive for *Escherichia coli*. He was started on an extensive course of intravenous antibiotics and physical therapy.



**Figure 2.** A and B: Sequential axial T2 images at the level of L4-L5 near the more inferior abscess demonstrate a sinus tract communicating between the skin and the posterior spinal canal (→). C-F: Sequential sagittal STIR and T1 postcontrast images demonstrate the dermal sinus tract.

### Final Diagnosis

On the basis of diagnostic imaging and spinal culture sample results, we confirmed the primary diagnosis of multiple intradural spinal cord abscesses - intramedullary and extramedullary - due to *Escherichia coli*. We also confirmed a secondary diagnosis of a dermal sinus tract based on imaging studies.

### Treatment and Follow-up

In the setting of cerebrospinal fluid cultures positive for *Escherichia coli*, the patient was started on intravenous ceftriaxone for meningitis. One month after his first laminectomy for open biopsy and spinal culture, follow up magnetic resonance imaging of his spine re-demonstrated multicystic heterogeneous enhancement filling a large portion of the lumbar spinal canal including the distal portion of the conus medullaris, cauda equina and a large portion of the thecal sac from L2 to L4 that had decreased. As a result, he underwent a second laminectomy for an intradural resection and drainage of the abscesses. The procedure was uncomplicated and he continued intravenous ceftriaxone for a total of 42 days. After initial treatment for the acute infection, and while he continued on prolonged intravenous ceftriaxone therapy, he was transferred to an inpatient rehabilitation facility for extensive physical

therapy. After discharge from the rehabilitation facility, he continued to receive outpatient developmental therapies including physical and speech therapies. The patient has now regained full motor strength and is currently meeting developmental milestones.

### Discussion

Spinal cord abscess is a rare entity.<sup>1</sup> Spinal cord abscesses can be located in extradural, subdural and intradural (intramedullary or extramedullary) spaces around or within the cord. Among these locations, intramedullary is extremely uncommon. There have been few case reports of intramedullary spinal cord abscess (ISCA) since the first description in 1830.<sup>1</sup> A high degree of clinical suspicion, with appropriate radiographic imaging is essential for early diagnosis and initiation of treatment to avoid irreversible spinal cord damage.

Our case describes a 2 year-old boy who presented with refusal to walk for one week and subsequent finding of intramedullary spinal cord abscesses at multiple levels. He had been treated for *Escherichia coli* meningitis as a neonate and culture of the spinal cord abscesses revealed *Escherichia coli* as well which is extremely uncommon for an intramedullary abscess.<sup>2</sup> This patient was also noted to have a pit over his sacral spine. Further investigation demonstrated a tract

extending from the skin to the spinal cord concerning for a dorsal dermal sinus tract.

Dermal sinus tract is defined as an abnormal connection between epithelium and the underlying spinal cord, meninges, or subarachnoid space.<sup>3</sup> The incidence is approximately 1 in 2500 live births.<sup>3</sup> During normal fetal development, the cutaneous ectoderm normally separates from neural ectoderm.<sup>3</sup> When this process fails, this connection can persist and result in a dermal sinus tract. This tract can potentiate possible passage of various organisms and cause infections such as meningitis and/or spinal cord abscess.<sup>3,4</sup> These complications may result in neurologic impairment. When infection is associated with a dorsal dermal sinus tract, the pathogens are typically related to skin flora (*Staphylococcus aureus* and *Streptococcus pneumoniae*).<sup>2</sup>

Our patient's intramedullary abscess was caused by *Escherichia coli*. This is unusual because *Escherichia coli* meningitis is more prevalent in infants less than 2 months of age. Our patient did have a history of *Escherichia coli* meningitis as well as a physical exam and diagnostic imaging consistent with a dorsal dermal sinus tract. We suspect that the dorsal dermal sinus tract may have served as a reservoir for infection, given the very unlikely coincidence of 2 neurologic infections with the same pathogen.

It is important to consider ISCA in the differential diagnosis for a patient presenting with neurologic symptoms localizing to a spinal cord level. The presence of a midline sacral pit should alert the clinician to the possibility of a dermal sinus tract, as demonstrated in our case. Anatomical abnormalities such as a dermal sinus tract should be investigated thoroughly, particularly in the setting of bacterial meningitis and/or spinal abscess,

as prophylactic surgery may be indicated to prevent infections of the central nervous system.


### Declaration of Conflicting Interests

The author(s) declared no potential conflicts of interest with respect to the research, authorship, and/or publication of this article.

### Funding

The author(s) received no financial support for the research, authorship, and/or publication of this article.

### ORCID iD

Rachel Sehgal, MD  <https://orcid.org/0000-0002-8894-5708>

### Ethical Approval

The institutional review board at Loyola University Medical Center has reviewed and approved this manuscript.

### References

1. Hart J. Case of encysted abscess in the center of the spinal cord. *Med Chir Rev*. 1831;14(27):284-286.
2. Vo DT, Cravens GF, Germann RE. Streptococcus pneumoniae meningitis complicated by an intramedullary abscess: a case report and review of the literature. *J Med Case Rep*. 2016;10(1):290. doi:10.1186/s13256-016-1080-7
3. Tisdall M, Hayward R, Thompson D. Congenital spinal dermal tract: how accurate is clinical and radiological evaluation? *J Neurosurg Pediatr*. 2015;15(6):651-656. doi:10.3171/2014.11.PEDS14341
4. Swanson D. Meningitis. *Pediatr Rev*. 2015;36(12):514-526. doi:10.1542/pir.36-12-514.