

# Clonorchiasis Complicated with Diffuse Parenchymal Lung Disease in Children

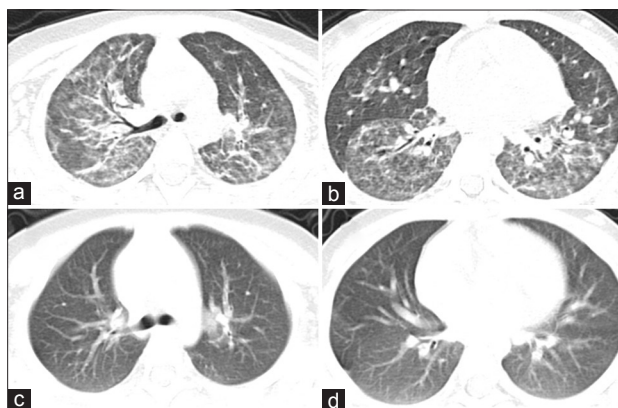
Yuan-Jian Sheng, Dan Xu, Lei Wu, Zhi-Min Chen

Department of Pulmonology, The Children's Hospital of Zhejiang University School of Medicine, Hangzhou, Zhejiang 311052, China

To the Editor: Clonorchiasis is a biliary tract disease caused by *Clonorchis sinensis*, which is widely distributed in East Asia, including China. Diffuse parenchymal lung diseases (DPLDs) comprise a large and heterogeneous group of disorders characterized by diffuse infiltrates, restrictive functional defect, and disordered gas exchange. *C. sinensis* infection is seldom associated with pulmonary manifestation. Here, we report a case of clonorchiasis complicated with DPLD in a child.

A 23-month-old previously healthy female child was admitted to our hospital with a 1-month history of progressive cough and a 3-week history of wheezing. She had a dry cough and dyspnea. She developed a fever lower than 39°C during two episodes, which both lasted for only 1 day. She and her parents liked to eat raw freshwater crayfish. On physical examination, the child was pale and tachypneic (respiratory rate 56/min) with bilateral rales. She required 2 L/min oxygen delivered by catheter to maintain normal oxygen saturation. The rest of the examination was unremarkable. Both chest X-ray and computed tomography (CT) [Figure 1a and 1b] showed bilateral ground-glass attenuation and reticular opacities, which suggested DPLD. Her pulmonary function test revealed patterns of restrictive lung disease. Ultrasound showed no remarkable change in the liver or gallbladder. Arterial blood gas analysis showed pH 7.429, PaO<sub>2</sub> 51.2 mmHg, and PaCO<sub>2</sub> 40.5 mmHg. The white blood cell count was  $4.70 \times 10^9/L$  with 41.2% neutrophils and 9.7% eosinophils. C-reactive protein was <1 mg/L. *C. sinensis*-specific IgG in the serum was positive in a dot immuno-gold filtration assay established by Wang *et al.*<sup>[1]</sup> However, examination of the feces failed to find *C. sinensis* eggs. Anti-nuclear antibody was positive. Other serological analyses for collagen vascular disease were negative. Serum total IgE level and parameters for liver and kidney functions were normal. Pathogen investigations for other bacteria, viruses, and parasites were all negative. On diagnosing *C. sinensis* infection, two courses of praziquantel were prescribed, after which the cough and dyspnea improved. CT analysis 4 months later showed the curing of interstitial pneumonia [Figure 1c and 1d]. During 2 years of follow-up, the child was symptom-free.

The symptoms of clonorchiasis are indigestion, abdominal discomfort, and diarrhea; it may also be asymptomatic. Major complications are gallstones, pyogenic cholangitis and abscess, and cholangiocarcinoma. Clonorchiasis can be transmitted through the



**Figure 1:** Chest computed tomography of the patient: (a and b) Images before praziquantel treatment; (c and d) images 4 months after praziquantel treatment.

ingestion of raw freshwater fish or shellfish or through unwashed kitchen knives, towels, kitchen boards, and/or the hands of the cook or handler. This patient liked to eat raw freshwater crayfish, through which transmission might have occurred. The worm burden increases gradually with age. Individuals with typical clinical manifestations of disease are usually more than 30 years old. The standard diagnosis of clonorchiasis is made through a fecal examination. However, it is not easy to detect a small number of *C. sinensis* eggs in patients with a slight infection with a fecal examination. Alternative diagnostic methods, including GIFA, have been developed.<sup>[1]</sup> In this case, we failed to find *C. sinensis* eggs in the patient's feces. This negative result may have been due to a low number of eggs per gram of feces. In this case, a diagnosis of *C. sinensis* infection was based on a positive result of a serum-specific antibody to *C. sinensis*, elevated eosinophilia (9.7%), and the effectiveness of praziquantel.

**Address for correspondence:** Dr. Zhi-Min Chen,  
Department of Pulmonology, The Children's Hospital of Zhejiang  
University School of Medicine, Hangzhou, Zhejiang 310052, China  
E-Mail: chenzm@zju.edu.cn

This is an open access article distributed under the terms of the Creative Commons Attribution-NonCommercial-ShareAlike 3.0 License, which allows others to remix, tweak, and build upon the work non-commercially, as long as the author is credited and the new creations are licensed under the identical terms.

© 2017 Chinese Medical Journal | Produced by Wolters Kluwer - Medknow

**Received:** 04-07-2017 **Edited by:** Li-Min Chen  
**How to cite this article:** Sheng YJ, Xu D, Wu L, Chen ZM. Clonorchiasis Complicated with Diffuse Parenchymal Lung Disease in Children. Chin Med J 2017;130:2895-6.

## Access this article online

### Quick Response Code:



**Website:**  
www.cmj.org

**DOI:**  
10.4103/0366-6999.219162

We report the first case of clonorchiasis complicated with DPLD in a child. Signs and symptoms, history, imaging results, and pulmonary function test, all supported DPLD. Several pieces of evidence supported a conclusion that *C. sinensis* was the cause of DPLD. First, when the clinical presentation and radiologic examination were at the gravest stage, serum antibody tests for *C. sinensis* were positive. Other specific underlying reasons were not discovered. Second, corticosteroid, the first choice DPLD treatment, was not applied to this patient. However, anti-*C. sinensis* treatment provided a clinical improvement in the DPLD. Third, a 2-year follow-up being normal could have led to a reoccurrence of DPLD in the absence of corticosteroid management.

Although invasive parasitic diseases, including some that infect the lungs, do occur, only a few parasites cause DPLD. *Strongyloides stercoralis* hyperinfection can mimic accelerated idiopathic pulmonary fibrosis.<sup>[2]</sup> A case of interstitial pulmonary fibrosis and spontaneous pneumothorax associated with *Schistosoma haematobium* was reported in South Africa.<sup>[3]</sup> In laboratory settings, Retnla-/- mice developed fibrosis in their lungs after being challenged with *Schistosoma mansoni* eggs.<sup>[4]</sup> A variety of cytokines (especially Th2 cytokines), chemokines, and growth factors play important roles in regulating pulmonary fibrosis. In this case, *C. sinensis* could have induced DPLD in similar manner as *C. sinensis* infection is also associated with Th2 cytokines. The exact mechanism needs further investigation. This case should remind pediatricians to include clonorchiasis in the differential diagnosis of DPLD with peripheral eosinophilia in children from areas where *C. sinensis* is endemic.

## Declaration of patient consent

The authors certify that they have obtained all appropriate patient consent forms. In the form, the guardian(s) of the patient(s) has/have given his/her/their consent for his/her/their images and other clinical information to be reported in the journal. The guardians of the patients understand that their names and initials will not be published and due efforts will be made to conceal their identity, but anonymity cannot be guaranteed.

## Financial support and sponsorship

This study was supported by a grant from the Project of Zhejiang Provincial Education Department (No. Y201431434).

## Conflicts of interest

There are no conflicts of interest.

## REFERENCES

1. Wang Y, Tang Y, Gan X. Rapid detection of specific IgG in sera of patients with infection of *Sparganum mansoni* by dot immuno-gold filtration assay. *Chin J Zoonoses* 2008;24:319-21. doi: 10.3969/j.issn.1002-2694.2008.04.009.
2. Vijayan VK. Parasitic lung infections. *Curr Opin Pulm Med* 2009;15:274-82. doi: 10.1097/MCP.0b013e328326f3f8.
3. Feldman C, Kallenbach J, Sutej P, Lewis M, Goldstein B. Diffuse interstitial pulmonary fibrosis and spontaneous pneumothorax associated with *Schistosoma haematobium* infestation of the lungs. A case report. *S Afr Med J* 1986;69:138-9.
4. Pesce JT, Ramalingam TR, Wilson MS, Mentink-Kane MM, Thompson RW, Cheever AW, et al. Retnla (relmalph/fizz1) suppresses helminth-induced Th2-type immunity. *PLoS Pathog* 2009;5:e1000393. doi: 10.1371/journal.ppat.1000393.