

In-stent Anchoring Facilitating Side-branch Balloon Delivery for Final Kissing: A Prospective, Single-center Registry Study

Yu Zhou¹, Han Xiao¹, Yu-Qing Wang¹, Huan-Yun Liu², Pang Bao¹, Yao-Ming Song¹, Lorenzo Azzalini³, Lan Huang¹, Xiao-Hui Zhao¹

¹Institution of Cardiovascular Research, Xinqiao Hospital, Third Military Medical University, Chongqing 400037, China

²Department of Cardiovascular, First People's Hospital of Chongqing New North Zone, Chongqing 401120, China

³Interventional Cardiology, San Raffaele Scientific Institute, Milan, Italy

Abstract

Background: Recrossing the compromised side branch (SB) with a balloon is sometimes technically challenging. The aim of this study was to evaluate whether in-stent anchoring (ISA) is safe and effective to facilitate SB balloon delivery for final kissing.

Methods: One hundred and fifty-nine consecutive patients were included (166 bifurcation lesions) in this prospective, single-center registry. ISA was used as a bailout method after unsuccessful SB crossing using conventional techniques, including low-profile balloons. Technique success was defined as SB balloon delivery and final kissing.

Results: Kissing-balloon delivery was successfully performed with conventional strategies in 149 of 166 lesions (89.8%). In the remaining 17 lesions (10.2%), recrossing of the main vessel stent strut was not successful; therefore, ISA was attempted. The balloon successfully crossed the stent struts, and final kissing was achieved in 15 of 17 lesions (88.2%). Total final kissing was achieved in 164 of 166 lesions (98.8%), with success rates of 100% in the single-stent group and 97.6% in the two-stent group. Two cases without balloon delivery had complex bifurcation lesions with severe calcification. There was no vessel dissection in the anchoring zone.

Conclusions: ISA is safe and effective for recrossing stent struts when conventional low-profile balloons have failed. However, large-scale trials are warranted for further evaluation.

Key words: Bifurcation; In-stent Anchoring; Percutaneous Coronary Intervention

INTRODUCTION

Bifurcation lesions are among the most frequently approached and challenging coronary lesions for percutaneous coronary intervention (PCI).^[1] However, treatment of these lesions is still limited by low rates of procedural success and high rates of clinical and angiographic restenosis.

Kissing-balloon (KB) inflation is mandatory in any two-stent strategy to optimize stent apposition, correct stent deformation or distortion, reduce angiographic side-branch (SB) (re) stenosis, and improve outcomes.^[2] KB inflations may also be used during provisional stenting when an angiographically significant (>75% diameter stenosis [DS] or thrombolysis in myocardial infarction [TIMI] flow <3) ostial SB lesion remains after main vessel (MV) stent implantation.^[1,3] However, recrossing a compromised or obstructed SB with a conventional balloon can often be time consuming, and the success rate varies.^[4-7]

We previously described an improved in-stent anchoring (ISA) technique that allowed easy balloon delivery and avoided possible vascular injury.^[8] This prospective, single-center registry study aimed to evaluate the safety and efficiency of ISA after mid-term follow-up.

METHODS

Study population

The study protocol was approved by the Ethics Committee of Xinqiao Hospital. All patients signed written informed consents.

Address for correspondence: Prof. Xiao-Hui Zhao, Institution of Cardiovascular Research, Xinqiao Hospital, Third Military Medical University, 183 Xinqiao Street, Shapingba District, Chongqing 400037, China
E-Mail: doctorzhaoxiaohui@yahoo.com

This is an open access article distributed under the terms of the Creative Commons Attribution-NonCommercial-ShareAlike 3.0 License, which allows others to remix, tweak, and build upon the work non-commercially, as long as the author is credited and the new creations are licensed under the identical terms.

For reprints contact: reprints@medknow.com

© 2016 Chinese Medical Journal | Produced by Wolters Kluwer - Medknow

Received: 14-07-2016 **Edited by:** Yi Cui

How to cite this article: Zhou Y, Xiao H, Wang YQ, Liu HY, Bao P, Song YM, Azzalini L, Huang L, Zhao XH. In-stent Anchoring Facilitating Side-branch Balloon Delivery for Final Kissing: A Prospective, Single-center Registry Study. Chin Med J 2016;129:2666-9.

Access this article online

Quick Response Code:



Website:
www.cmj.org

DOI:
10.4103/0366-6999.193439

In-Stent Anchoring Registry (registration number ChiCTR-ONC-13004236) is a prospective, single-center registry of consecutive patients with coronary bifurcation lesions (MV diameter ≥ 2.75 mm; SB diameter ≥ 2.0 mm). Experienced investigators (Lan Huang and Xiao-Hui Zhao) confirmed the following criteria of KB delivery by reviewing all patient angiograms: two drug-eluting stent implantations and SB compromise ($>75\%$ DS, TIMI flow <3 , or chest pain) after MV stenting. All patients were included between December 2012 and March 2015.

Patients were excluded from clinical outcomes analysis if they met one or more of the following exclusion criteria: insufficient patient data or patients lost to follow-up.

Percutaneous coronary intervention

Aspirin (300 mg/d) and clopidogrel (loading dose of 300 mg/d and maintenance dose of 75 mg/d) were administered at least 24 h before the procedure. Bifurcations were classified according to the Medina classification whereby the proximal MV, distal MV, and SB components of the bifurcation are each assigned a score of 1 or 0 depending on the presence or absence of $>50\%$ stenosis.^[9] The PCI was performed with a femoral (17 patients) or radial (142 patients) approach using 6 or 7 French-guiding catheters (18 and 141 patients, respectively) at the discretion of the operator. The stenting strategy was determined according to the European Bifurcation Club recommendations and the operator's discretion.^[1] For the stenting procedure, a paclitaxel-eluting stent (Taxus, Boston Scientific, Natick, MA, USA) and sirolimus-eluting stents (ExcelTM, Jiwei Medical, Shandong, China) were used.

For rewiring, the reverse wire technique was used to achieve distal recrossing in the single-stent group by advancing a guidewire with a bended tip into the distal MV and then carefully retracting the wire while turning and directing it toward the SB.^[10] However, a middle- to distal-position was achieved with a two-stent technique. Although the proximal optimization technique (POT) is recommended by the European Bifurcation Club to facilitate recrossing of SB,^[11] it is difficult to accurately position the POT balloon in cases with severe ostial SB stenosis, and the technique may involve the risk of SB occlusion after inflation.^[1] Therefore, we only attempted POT in the two-stent group.

ISA was used as a bailout method [Supplementary Figure 1] after unsuccessful SB crossing, using the conventional technique with low-profile balloons (1.2–1.5 mm). For final kissing, noncompliant balloons were recommended, and their sizes were chosen according to MV stent and SB diameter.

Coronary artery dissection was diagnosed by performing coronary angiography. Findings included the appearance of a radiolucent intimal flap or slow clearance of contrast from the false lumen.^[12]

Clinical follow-up

Major adverse cardiac events (MACEs) were the composite of nonfatal myocardial infarction (MI), death, and target

vessel revascularization (TVR). TVR was defined as any revascularization procedure involving the target vessel because of luminal renarrowing in the presence of symptoms or objective signs of ischemia. MI was defined by creatine kinase concentrations that were more than double the normal, with positive concentrations of creatine kinase-MB or troponin I or T.

RESULTS

Baseline characteristics

There were 518 patients with bifurcation lesions that needed SB protection within 26 months. The single-stent technique was planned in 453 patients, and the two-stent technique was planned in 65 cases (68 lesions). However, a tight lesion ($>75\%$ DS or TIMI flow <3) was present in 94 patients (98 lesions) in the single-stent group. After the KB procedure, 14 of 94 single-stent cases (15 lesions) needed an additional stent. Thus, the single- and two-stent techniques were performed in 80 and 79 patients, respectively (83 lesions, each).

A total of 159 patients (166 lesions) were initially included in the analysis; baseline characteristics are shown in Table 1. All patients were followed up for 9 months.

Percutaneous coronary intervention and clinical follow-up

Rewiring was successful in all cases, and a third wire was used in 22 single-stent patients when TIMI flow <3 was present and in 15 two-stent patients when SB balloon recrossing failed. The type of two-stent strategies included mini-crush ($n = 34$), crush ($n = 6$), T ($n = 20$), T-stenting and small protrusion (TAP) ($n = 13$), culotte ($n = 9$), and V ($n = 1$). Angiographic and PCI characteristics are shown in Table 2

We successfully achieved the KB with conventional strategies using 1.2–1.5 mm balloons in 149 of the 166 lesions (success rate, 89.8%). For subgroups, the successful rate

Table 1: Baseline characteristics of study participants

Characteristics	Total ($n = 159$)	Two stents ($n = 79$)	One stent ($n = 80$)
Age, mean \pm SD (years)	62.3 \pm 10.2	62.8 \pm 9.7	61.7 \pm 10.7
Male, n (%)	136 (85.5)	68 (86)	68 (85)
EF, mean \pm SD (%)	62.6 \pm 6.0	62.4 \pm 5.9	62.8 \pm 6.2
Smoker, n (%)	112 (70.4)	54 (68.4)	58 (72.5)
Alcohol consumption, n (%)	84 (52.8)	43 (54.4)	41 (51.3)
Hypertension, n (%)	84 (52.8)	45 (57.0)	39 (48.8)
Diabetes mellitus, n (%)	34 (21.4)	15 (19.0)	19 (23.8)
Hyperlipidemia, n (%)	49 (30.8)	22 (27.8)	27 (33.8)
History of PCI or MI, n (%)	19 (11.9)	9 (11.4)	10 (12.5)
Unstable, n (%)	105 (66.0)	51 (64.5)	54 (67.5)
STEMI, n (%)	44 (27.7)	23 (29.1)	21 (26.2)
Non-STEMI, n (%)	7 (4.4)	3 (3.8)	4 (5.0)
Stable angina pectoris, n (%)	3 (1.9)	1 (2.6)	1 (1.3)

EF: Ejection fraction; MI: Myocardial infarction; PCI: Percutaneous coronary intervention; STEMI: ST-segment elevation myocardial infarction.

Table 2: Angiographic and PCI characteristics of study participants, n (%)

Characteristics	Total	Two stents	One stent
Bifurcation lesions	166	83	83
Left main	33 (19.9)	23	10
LAD/diagonal	109 (65.7)	50	59
LCX/marginal branch	18 (10.8)	8	10
RCA/posterior descending	6 (3.6)	2	4
Severe calcification	8 (4.8)	4	4
Medina classification			
True bifurcations	144 (86.8)	79 (95.2)	65 (78.3)
1.1.1	109 (65.7)	59 (71.1)	50 (60.2)
0.1.1	8 (4.8)	6 (7.2)	2 (2.4)
1.0.1	27 (16.3)	14 (16.9)	13 (15.7)
1.1.0	19 (11.4)	4 (4.8)	15 (18.1)
1.0.0	3 (1.8)	0	3 (3.6)
Stent types			
PES	35	16	19
SES	131	67	64
Technique evaluation			
Success rates of conventional technique	149 (89.8)	73 (88.0)	76 (91.6)
Total success rates after ISA	164 (98.8)	81 (97.6)	83 (100)

LAD: Left anterior descending; LCX: Left circumflex; ISA: In-stent anchoring; PCI: Percutaneous coronary intervention; RCA: Right coronary artery; PES: Paclitaxel-eluting stent; SES: Sirolimus-eluting stents.

of KB was 91.6% (76/83) in the single-stent strategy, 85% (34/40) in the mini-crush/crush group, 90.9% (30/33) in T/TAP, and 90% (9/10) in the culotte/V technique. In the remaining 17 lesions (10.2%), recrossing of the MV stent strut was not successful; therefore, ISA was attempted as a bailout approach. The balloon successfully crossed the stent struts in 15 lesions (88.2%), and the final KB was placed in 164 of the 166 lesions (98.8%), with success rates of 100% in the single-stent group and 97.6% in the two-stent group. Subgroup analysis showed that the KB rate was 100% in the T/TAP/culotte group, but decreased to 95% (38/40) when using the mini-crush/crush techniques. The two cases without final procedural success had complex bifurcation lesions with severe calcification, and one case developed acute MI. There was no vessel dissection in the anchoring zone.

The cumulative MACE rate was 8.18% at 9 months and included four cardiac deaths, two nonfatal MIs, and seven TVRs. There were three definite stent thromboses.

DISCUSSION

The balloon-anchoring technique was first reported by Fujita *et al.* in 2003 for facilitating balloon/stent delivery across chronic lesions with total occlusion.^[13] However, potential vessel dissection and acute occlusion caused by balloon inflation could occur at the site of anchoring.^[14,15] We previously reported that ISA facilitated balloon delivery for final kissing.^[8] Using this method, the noncompliant balloon is inflated in the anchored zone where the intima is covered and protected by the stent. Thus, there is no risk of vessel dissection and serious injury when higher inflation pressure (12 atm) is applied. In this study, we did not find coronary artery dissection after ISA in any of our 15 patients.

At the same time, the balloon could be advanced because the anchored balloon did not block the SB ostium.

Carina, plaque shift, and presence of stent struts in the ostium were mainly caused by mechanical extrusion and are the leading obstacles to equipment delivery during bifurcation intervention. Crossing with a balloon is more challenging and is unsuccessful in 15–20% of cases when an appropriately sized balloon (2.5 or 3.0 mm) is used.^[16]

Low-profile balloons are generally accepted as the first choice and solve the problem in most cases. It is also reported that a short, dedicated glider balloon is an effective strategy for recrossing stent struts when conventional low-profile balloons fail.^[17] In this study, we used a 1.2–1.5 mm balloon for SB recrossing and achieved a success rate of 89.8%. In the remaining 15 patients (10.2%), MV stent strut recrossing was not successful, and therefore, ISA was attempted as a bailout approach. The balloon successfully crossed the stent struts in 12 lesions (88.2%) and a final KB was achieved in the great majority of lesions, with a success rate of 100% in the single-stent group and 97.6% in the two-stent group, respectively. These results indicate that ISA is an effective balloon delivery strategy for recrossing stent struts when conventional, low-profile balloons fail. Furthermore, no additional equipment is needed for ISA. Therefore, trying this technique may shorten the surgery time if the KB is necessary. In addition, if the ISA technique fails, it is likely complementary to other techniques, such as the use of a glider balloon.

Whenever possible, final KB dilation should be performed in complex bifurcation lesions requiring the double-stenting technique.^[1] In the crush-treated patients, three layers of struts covering the SB ostium make the rewiring and balloon

insertion through stent struts laborious.^[18] Our study also found that the two failure cases were all in the crush subgroup and had a lower KB rate. However, the double-kissing crush technique is reported to significantly improve the kissing rate and outcomes.^[19]

There are some limitations of our study. The major one is the small number of patients who underwent ISA technique (3.28%, 17/518). Therefore, we could not address the role of important factors, such as different stent design and bifurcation stenting technique, including crush and culotte, in the occurrence of SB balloon delivery and KB. Second, the true incidence of coronary artery dissection is likely to be underestimated only on angiography. Therefore, intravascular ultrasound and optical coherence tomography would be more reliable. Third, a preimplanted stent is necessary. Fourth, a short, noncompliant balloon is recommended because it is easy to position and covered by the stent. Fifth, a guiding catheter ≥ 6 Fr is needed for two balloon catheters to operate together. Finally, although the coronary artery is transiently blocked by anchored balloon dilation (for <30 s), the interruption of blood flow may also cause an uncomfortable sensation.

In conclusion, our study indicated that ISA is a safe and effective balloon delivery strategy for recrossing stent struts when conventional, low-profile balloons fail. However, large-scale trials are warranted for further evaluation.

Supplementary information is linked to the online version of the paper on the Chinese Medical Journal website.

Financial support and sponsorship

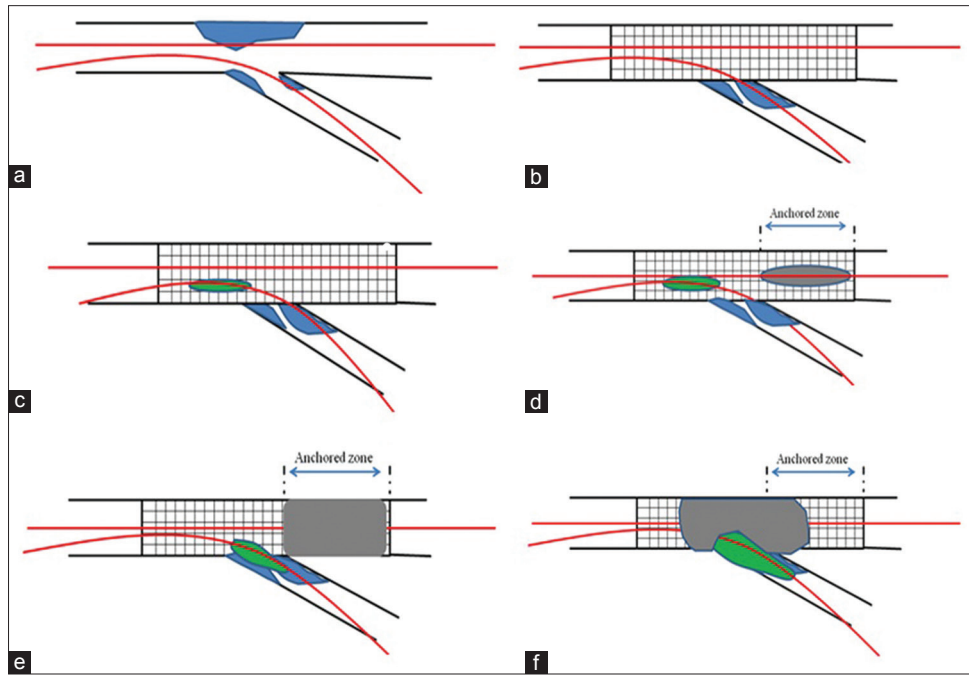
This study was supported by the clinical research grants from the Third Military Medical University (No. 2014YLC02).

Conflicts of interest

There are no conflicts of interest.

REFERENCES

1. Lassen JF, Holm NR, Stankovic G, Lefèvre T, Chieffo A, Hildick-Smith D, *et al.* Percutaneous coronary intervention for coronary bifurcation disease: Consensus from the first 10 years of the European Bifurcation Club meetings. *EuroIntervention* 2014;10:545-60. doi: 10.4244/EIJV10I5A97.
2. Sgueglia GA, Chevalier B. Kissing balloon inflation in percutaneous coronary interventions. *JACC Cardiovasc Interv* 2012;5:803-11. doi: 10.1016/j.jcin.2012.06.005.
3. Zhang D, Xu B, Yin D, Li YP, He Y, You SJ, *et al.* Clinical and angiographic predictors of major side branch occlusion after main vessel stenting in coronary bifurcation lesions. *Chin Med J* 2015;128:1471-8. doi: 10.4103/0366-6999.157654.
4. Ge L, Airoidi F, Iakovou I, Cosgrave J, Michev I, Sangiorgi GM, *et al.* Clinical and angiographic outcome after implantation of drug-eluting stents in bifurcation lesions with the crush stent technique: Importance of final kissing balloon post-dilation. *J Am Coll Cardiol* 2005;46:613-20. doi: 10.1016/j.jacc.2005.05.032.
5. Hildick-Smith D, de Belder AJ, Cooter N, Curzen NP, Clayton TC, Oldroyd KG, *et al.* Randomized trial of simple versus complex drug-eluting stenting for bifurcation lesions: The British Bifurcation Coronary Study: Old, new, and evolving strategies. *Circulation* 2010;121:1235-43. doi: 10.1161/CIRCULATIONAHA.109.888297.
6. Chue CD, Routledge HC, Ludman PF, Townend JN, Epstein AC, Buller NP, *et al.* 3-year follow-up of 100 consecutive coronary bifurcation lesions treated with Taxus stents and the crush technique. *Catheter Cardiovasc Interv* 2010;75:605-13. doi: 10.1002/ccd.22252.
7. Galassi AR, Tomasello SD, Capodanno D, Barrano G, Ussia GP, Tamburino C. Mini-crush versus T-provisional techniques in bifurcation lesions: Clinical and angiographic long-term outcome after implantation of drug-eluting stents. *JACC Cardiovasc Interv* 2009;2:185-94. doi: 10.1016/j.jcin.2008.12.005.
8. Zhao X, Song Y, Huang L. In-stent anchoring facilitates balloon delivery for final kissing. *J Invasive Cardiol* 2014;26:E66-9.
9. Medina A, Suárez de Lezo J, Pan M. A new classification of coronary bifurcation lesions. *Rev Esp Cardiol* 2006;59:183. doi: 10.1016/S1885-5857(06)60130-8.
10. Burzotta F, De Vita M, Sgueglia G, Todaro D, Trani C. How to solve difficult side branch access? *EuroIntervention* 2010;6:J72-80. doi: 10.4244/EIJV6SUPJA12.
11. Hildick-Smith D, Lassen JF, Albiero R, Lefèvre T, Darremont O, Pan M, *et al.* Consensus from the 5th European Bifurcation Club meeting. *EuroIntervention* 2010;6:34-8. doi: 10.4244/EIJV6I1A6.
12. Nishikawa H, Nakanishi S, Nishiyama S, Nishimura S, Seki A, Yamaguchi H. Primary coronary artery dissection observed at coronary angiography. *Am J Cardiol* 1988;61:645-8. doi: 10.1016/0002-9149(88)90782-5.
13. Fujita S, Tamai H, Kyo E, Kosuga K, Hata T, Okada M, *et al.* New technique for superior guiding catheter support during advancement of a balloon in coronary angioplasty: The anchor technique. *Catheter Cardiovasc Interv* 2003;59:482-8. doi: 10.1002/ccd.10551.
14. Aeby G, Surmely JF, Togni M, Cook S. A modified technique of balloon anchoring for tricky stent delivery. *EuroIntervention* 2013;8:1099-102. doi: 10.4244/EIJV8I9A168.
15. Di Mario C, Ramasami N. Techniques to enhance guide catheter support. *Catheter Cardiovasc Interv* 2008;72:505-12. doi: 10.1002/ccd.21670.
16. Routledge HC, Morice MC, Lefèvre T, Garot P, De Marco F, Vaquerizo B, *et al.* 2-year outcome of patients treated for bifurcation coronary disease with provisional side branch T-stenting using drug-eluting stents. *JACC Cardiovasc Interv* 2008;1:358-65. doi: 10.1016/j.jcin.2008.05.005.
17. Briguori C, Visconti G, Donahue M, Chiariello GA, Focaccio A. The glider balloon: A useful device for the treatment of bifurcation lesions. *Int J Cardiol* 2013;168:3208-11. doi: 10.1016/j.ijcard.2013.04.002.
18. Zheng XW, Zhao DH, Peng HY, Fan Q, Ma Q, Xu ZY, *et al.* Randomized comparison of the crush versus the culotte stenting for coronary artery bifurcation lesions. *Chin Med J* 2016;129:505-10. doi: 10.4103/0366-6999.176997.
19. Shan SJ, Ye F, Liu ZZ, Tian NL, Zhang JJ, Chen SL. Coronary bifurcation lesions treated with double kissing crush technique compared to classical crush technique: Serial intravascular ultrasound analysis. *Chin Med J* 2013;126:1247-51.



Supplementary Figure 1: A step-by-step description of the in-stent anchoring technique is as follows: (a) main vessel and side-branch lesions (blue area) are wired (red lines). (b) Main vessel stent implantation causes obvious stenosis in the ostium of the side branch. (c) Side-branch balloon (green area) cannot be advanced across the main vessel stent structure. (d) The anchoring balloon (gray area) is positioned in the “anchored zone” (between the ostium of the side-branch and the distal edge of the stent). (e) The in-stent balloon is inflated, and the side-branch balloon is advanced through the main vessel stent structures. (f) Kissing balloon is performed.