

Received: 2019.09.20

Accepted: 2019.12.13

Available online: 2020.01.24

Published: 2020.03.08

# Superficial Stab Wound to Zone I of the Neck Resulting in Thyrocervical Trunk Pseudoaneurysm Presented as Recurrent Hemothorax and Successfully Managed by Coil Embolization

## Authors' Contribution:

Study Design A  
Data Collection B  
Statistical Analysis C  
Data Interpretation D  
Manuscript Preparation E  
Literature Search F  
Funds Collection G

ABCDEFG 1 **Adel Elkbuli**  
BCDEF 1 **Saamia Shaikh**  
CDEF 1 **John D. Ehrhardt Jr.**  
BCDEFG 1,2 **Mark McKenney**  
ABCDEFG 1,2 **Dessy Boneva**

1 Department of Surgery, Kendall Regional Medical Center, Miami, FL, U.S.A.  
2 University of South Florida, Tampa, FL, U.S.A.

**Corresponding Author:** Adel Elkbuli, e-mail: [Adel.Elkbuli@hcahealthcare.com](mailto:Adel.Elkbuli@hcahealthcare.com)

**Conflict of interest:** None declared

**Patient:** Male, 27-year-old  
**Final Diagnosis:** Thyrocervical trunk pseudoaneurysm with recurrent hemothorax  
**Symptoms:** Diaphoresis • lethargy  
**Medication:** —  
**Clinical Procedure:** Coil embolization  
**Specialty:** Surgery

**Objective:** Rare disease  
**Background:** Thyrocervical trunk pseudoaneurysms are rare complications that have been documented after internal jugular or subclavian venous cannulation. Even less common, these pseudoaneurysms can arise after blunt or penetrating trauma. Clinical hallmarks include an expanding supraclavicular mass with local compressive symptoms such as paresthesias, arterial steal syndrome, and Horner's syndrome. Patients may be asymptomatic, however, or present with overlying ecchymosis or the presence of a new bruit or thrill. With the risk of rupture, thyrocervical trunk pseudoaneurysm is associated with significant morbidity and mortality.

**Case Report:** We report the case of a 27-year-old man who presented after sustaining a self-inflicted stab wound to zone I of his neck. Initial examination revealed only a superficial small laceration, but a chest x-ray revealed a pneumothorax, and tube thoracostomy returned 300 mL of bloody output. After resolution of the hemothorax and removal of the thoracostomy tube, the patient reaccumulated blood, requiring a repeat tube thoracostomy. Angiography at that time revealed a pseudoaneurysm of the thyrocervical trunk, and coil embolization was performed to obliterate the pseudoaneurysm.

**Conclusions:** Thyrocervical trunk pseudoaneurysms can be asymptomatic, often have a delayed presentation, and can be life-threatening due to the risk of rupture and subsequent hemodynamic decline or airway compromise. While these pseudoaneurysms are well-known complications of deep penetrating injuries, they can also present following superficial penetrating injury to zone I of the neck. Selective angiography is the imaging modality of choice. Open surgical repair was traditionally the criterion standard for treatment; however, endovascular approaches are minimally invasive, feasible, and safer alternatives with reduced complications and are becoming more common.

**MeSH Keywords:** Aneurysm, False • Embolization, Therapeutic • Hemothorax • Wounds, Penetrating

Full-text PDF: <https://www.amjcaserep.com/abstract/index/idArt/920196>



2102

—

8

34

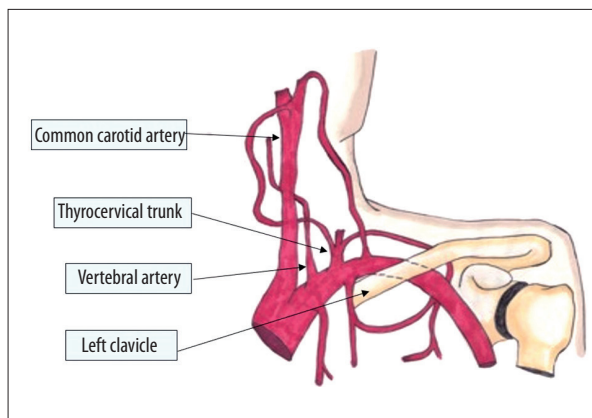
## Background

Thyrocervical trunk injury is rare owing to the relative anatomical protection afforded by its deep position in neck zone I [1]. Pseudoaneurysms of the thyrocervical trunk have most commonly been documented as complications of central venous access attempts directed at the internal jugular and subclavian veins. Blind approaches, multiple cannulation attempts, and inadvertent arterial puncture increase the likelihood of pseudoaneurysm formation [1,2]. Additional etiologies include trauma, infection, and fibromuscular hyperplasia [3]. These vascular anomalies typically present as a painless, pulsatile, supraclavicular mass but can also present as massive hemothorax, recurrent hemothorax, or hemoptysis [4–6]. As the aneurysm expands, neurovascular compression of neighboring structures can result in paresthesia (ansa cervicalis), arterial steal syndrome (subclavian artery), or Horner's syndrome (sympathetic trunk). Of note, these potentially life-threatening pseudoaneurysms often have a delayed presentation and may only become symptomatic after several months [6–8].


Located posterolateral to the internal jugular vein, the thyrocervical trunk is the second ascending branch of the subclavian artery and is responsible for blood supply to the neck [6]. It arises distal to the vertebral artery, which is the first ascending branch of the subclavian artery (Figure 1). Further, the thyrocervical trunk emanates from the superior edge of the subclavian artery and gives rise to 4 branches, while the vertebral artery originates from the posterior edge of the subclavian artery [6,9].

Neck injuries are commonly classified according to zones created by superficial anatomic boundaries that guide surgical management decisions [10–12]. Zone I injuries occur between the level of the clavicles and the cricoid cartilage and are associated with the highest mortality. It contains structures such as a portion of the common carotid artery, the subclavian artery, the vertebral artery, and the apex of the lung [13]. Zone I injuries are often the most difficult to assess on physical examination due to their proximity to the thoracic cavity and mediastinum. Zone II injuries occur between the cricoid cartilage and the mandibular angle, and zone III injuries encompass the retromandibular space between the angle of the mandible and the base of the skull [12,14]. The traditional management for active hemorrhage from a zone I injury necessitated a sternotomy, thoracotomy, or a claviclectomy for exposure [14].

Here, we report the case of a 27-year-old man who developed recurrent hemothorax secondary to a traumatic thyrocervical trunk pseudoaneurysm following a self-inflicted neck stabbing with an Indonesian karambit knife.



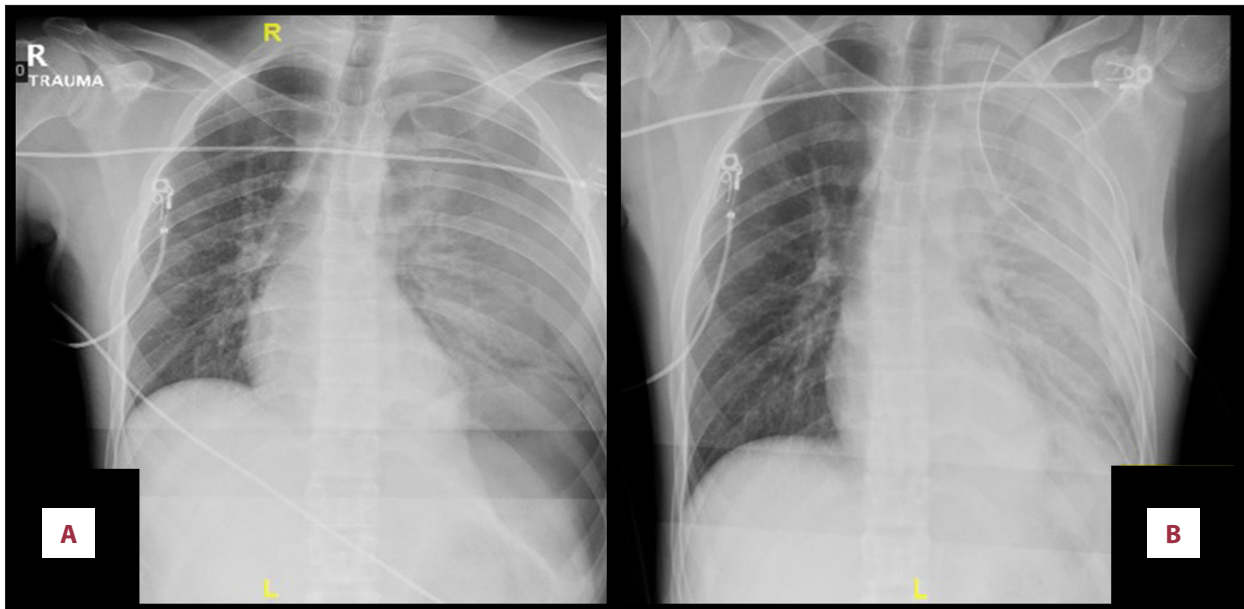
**Figure 1.** The thyrocervical trunk is the second ascending branch of the subclavian artery, arising distal to the vertebral artery.



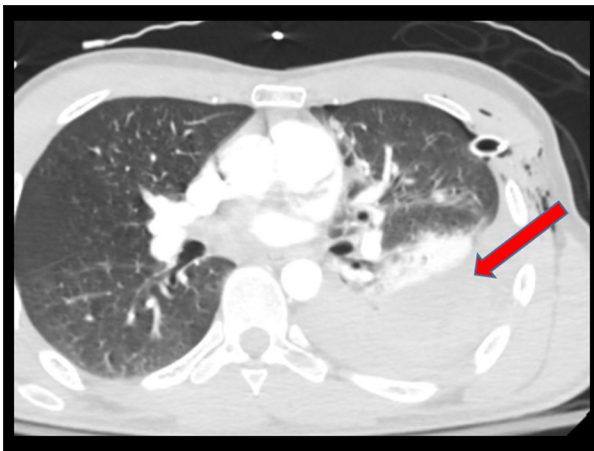
**Figure 2.** Karambit knife.

## Case Report

A 27-year-old man presented to our Trauma Center after sustaining a self-inflicted stab wound to his left lateral neck with a karambit knife (Figure 2). The left lower neck wound measured 2 mm and appeared negligible on examination. The injury was located in zone I of the neck. On arrival, the patient had a GCS of 15, with lethargy and diaphoresis. He primarily complained of nausea and an impending sense of doom. His airway was intact, but breath sounds were decreased in the left hemithorax. Oxygen saturation was 95% on room air and the patient's systolic blood pressure was 90 mmHg. The initial chest x-ray (CXR) in the trauma bay revealed a large left-sided pneumothorax measuring approximately 3.6 cm along the left lateral edge, with a hazy density characteristic of a large underlying hemothorax (left-sided hemopneumothorax) (Figure 3A). A left tube thoracostomy was performed in the trauma bay and yielded an immediate evacuation of 300 mL blood. Repeat CXR showed moderate re-expansion of the left hemopneumothorax, but persistent hemothorax (Figure 3B).



**Figure 3.** (A) Index trauma bay A-P CXR showing left-sided pneumothorax. (B) After tube thoracostomy, showing left lung “white-out” consistent with hemothorax.



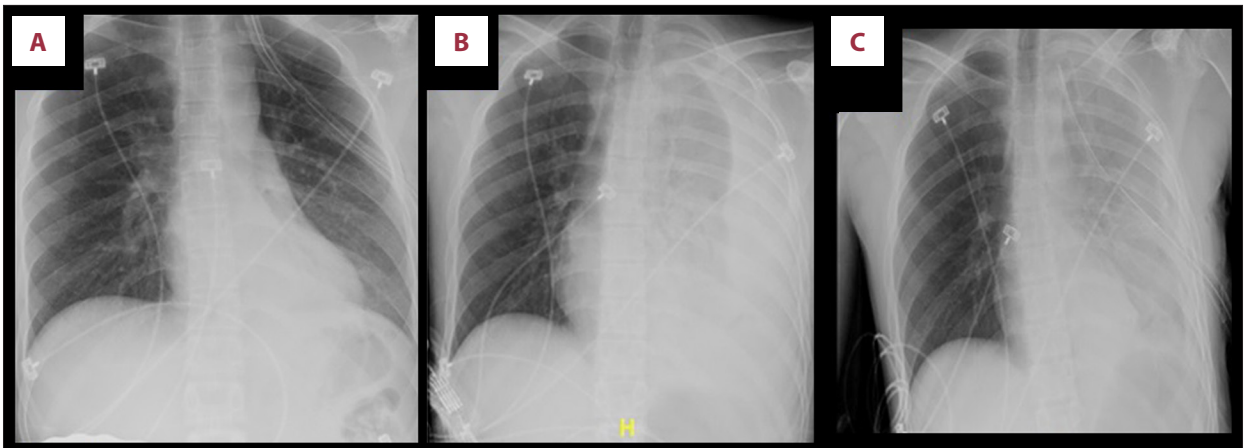
**Figure 4.** Initial CT chest and neck with contrast showing moderate left hemothorax without evidence of contrast extravasation.

In light of his hemodynamic stability, the patient was subsequently taken for imaging. Initial computed tomography (CT) of the chest and neck with contrast were performed and revealed the left hemopneumothorax with prominent compressive pulmonary atelectasis and chest tube in good position. The imaging also revealed patent and intact neck vessels (vertebral and carotid) with no evidence of contrast extravasation (Figure 4). The patient’s hemodynamic status and thoracostomy tube output was closely monitored in the ICU overnight. The chest tube evacuated another 900 mL of sanguineous drainage overnight, yet the patient remained hemodynamically stable.

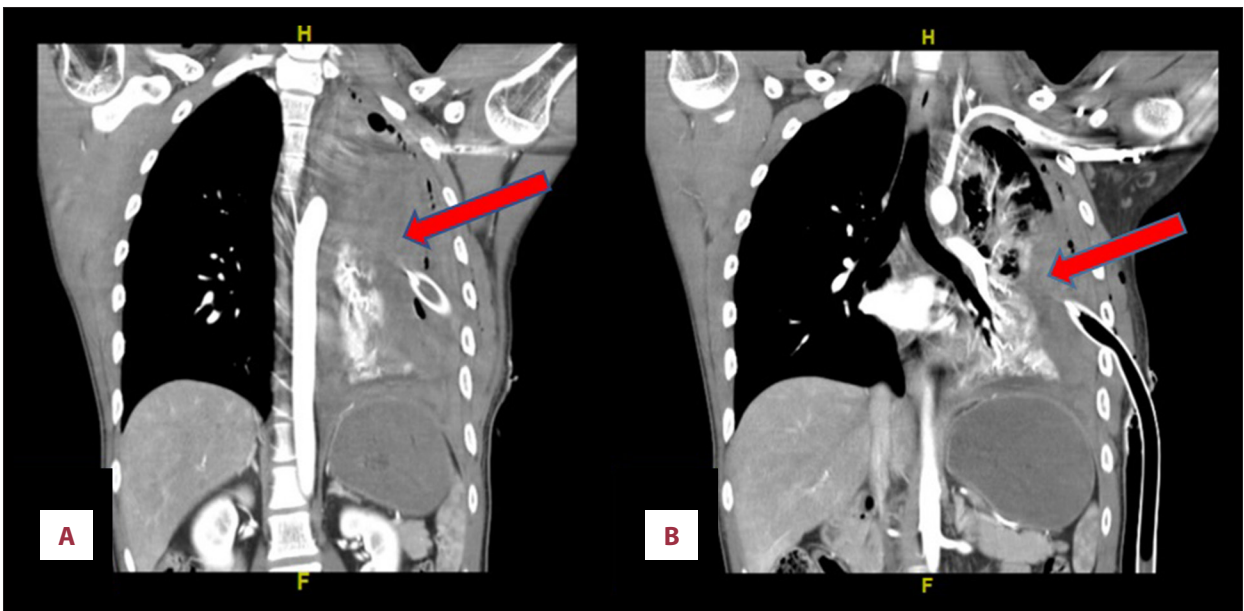
Conservative management ensued, with thoracostomy tube output decreasing until admission day 3, at which point the chest drainage system was placed on water seal. CXR at this time showed significant improvement of his hemopneumothorax (Figure 5A). The patient remained hemodynamically stable and no further left thoracostomy tube output was observed.

Thoracostomy tube removal on hospital day 4 was complicated by marked clinical deterioration soon thereafter. The patient became pale and diaphoretic, and post-removal CXR revealed complete opacification of the left lung field (Figure 5B). We immediately re-inserted a left thoracostomy tube (Figure 5C) and evacuated 900 mL of rich sanguineous output over several hours. Declining hemoglobin levels necessitated the transfusion of 2 units of pRBCs. Repeat CT chest with intravenous contrast demonstrated arterial injury with active contrast extravasation originating from the proximal left subclavian artery (Figure 6A, 6B) and left hemothorax.

A subsequent left subclavian-selective arteriogram demonstrated a pseudoaneurysm arising from a branch of the left thyrocervical trunk (Figure 7A). The vascular anomaly was embolized using 3-mm detachable micro-coils (Figure 7B). A post-procedure angiogram demonstrated hemorrhage resolution with complete occlusion of the vessel and pseudoaneurysm (Figure 7C). Consequently, the patient underwent a video-assisted thoracoscopic surgery (VATS) for removal of 1 L of retained hemothorax. A mechanical pleurodesis was also performed and 2 thoracostomy tubes were placed. Over the next several days the thoracostomy tube output decreased, and the tubes were placed on water seal and removed. Post-removal CXR



**Figure 5.** (A) Repeat CXR on hospital day 4. (B) CXR after chest tube removal on hospital day 4 demonstrating persistent opacification of left lung field. (C) CXR after tube thoracostomy placement after removal of chest tube due to “white-out” of the left chest due to bleeding.



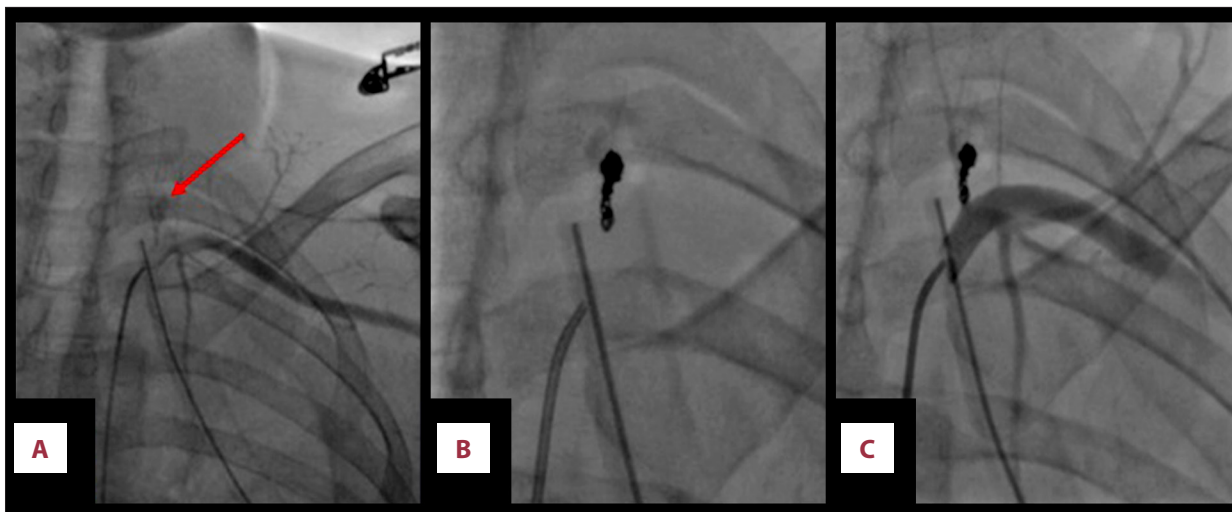
**Figure 6.** CT chest with IV contrast, coronal view: (A) Evidence of arterial injury with active extravasation of contrast originating from the thyrocervical branch of the proximal left subclavian artery; a small pseudoaneurysm is seen at the thyrocervical branch. (B) A large amount of blood is seen in the left chest as a result of bleeding from the injury site of the thyrocervical trunk pseudoaneurysm; a thoracostomy tube is also in place in the left chest.

showed complete resolution of the hemothorax (Figure 8). Shortly thereafter, the patient was discharged home and had a full recovery. The patient was significantly improved on follow-up visit at the trauma clinic 2 weeks later.

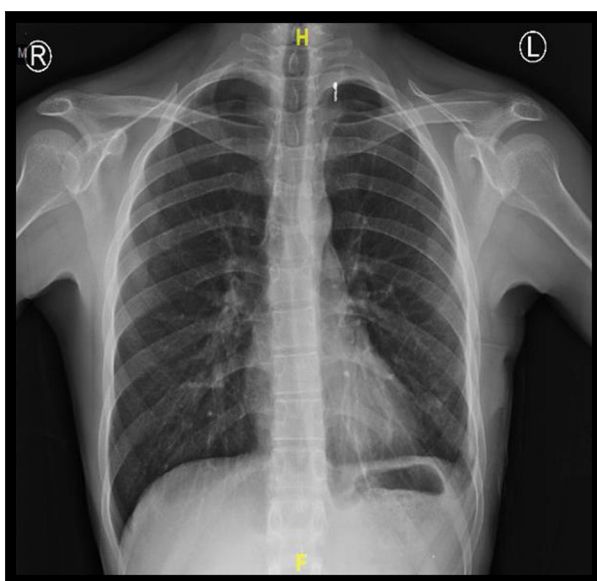
## Discussion

Thyrocervical trunk pseudoaneurysm is a rare entity occurring in previous reports as a complication of central venous catheterization [1,15–23]. The pathogenesis usually involves arterial

intimal injury creating discontinuity in the arterial wall, thereby allowing blood into the false arterial lumen, giving rise to pseudoaneurysm formation [24–26]. Rupture of a pseudoaneurysm can result in formation of a hematoma and can cause hemodynamic decline or airway compromise and can potentially be fatal [27,28]. Abrokwah et al. reported the case of a patient in which cannulation of the subclavian vein was attempted for cardiac pacing; however, the procedure was ultimately abandoned due to bleeding from the puncture site. The following day, the patient developed Horner’s syndrome and a pulsatile mass at the site of the injury. Digital subtraction



**Figure 7.** (A) Angiogram showing left subclavian artery and thyrocervical trunk branch of the proximal subclavian artery. Left subclavian-selective arteriogram demonstrates a pseudoaneurysm arising from a branch of the left thyrocervical trunk with contrast extravasation (arrow). (B) Selective catheterization of left thyrocervical trunk, angiogram, and coil embolization. The abnormal vessel/pseudoaneurysm was embolized using three 3-mm detachable micro-coils. (C) Successful coil embolization of left thyrocervical trunk branch. Post-procedure angiogram demonstrates complete occlusion of the abnormal artery with exclusion of the pseudoaneurysm. No active contrast extravasation.



**Figure 8.** Normal CXR on the day of discharge.

angiography confirmed the presence of a 2-mm pseudoaneurysm. Upon surgical repair, the authors reported evacuating the pseudoaneurysm contents and repairing the defect [16]. This technique has been referred to as the “smash-and-grab technique” [2]. The Horner’s syndrome and pulsatile mass resolved postoperatively for their patient using this approach [17]. Another case report, by Dwivedi et al., described a patient requiring a pacemaker who underwent multiple attempts at right internal jugular and subclavian venous cannulation, ultimately resulting in thyrocervical pseudoaneurysm formation.

Manifesting symptoms in this case included a supraclavicular mass, overlying ecchymosis, a new bruit, and tingling of the upper extremity [1]. Ezhilnilavan and colleagues reported a case in which they attempted blind cannulation of the internal jugular vein. They aborted the procedure after inadvertent arterial puncture. Immediately following the procedure, the patient complained of dysphagia, and CTA neck and chest revealed the pseudoaneurysm [32].

Traumatic thyrocervical trunk pseudoaneurysms are usually the result of deep penetrating trauma. Nonetheless, a handful of cases have been documented in the setting of blunt trauma [5,15,24,29]. In 1998, Houshian and Poulsen reported the first case of pseudoaneurysm formation after blunt-force cervical trauma. The patient was a young man who presented with Horner’s syndrome, facial palsy, arterial steal syndrome, and torticollis months after being hit with iron shrapnel. Angiography confirmed pseudoaneurysm of the thyrocervical trunk [24]. Similar to the present case, Majeski reported the case of a patient with a superficial stab wound in zone 1 of the neck from a pocketknife. During the patient’s initial encounter in the ED, the stab wound was irrigated and the patient was sent home with a prescription for antibiotics. Two months later, however, the patient required surgical repair of a thyrocervical trunk pseudoaneurysm [7]. Interestingly, in both the present case and the aforementioned case, the patients sustained superficial knife injuries in zone I of the neck that were largely unremarkable on presentation but ultimately resulted in the need for operative intervention for the treatment of thyrocervical trunk pseudoaneurysms.

There have also been spontaneous thyrocervical pseudoaneurysms reported in the literature. For example, an 8-year-old boy presented with a painless expanding pulsatile supraclavicular mass in the absence of any bodily trauma [3]. In another case, a 60-year-old woman presented with altered mental status, unsteady gait, speech difficulty, Horner's syndrome, and a 2-cm neck mass. Although still suspected, the patient did not report any falls or other sources of trauma in that case [30]. Junior et al. described a case of a patient with Harlequin syndrome who was found to have thyrocervical trunk pseudoaneurysm as well as a systemic-pulmonary arterio-arterial fistula [27]. Additionally, 2 cases of thyrocervical trunk and thyrocervical trunk branch pseudoaneurysms have been associated with clavicular fracture [25,31]. The first involved thyrocervical trunk pseudoaneurysm as a complication of plate-fixation of a mid-shaft clavicular fracture [31]. In the second case, a thyrocervical trunk branch pseudoaneurysm resulted during a motor vehicle collision, which caused trauma to the shoulder and fracture of the clavicle [25].

Pseudoaneurysms can be diagnosed using noninvasive modalities such as CTA, magnetic resonance angiography (MRA), or Doppler ultrasound (DUS). Using DUS, the presence of a pseudoaneurysm is confirmed by a "to and from" waveform [32]. Conventional angiography, although invasive, provides a more complete spatial picture of the size and location of the defect and remains the criterion standard for diagnosis [1,15]. Additionally, selective angiography provides essential information regarding the formation of possible collateral vasculature that must be obtained prior to endovascular intervention [6]. With DUS, the presence of a pseudoaneurysm is confirmed by a "to and from" waveform [32].

Complications of thyrocervical trunk pseudoaneurysms include thrombosis, local neurovascular compression, rupture, hemorrhage, hematoma formation secondary to rupture, and airway compromise due to hematoma formation [15,27,30,32]. Early detection of pseudoaneurysms can minimize morbidity and even prevent death [25].

Historically, surgical repair was considered to be the standard treatment approach. Proximal and distal control of the vessel was obtained, accumulated blood products were drained, the aneurysm wall was excised, and the vessel wall defect was repaired [33]. In recent years, endovascular approaches have become more common [34]. For partial defects, covered stent grafts may be utilized [1]. As in the present case, coil embolization is another endovascular approach that can be used [1,33]. Endovascular occlusion with micro-coils is a minimally invasive approach and is appropriate even in high-risk patients [21]. Endovascular approaches are associated with reduced complication rates and an overall decreased morbidity.

Ultrasound-guided compression, ultrasound-guided thrombin injections, and liquid embolization with polymerizing agents are also therapeutic options for select patients [6,25–27].

We reported the case of a patient who presented after a self-inflicted stab wound with traumatic thyrocervical trunk pseudoaneurysm, which was discovered after recurrent hemothorax, requiring endovascular coiling, VATS, and mechanical pleurodesis. To the best of our knowledge, there has only been 1 other case reported in the literature which occurred after an unremarkable superficial stab wound to zone I of the neck and later resulted in thyrocervical trunk pseudoaneurysm [7], and there have only been 2 cases previously reported in the literature that resulted in hemothorax following thyrocervical trunk pseudoaneurysm [4,5]. The present case is the first case in the literature in which a thyrocervical trunk pseudoaneurysm necessitated coil embolization, VATS, and mechanical pleurodesis. Thyrocervical trunk pseudoaneurysm is associated with significant mortality but can be easily managed via endovascular techniques if detected in time. We hope this case report raises awareness of this uncommon yet deadly complication.

## Conclusions

Pseudoaneurysm of the thyrocervical trunk is an exceedingly rare complication of trauma of the neck and can be life-threatening. Most cases are iatrogenic and result from attempted cannulation of the internal jugular or subclavian veins for central venous access. The majority of cases present with a pulsatile supraclavicular mass or symptoms of neurovascular compromise; however, as in the present case, recurrent hemothorax may be the presenting symptom. Further, given the favorable outcomes using endovascular approaches coupled with the fact that thyrocervical trunk pseudoaneurysms can be asymptomatic and potentially fatal, imaging for all penetrating traumas to zone I neck of the neck – deep and superficial – should be performed to minimize morbidity and mortality.

## Acknowledgement

Artwork by Katie McKenney.

## Department and Institution where work was done

Department of Surgery, Kendall Regional Medical Center, Miami, FL, U.S.A.

## Conflicts of interests

None.

## References:

1. Dwivedi AJ, Cherukupalli C, Dayal R et al: Endovascular treatment of false aneurysm of the thyrocervical trunk. *Vasc Endovasc Surg*, 2007; 41: 77–79
2. Chalmers RTA: Correspondence: False aneurysm of the thyrocervical trunk. *Eur J Vasc Endovasc Surg*, 1997; 13: 424–25
3. Al-Homoud S, Al-Garni S, Khougeer G: Thyrocervical trunk pseudoaneurysm. *Ann Saudi Med*, 1998; 18: 239–41
4. Seamon MJ, Choudry R, Santora T et al: Thyrocervical trunk transection: A rare cause of massive hemothorax. *J Trauma*, 2005; 62: 1534
5. Tanizaki S, Hayashi H: Massive hemothorax after blunt transverse cervical artery injury. *J Emerg Med*, 2012; 43(6): e397–99
6. Perez-Garcia C, Malfaz C, Dieguez MDV et al: Embolization through the thyrocervical trunk: Vascular anatomy, variants, and a case series. *J Neurointervent Surg*, 2018; 10: 1012–18
7. Majeski J: Traumatic pseudoaneurysm of the thyrocervical trunk. *South Med J*, 2001; 94(4): 380–82
8. Mammen S, Koshy GC, Khurana A, David V: Endovascular repair of iatrogenic subclavian artery pseudo-aneurysm. *Saudi J Kidney Dis Transpl*, 2015; 26(5): 1023–25
9. Kayashima K, Yamasaki R: Ultrasonographic identification of the thyrocervical trunk and vertebral artery in adults to decrease complications. *Turk J Anesthesiol Reanim*, 2016; 44: 275
10. Monson DO, Saletta JD, Freeark RJ: Carotid vertebral trauma. *J Trauma*, 1969; 9: 987
11. Roon AJ, Christensen N: Evaluation and treatment of penetrating cervical injuries. *J Trauma*, 1979; 19: 391
12. Sperry JL, Moore EE, Coimbra R et al: Western Trauma Association critical decisions in trauma: Penetrating neck trauma. *J Trauma Acute Care Surg*, 2013; 75: 936–40
13. Alao T, Waseem M: Neck trauma. *StatPearls*. Treasure Island (FL): StatPearls Publishing, 2019
14. Mattox KL, Moore EE, Feliciano DV: 7<sup>th</sup> ed. *Trauma*. New York: The McGraw-Hill Companies, 2013
15. Mehta K, England E, Appar J et al: Post-traumatic pseudoaneurysm of the thyrocervical trunk. *Skeletal Radiol*, 2013; 42: 1169–72
16. Abrokwah J, Shenoy KN, Armour RH: False aneurysm of the thyrocervical trunk: An unconventional surgical approach. *Eur J Vasc Endovasc Surg*, 1996; 11: 373–74
17. Salviz EA, Tetik A, Demirdogen V et al: A rare complication of internal jugular vein cannulation: pseudoaneurysm of the thyrocervical trunk. *GKDA Derg*, 2015; 21: 116–20
18. Ruan J, Zhang C, Peng Z et al: Inferior thyroid pseudoaneurysm associated with internal jugular vein puncture: A case report. *BMC Anesthesiology*, 2015; 15: 71
19. Alpay E, Guner A, Havan N et al: Pseudoaneurysm of the thyrocervical trunk after coronary intervention from the right radial approach. *Coron Artery Dis*, 2017; 28: 443–44
20. Cuhaci B, Khoury P, Chvala R: Transverse cervical artery pseudoaneurysm: A rare complication of internal jugular cannulation. *Am J Nephrol*, 2000; 20(6): 476–82
21. Palermo C, Sanfiorenzo A, Giaquinta AT et al: Mini-invasive treatment of a large pseudoaneurysm of the neck related to central venous catheter placement: A case report. *Medicine*, 2018; 97: e11262
22. Elariny HA, Crockett D, Hussey JL: False aneurysm of the thyrocervical trunk. *South Med J*, 1996; 89(5): 519–21
23. Peces R, Navascues RA, Baltar J et al: Pseudoaneurysm of the thyrocervical trunk complicating percutaneous internal jugular-vein catheterization for haemodialysis. *Nephrol Dial Transplant*, 1998; 13: 1009–11
24. Houshian S, Poulsen TD: Aneurysm of the thyrocervical trunk after blunt cervical injury. *Injury*, 1998; 29: 77–78
25. Prater S, Marichal DA, Rees C: Endovascular management of suprascapular artery pseudoaneurysm. *Proc (Bayl Univ Med Cent)*, 2010; 23(1): 24–26
26. Saad NEA, Saad WEA, Davies MG et al: Pseudoaneurysms and the role of minimally invasive techniques in their management. *Radiographics*, 2005; 25: S173–89
27. Junior AMOG, Junior AK, Paschoal EHA, Jeha SAH: Three extremely rare findings in the same patient: Harlequin syndrome, thyrocervical trunk aneurysm, and systemic-pulmonary arterio-arterial fistula. *Ann Vasc Surg*, 2017; 45: 267.e7–e12
28. Garrett HE, Heidepriem RW, Broadbent LP: Ruptured aneurysm of the inferior thyroid artery: Repair with coil embolization. *J Vasc Surg*, 2005; 42(6): 1226–29
29. Akpınar E, Cil BE: Endovascular treatment of thyrocervical trunk pseudoaneurysm with covered stent implantation. *Eurorad*, 2009; Case 2876
30. Al-Jundi W, Matheiken S, Abdel-Rehim S et al: Ruptured thyrocervical trunk aneurysm in a patient with type I neurofibromatosis. *EJVES Extra*, 2011; 21: e10–12
31. Rossi LA, Atala N, Barros H et al: Pseudoaneurysm of the thyrocervical trunk of the subclavian artery after osteosynthesis of a mid-shaft clavicular fracture. *Clin Surg*, 2019; 4: 2373
32. Ezhilnilavan S, Priyamvada PS, Swamiappan E et al: Pseudoaneurysm of thyrocervical trunk following left internal jugular vein cannulation. *Indian J Nephrol*, 2018; 28: 173–74
33. Mur TA, Anis MM, Soliman AMS: Thyrocervical trunk pseudoaneurysm presenting as a neck mass. *Ear Nose Throat J*, 2017; 96: 238–39
34. Hamamoto K, Nakano M, Omoto K et al: Successful endovascular treatment of iatrogenic thyrocervical trunk pseudoaneurysm with concomitant arteriovenous fistula using 0.010-inch detachable microcoils. *Case Rep Vasc Med*, 2014; 2014: 479656