



OPEN ACCESS

Empyema associated with a cough-induced rib fracture

Satoshi Hayano , Masayuki Kashima

Department of Internal Medicine, Japanese Red Cross Kumamoto Hospital, Kumamoto, Japan

Correspondence to
Dr Satoshi Hayano;
059m2076@gmail.com

Accepted 22 April 2021

SUMMARY

A 44-year-old man presented to the emergency department with fever and right anterior chest pain. He reported a persistent cough and the development of sudden-onset right anterior chest pain after coughing. The inspiratory pain in the right lung was severe, and therefore deep breathing was impossible. Chest CT revealed a fracture in the right seventh rib with consolidation and pleural effusion. A pleural fluid culture test result was positive for methicillin-susceptible *Staphylococcus aureus*. He was diagnosed with empyema associated with a cough-induced rib fracture. Thoracic drainage tube placement and intravenous antibiotic therapy successfully ameliorated his condition. He was discharged on day 13 and switched to an 8-week course of oral antibiotic therapy. There was no clinical relapse at the 6-month follow-up.

BACKGROUND

Cough-induced rib fracture is a type of stress fracture.^{1–4} Typically, postinfectious cough, chronic bronchitis, asthma attack and postnasal drip are associated with cough-induced rib fractures; furthermore, the fracture is followed by a sudden onset of chest pain after the cough.¹³ Rib fractures are more likely to occur in the lateral aspect of the 5th–10th ribs because of their known susceptibility to shear forces.¹⁵ Approximately 30% of patients with a cough-induced rib fracture have no underlying disease or osteoporosis, meaning it can occur in patients with no specific risk factors and in healthy adults.^{1–4}

Rib fractures are considered a risk factor for both pneumonia and empyema.^{6–9} In particular, multiple rib fractures due to trauma can worsen the drainage of sputum from cough owing to pain and flail chest syndrome and increase the risk of subsequent pneumonia. The prevalence of pneumonia after rib fractures is estimated to be 6%–9.1%, and this also increases mortality, especially in those aged >65 years.^{7 10} The rate of complications depends on the number and severity of rib fractures, with more fractures resulting in more severe complications and pneumonia.^{8 11} In 50% of cough-induced rib fractures, a single rib fracture is involved.¹⁴ Although the prognosis for cough-induced rib fracture is good generally, complications, such as pneumonia, haemothorax, pneumothorax, pneumomediastinum, subcutaneous emphysema, chest wall haematoma and intercostal pulmonary herniation, have also been reported.^{1 12 13} Most post-traumatic empyema cases are related to contusion trauma and to chest tube insertion, with a reported incidence of

approximately 3.1%.⁹ Empyema has not previously been reported to be associated with cough-induced rib fractures, and its epidemiology is unknown. Here, we present a novel case of empyema associated with a cough-induced rib fracture.

CASE PRESENTATION

A 44-year-old man with a history of asthma presented to the emergency department (ED) with fever and right anterior chest pain. Two weeks before presentation, he had had a persistent cough with an asthma attack after an upper respiratory tract infection. One week later, he developed sudden-onset right anterior chest pain after coughing. He reported no history of trauma, and an orthopaedic surgeon diagnosed him with a fracture of the right seventh rib. He had not been taking any oral medications. He was previously diagnosed with contact dermatitis and had been receiving monthly injections of intramuscular triamcinolone acetonide for the previous 10 years. He drank one beer daily and had smoked half a pack of cigarettes per day for >20 years. On presentation, his body temperature was 37.5°C, blood pressure was 131/95 mm Hg, heart rate was 80 beats per minute, respiratory rate was 18 breaths per minute and SpO₂ (arterial oxygen saturation of pulse oxymetry) level was 98% (ambient air). Physical examination revealed right anterior chest pain at the level of the seventh rib. The respiratory sounds on auscultation were unremarkable.

INVESTIGATIONS

A chest X-ray (figure 1) revealed a fracture of the seventh rib, and chest CT showed consolidation and a small amount of pleural effusion (figure 2). A rib fracture with haemothorax and pneumonia was initially suspected. The patient was initiated on oral amoxicillin/clavulanate. Two days after his initial visit, he was rushed to the ED with worsening right chest pain and shortness of breath. The

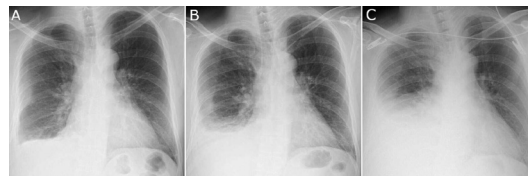
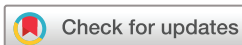

Figure 1 Anteroposterior chest radiograph of our patient. (A) Blunt, right costophrenic angle with a seventh rib fracture at presentation. Increased pleural effusion was observed 12 hours after admission (B) and on day 2 (C).



© BMJ Publishing Group Limited 2021. Re-use permitted under CC BY-NC. No commercial re-use. See rights and permissions. Published by BMJ.

To cite: Hayano S, Kashima M. *BMJ Case Rep* 2021;**14**:e242656. doi:10.1136/bcr-2021-242656

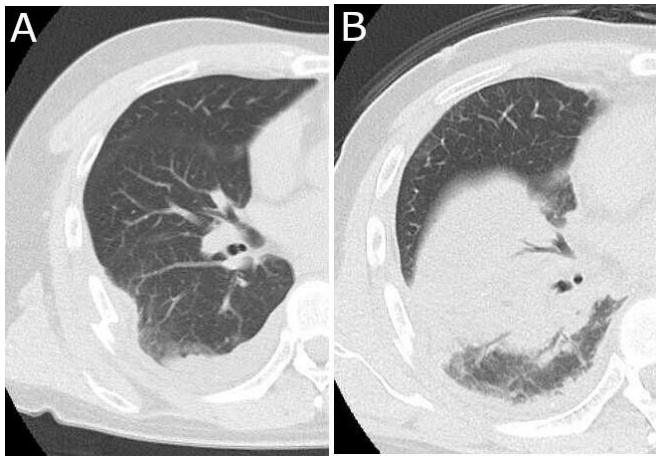


Figure 2 Chest CT of our patient at presentation. A fracture of the right seventh rib was observed (A) with right lower lung consolidation and pleural effusion on day 2 (B).

inspiratory pain in the right lung had markedly worsened, and deep breathing had become impossible. On arrival at the ED, his body temperature was 38.5°C, blood pressure was 131/95 mm Hg, heart rate was 107 beats per minute, respiratory rate was 30 breaths per minute and SpO₂ level was 98% (O₂, 6L/min). The laboratory test results were as follows: leucocyte count, 10.18 ×10⁹/L; haemoglobin level, 137g/L; platelet count, 211 ×10⁹/L; serum creatinine level, 0.96 mg/dL; lactate dehydrogenase level, 227U/L; total protein level, 6.5 g/dL; serum albumin level, 3.2 mg/dL; blood glucose level, 197 mg/dL; and C reactive protein level, 17.83 mg/dL. The chest X-ray showed an increased level of pleural effusion. Thus, thoracentesis was performed, revealing an exudative neutrophilic pleural effusion with the following: total protein level of 5.8 g/dL, glucose level of 138 mg/dL and lactate dehydrogenase level of 779 U/L. Gram staining of the pleural fluid showed gram-positive cocci. Pleural fluid culture results revealed methicillin-susceptible *Staphylococcus aureus* (MSSA). Two sets of blood cultures were negative.

TREATMENT

Empirical treatment was initiated with ampicillin/sulbactam and vancomycin after admission. However, once the results of antibiotic sensitivity tests were available, the antibiotics were switched to cefazolin. A right thoracic drainage tube was inserted on admission, draining 520 mL of pleural fluid over 1 hour. The patient's respiratory distress and right inspiratory chest pain were intense, but the symptoms gradually improved after drainage. On day 3, the fever abated, and he could take deep breaths; thereafter, the thoracic drainage tube was removed. After 13 days of intravenous antimicrobial treatment, the patient was discharged and switched to an oral antibiotic to continue outpatient treatment with an 8-week course of cephalexin.

OUTCOME AND FOLLOW-UP

Two months after discharge from our hospital, chest CT revealed that the pleural effusion had markedly improved. The patient completed the 8-week course of cephalexin therapy, and no relapse was noted at the 6-month follow-up. The rib fracture was treated conservatively, and posterior follow-up CT showed bone fusion had occurred. Bone densitometry revealed osteopenia: the T-score of the lumbar spine was -1.6 and that of the total hip was -2.0.

DISCUSSION

Cough-induced rib fracture can occur in healthy young people and it is also occurs in patients with osteopenia and osteoporosis.^{1 2} It has been reported by Hanak *et al* that 17 of their 26 patients with a cough-induced rib fracture met the criteria for either osteopenia or osteoporosis.¹ Prins *et al* reported that patients with osteopenia or osteoporosis had a higher risk of rib fracture than patients with normal bone density on blunt thoracic trauma.¹⁴ In our case, no oral steroids or immunosuppressive drugs were used, but a detailed medical history revealed that the patient had received regular intramuscular injections of triamcinolone acetonide for over 10 years. Any association between cough-induced rib fractures and steroid-induced bone loss is unclear.^{1 4} Our patient was at a high risk of fracture and pneumonia due to both his steroid use and his prolonged smoking habit.

Chauny *et al* reported that generally the time between a rib fracture and the onset of pneumonia is between 2 and 14 days; furthermore, the onset of pneumonia can also occur soon after rib fracture, during the acute phase of the disease.¹⁵ In our case, the patient developed pneumonia on the third day after the fracture occurred, which, considering the above, was a relatively early onset. Among the complications arising from rib fractures, pneumonia is the leading cause of death in trauma patients and is particularly problematic in those aged >65 years.⁷ Brasel *et al* reported that the development of pneumonia after a rib fracture was a risk factor for death (OR, 3.5; 95% CI, 2.2 to 5.7). Risk factors for pneumonia after rib fracture include the following: male sex; age >65 years; >6 rib fractures; brain injury; spinal cord injury; underlying disease, such as congestive heart failure; paralysis; chronic pulmonary disease; obesity; weight loss; alcohol consumption; and high initial fluid volume.^{8 10 11} Although increasing age and number of fractures have been reported to increase complications, those aged <45 years at risk of multiple rib fractures have been reported to have adverse outcomes.^{11 16} Thus, complications after rib fractures should be monitored in at-risk patients of all ages.

The incidence of pneumonia in minor rib fractures is as low as 0.6%–1.6%.^{7 17} However, Ho *et al* reported that even one or two rib fractures were associated with an increased risk of pneumonia (adjusted HR, 8.94; 95% CI, 3.79 to 21.09; p<0.001).¹⁷ Risk factors for pneumonia complications in minor fractures include age >65 years and chronic obstructive pulmonary disease, but the likelihood of pneumonia secondary to a minor rib fracture in healthy adults is low.¹⁷

To the best of our knowledge, this is the first report of empyema due to MSSA associated with a cough-induced rib fracture. Post-traumatic empyema has been previously reported as a complication, secondary to thoracic trauma, and mainly occurs after penetrating trauma with an inserted chest tube, but it has also been reported in combination with blunt trauma complicated by rib fracture.^{9 18 19} Previous studies have reported that haemothorax, prolonged tube placement, ≥2 rib fractures and contusion are risk factors for empyema.⁹ Regarding the microbiological aetiology of post-traumatic empyema, pleural fluid culture was reported to be positive in 73% of cases.²⁰ *S. aureus* is the most common bacterial pathogen, and MSSA accounts for 35.1% of cases.²⁰ Causative bacteria include methicillin-resistant *S. aureus*, *Streptococcus pneumoniae*, *Pseudomonas aeruginosa*, *Klebsiella pneumoniae* and anaerobic organisms.^{18–20} It has been reported that bacteria detectable in sputum and pleural fluid cultures in post-traumatic empyema do not always correlate.

Contamination at the time of injury, or tube insertion, has been shown as the cause of empyema due to penetrating trauma.²⁰

Although there was no perforating trauma in our case, we conjecture the mechanism to be that the patient's severe chest pain made it difficult to expel sputum and that steroid use and smoking were involved in the progression to empyema. As the patient was unable to expel sputum due to pain, sputum examination could not be performed. Contamination from an external surface was unlikely, and the patient may have progressed from pneumonia to empyema. The treatment of parapneumonic empyema requires drainage, and in our case, the initial medical treatment alone did not improve the patient's condition, necessitating the insertion of a drain, which resulted in a marked improvement. Possible complications of pneumonia and empyema after a cough-induced rib fracture should be considered, even if the patient has a small number of fractures.

Learning points

- ▶ Cough-induced rib fracture is a stress fracture that occurs after persistent cough, followed by a sudden onset of chest pain.
- ▶ Pneumonia is an important complication of the acute phase of rib fracture and can even occur after a minor rib fracture, particularly in older adults and smokers.
- ▶ In cases of empyema complicated with a rib fracture, it is crucial to differentiate empyema from simple haemothorax.
- ▶ *Staphylococcus aureus* is the most common bacterial pathogen of rib fracture-associated empyema.

Contributors SH was involved in conceptualisation, writing and original draft preparation; MK was involved in writing, reviewing and editing, and supervising.

Funding The authors have not declared a specific grant for this research from any funding agency in the public, commercial or not-for-profit sectors.

Competing interests None declared.

Patient consent for publication Obtained.

Provenance and peer review Not commissioned; externally peer reviewed.

Open access This is an open access article distributed in accordance with the Creative Commons Attribution Non Commercial (CC BY-NC 4.0) license, which permits others to distribute, remix, adapt, build upon this work non-commercially, and license their derivative works on different terms, provided the original work

is properly cited and the use is non-commercial. See: <http://creativecommons.org/licenses/by-nc/4.0/>.

ORCID iD

Satoshi Hayano <http://orcid.org/0000-0003-3554-1600>

REFERENCES

- 1 Hanak V, Hartman TE, Ryu JH. Cough-Induced rib fractures. *Mayo Clin Proc* 2005;80:879–82.
- 2 Yeh C-F, Su S-C. Cough-Induced rib fracture in a young healthy man. *J Formos Med Assoc* 2012;111:179–80.
- 3 De Maeseneer M, De Mey J, Debaere C, et al. Rib fractures induced by coughing: an unusual cause of acute chest pain. *Am J Emerg Med* 2000;18:194–7.
- 4 Sano A, Tashiro K, Fukuda T. Cough-Induced rib fractures. *Asian Cardiovasc Thorac Ann* 2015;23:958–60.
- 5 Karlson KA. Rib stress fractures in elite Rowers. *Am J Sports Med* 1998;26:516–9.
- 6 Martin TJ, Eltorai AS, Dunn R, et al. Clinical management of rib fractures and methods for prevention of pulmonary complications: a review. *Injury* 2019;50:1159–65.
- 7 Brasel KJ, Guse CE, Layde P, et al. Rib fractures: relationship with pneumonia and mortality. *Crit Care Med* 2006;34:1642–6.
- 8 Marco CA, Sorensen D, Hardman C, et al. Risk factors for pneumonia following rib fractures. *Am J Emerg Med* 2020;38:610–2.
- 9 Eren S, Esme H, Sehitogullari A, et al. The risk factors and management of posttraumatic empyema in trauma patients. *Injury* 2008;39:44–9.
- 10 Mangram AJ, Sohn J, Zhou N, et al. Trauma-associated pneumonia: time to redefine ventilator-associated pneumonia in trauma patients. *Am J Surg* 2015;210:1056–62. Discussion 61–2.
- 11 Bulger EM, Arneson MA, Mock CN, et al. Rib fractures in the elderly. *J Trauma* 2000;48:1040–7.
- 12 Camarillo-Reyes LA, Marquez-Córdova RI, Surani S, et al. Hemothorax induced by severe cough: an unusual presentation. *SAGE Open Med Case Rep* 2019;7:2050313X1984604.
- 13 Shukri WNA, Ng VH, Ismail AK. A case of cough induced rib fracture with subcutaneous emphysema and pneumothorax. *Med J Malaysia* 2019;74:551–2.
- 14 Prins JTH, Van Lieshout EMM, Reijnders MRL, et al. Rib fractures after blunt thoracic trauma in patients with normal versus diminished bone mineral density: a retrospective cohort study. *Osteoporos Int* 2020;31:225–31.
- 15 Chauny J-M, Émond M, Plourde M, et al. Patients with rib fractures do not develop delayed pneumonia: a prospective, multicenter cohort study of minor thoracic injury. *Ann Emerg Med* 2012;60:726–31.
- 16 Testerman GM. Adverse outcomes in younger rib fracture patients. *South Med J* 2006;99:335–9.
- 17 Ho S-W, Teng Y-H, Yang S-F, et al. Risk of pneumonia in patients with isolated minor rib fractures: a nationwide cohort study. *BMJ Open* 2017;7:e013029.
- 18 Villalba M, Lucas CE, Ledgerwood AM, et al. The etiology of post-traumatic empyema and the role of decortication. *J Trauma* 1979;19:414–21.
- 19 Hoth JJ, Burch PT, Richardson JD. Posttraumatic empyema. *European Journal of Trauma* 2002;28:323–32.
- 20 Hoth JJ, Burch PT, Bullock TK, et al. Pathogenesis of posttraumatic empyema: the impact of pneumonia on pleural space infections. *Surg Infect* 2003;4:29–35.

Copyright 2021 BMJ Publishing Group. All rights reserved. For permission to reuse any of this content visit <https://www.bmj.com/company/products-services/rights-and-licensing/permissions/>
BMJ Case Report Fellows may re-use this article for personal use and teaching without any further permission.

Become a Fellow of BMJ Case Reports today and you can:

- ▶ Submit as many cases as you like
- ▶ Enjoy fast sympathetic peer review and rapid publication of accepted articles
- ▶ Access all the published articles
- ▶ Re-use any of the published material for personal use and teaching without further permission

Customer Service

If you have any further queries about your subscription, please contact our customer services team on +44 (0) 207111 1105 or via email at support@bmj.com.

Visit casereports.bmj.com for more articles like this and to become a Fellow