

## Case Report

# Veno-venous extracorporeal membrane oxygenation for severe pneumonia: COVID-19 case in Japan

Hayato Taniguchi,<sup>1</sup>  Fumihiro Ogawa,<sup>1</sup>  Hiroshi Honzawa,<sup>1</sup> Keishi Yamaguchi,<sup>1</sup> Shoko Niida,<sup>1</sup> Mafumi Shinohara,<sup>1</sup> Kohei Takahashi,<sup>1</sup>  Masayuki Iwashita,<sup>1</sup> Takeru Abe,<sup>1</sup> Sousuke Kubo,<sup>2</sup> Makoto Kudo,<sup>2</sup> and Ichiro Takeuchi<sup>1</sup>

<sup>1</sup>Advanced Critical Care and Emergency Center, and <sup>2</sup>Respiratory Disease Center, Yokohama City University Medical Center, Yokohama, Japan

**Background:** Veno-venous extracorporeal membrane oxygenation (VV-ECMO) is one of the ultimate treatments for acute respiratory failure. However, the effectiveness of ECMO in patients with novel coronavirus disease (COVID-19) is unknown.

**Case Presentation:** A 72-year-old woman who was a passenger of a cruise ship tested positive for the severe acute respiratory syndrome coronavirus 2 (SARS-CoV-2) while in quarantine on board using throat swab. Three days after admission, her condition deteriorated, and she was subsequently intubated. On day 6, VV-ECMO was introduced. Lopinavir/ritonavir was given; continuous renal replacement therapy was also introduced. On day 10, her chest radiography and lung compliance improved. She was weaned off ECMO on day 12.

**Conclusion:** Treatment of severe pneumonia in COVID-19 by ECMO should recognize lung plasticity considering time to ECMO introduction and interstitial biomarkers. In Japan, centralization of ECMO patients has not been sufficient. Thus, we suggest nationwide centralization and further research to respond to the crisis caused by COVID-19.

**Key words:** Coronavirus disease 2019, extracorporeal membrane oxygenation, Japan, lopinavir, ritonavir, severe acute respiratory syndrome coronavirus 2

## INTRODUCTION

THE NOVEL CORONAVIRUS disease (COVID-19) was first reported in Wuhan, China, and it is now spreading worldwide. In Japan, since a cruise ship docked in Yokohama, the number of domestic patients has gradually increased. Among Chinese cases, the prevalence of severe pneumonia in COVID-19 was 4.7%, and the mortality rate was 2.3%.<sup>1</sup>

Veno-venous extracorporeal membrane oxygenation (VV-ECMO) is one of the ultimate treatments for acute respiratory failure<sup>2</sup>; however, the effectiveness of ECMO in patients with COVID-19 is unknown. In this report, we

describe the treatment of severe pneumonia in the first COVID-19 case in Japan treated with VV-ECMO.

## CASE REPORT

A 72-year-old, native Hawaiian woman, who was a passenger of a cruise ship, tested positive for the severe acute respiratory syndrome coronavirus 2 (SARS-CoV-2) while in quarantine on board using throat swab. She was transported to our emergency room with fever and dyspnea after 4 days (considered as day 1 for the case timeline). She had a history of chronic kidney disease stage 4 and diabetes. She also had class 2 obesity (body mass index, 38 kg/m<sup>2</sup>).

Vital signs at the emergency room were as follows: the patient was alert; respiratory rate, 24 breaths/min; oxygen saturation, 99% under oxygen mask at 5 L/min; heart rate, 119 b.p.m.; and blood pressure, 153/103 mmHg. Physical examination revealed bilateral wheezing. Laboratory test results on admission are shown in Table 1. Chest radiography and computed tomography showed bilateral ground-glass opacities and consolidation (Fig. 1, day 1). On arrival,

**Corresponding:** Fumihiro Ogawa, MD, PhD, Advanced Critical Care and Emergency Center, Yokohama City University Medical Center, 4-57 Urafune-cho, Minami-ku, Yokohama 232-0004, Japan. E-mail: fumihiro.tigers@gmail.com

Received 9 Mar, 2020; accepted 14 Mar, 2020

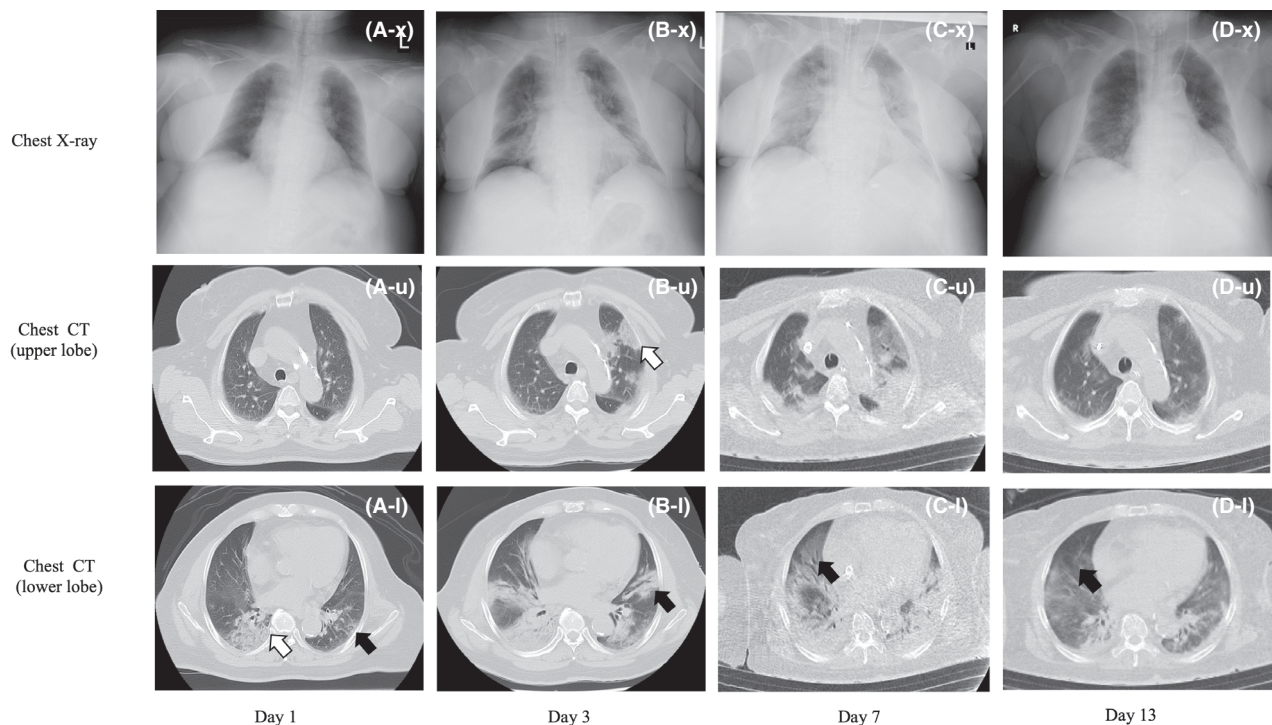
### Funding Information

No funding information provided.

**Table 1.** Clinical laboratory results of a 72-year-old woman with COVID-19 infection

Measure	Day 1	Day2	Day 3	Day 5	Day 7	Day 9	Day 11	Day 13
White cell count (per $\mu\text{L}$ )	11,500	7,100	7,400	9,700	19,100	11,000	11,600	12,300
Absolute lymphocyte count (per $\mu\text{L}$ )	1,242	923	657	237	401	243	297	545
Serum creatinine (mg/dL)	4.05	4.64	4.80	7.01	8.48	5.16	4.19	5.01
C-reactive protein (mg/dL)	3.12	6.47	8.99	15.5	21.1	19.3	11.4	3.99
KL-6 (ng/mL)	–	–	379	–	433	–	385	405
SP-D (ng/mL)	–	–	<17.2	–	47.2	–	55.4	46.7
Brain natriuretic peptide (pg/mL)	8.4	–	28.8	–	28.7	–	–	47.4
Blood gas pH	7.38	–	7.33	7.22	7.31	7.41	7.44	7.38
Blood gas bicarbonate (mEq/L)	15.5	–	17.8	13.7	15.1	21.0	23.1	22.8

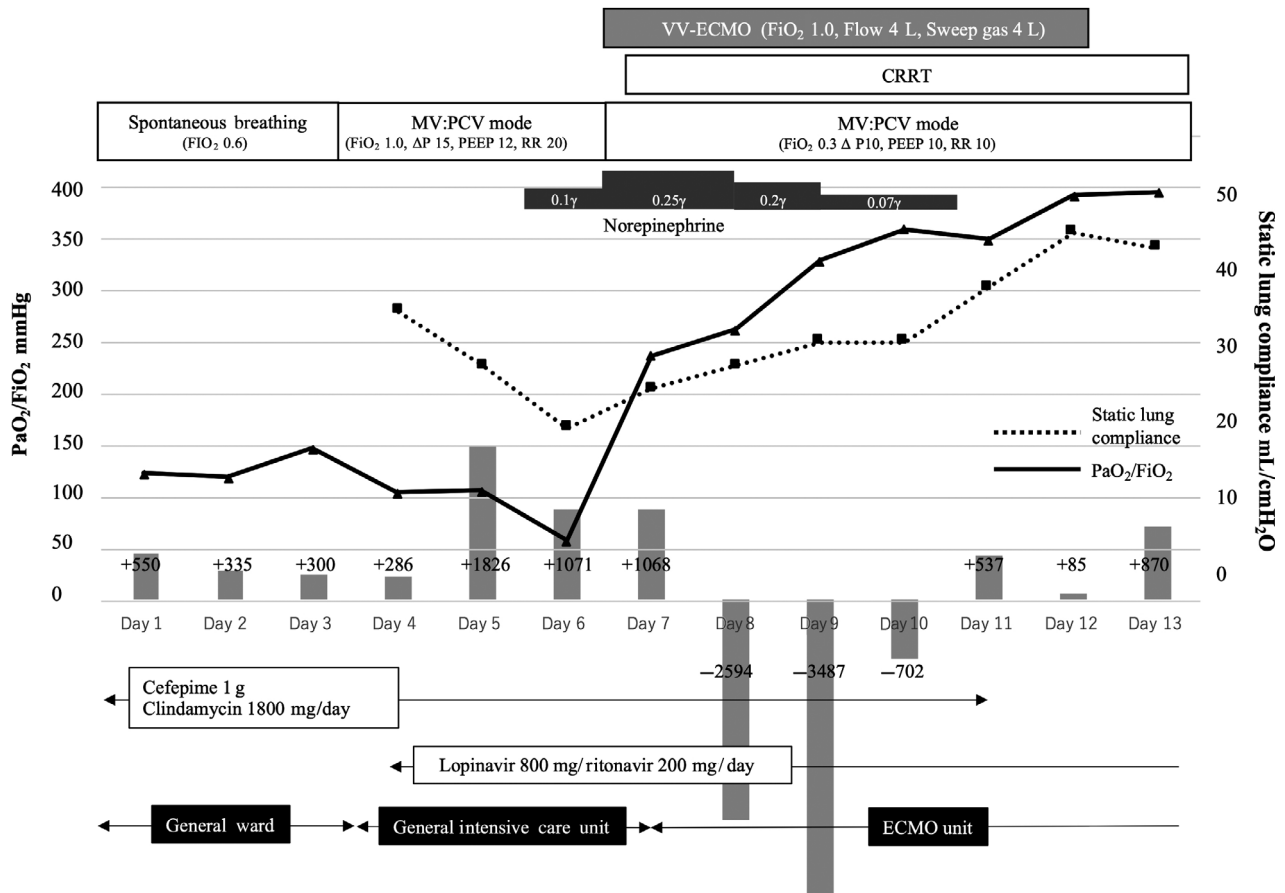
–, not measured; KL-6, Krebs von den Lungen-6; SP-D, surfactant protein-D.



**Fig. 1.** Chest X-ray and computed tomography (CT) images of a 72-year-old woman with COVID-19 infection. Day 1: ground-glass opacities (black arrow) and consolidation (white arrow) are apparent on the left lower lobe (A-l). Day 3: new consolidation appeared on the left lower lobe (black arrow) (B-l) and left upper lobe (white arrow) (B-u). Day 7: pulmonary congestion on the right lower lobe (black arrow) and consolidation progressed to all the upper lobe (C-l). Day 13: pulmonary congestion was improved on the right lower lobe (black arrow) and consolidation was improved on all the upper lobe (D-l).

her condition was relatively stable, and she was diagnosed with mild pneumonia caused by SARS-CoV-2. She was subsequently admitted to the isolation room in a respiratory ward.

After admission, oxygen therapy was maintained and 1 g cefepime and 1800 mg clindamycin phosphate were given every day. On day 3, pneumonia worsened (Fig. 1, day 3), which led to acute respiratory distress syndrome (ARDS).



**Fig. 2.** Time course of a 72-year-old woman with COVID-19 infection in terms of physical conditions, therapeutic intervention, and extracorporeal membrane oxygenation (ECMO) status.  $\Delta P$ , driving pressure; CRRT, continuous renal replacement therapy; MV, mechanical ventilation; PCV, pressure control ventilation; PEEP, positive end-expiratory pressure; RR, respiratory rate; VV-ECMO, veno-venous ECMO.

She was transferred to the general intensive care unit and then intubated (Fig. 2). Lopinavir/ritonavir, which was approved by the ethics committee as a treatment for COVID-19, was given for 2 weeks.

Three days later, as serum creatine level increased, urine output was almost zero and metabolic acidosis caused excessive spontaneous breathing (Table 1). Although cardiac function was normal, norepinephrine was needed to maintain blood pressure. We determined that the reason for hypoxia was not cardiogenic congestion by acute kidney injury in chronic kidney disease, but severe ARDS and septic shock that had developed from SARS-CoV-2.

The patient was transferred to our ECMO unit, and we decided to establish VV-ECMO. The right internal jugular vein was cannulated with a 25-Fr heparin-coated cannula for blood access, and the right femoral vein was cannulated with a 23-Fr heparin-coated cannula for blood return. The

procedure was completed safely, and no complications occurred.

Once the oxygenation was stable, we started continuous renal replacement therapy (CRRT). Early nutrition and rehabilitation were undertaken after ECMO introduction. On day 10, her chest radiography and lung compliance improved. The ECMO was discontinued on day 12 (the duration of ECMO support was 6 days). The respirator was removed after tracheostomy on day 19.

## DISCUSSION

UNTIL NOW, NO drug has been confirmed to be safe and effective for severe COVID-19 pneumonia. The World Health Organization interim guidelines made recommendations for the treatment of ARDS in this setting, including referring patients with refractory respiratory

failure to expert centers capable of providing VV-ECMO.<sup>3</sup> Yokohama City University Medical Center Advanced Critical Care and Emergency Center is a referral center for adult patients requiring ECMO in Yokohama, Japan, and is a member of the Extracorporeal Life Support Organization.

The role of ECMO in the management of COVID-19 is unclear at this point. However, ECMO is one of the treatment options in severe ARDS.<sup>2</sup> Extracorporeal membrane oxygenation is still invasive with significant potential for complications, and the high resource costs could present economic challenges to the health system.<sup>4</sup> Clinical judgment is needed to decide whether ECMO is effective or not, accompanied by understanding the risk-to-benefit ratio. Therefore, it is important to predict cases where ECMO could be an effective treatment method.

In the present case, the patient was weaned off ECMO for the following reasons. First, the timing of ECMO introduction might be adequate. Venovenous ECMO was introduced on day 3 after intubation. The Respiratory ECMO Survival Prediction score was also 1 point, with an expected survival of 60%. In addition, the levels of biomarkers such as Krebs von den Lungen-6 (KL-6) and surfactant protein-D (SP-D), which indicate lung injury, had not increased.<sup>5</sup> Although it has been reported pneumonia caused by SARS-Cov-2 progresses slowly and was likely severe,<sup>1</sup> at a time when lung plasticity was maintained, ECMO introduction might prevent subsequent lung injury. In fact, KL-6 and SP-D levels still had not increased by day 13 (Table 1).

Second, the recognition and treatment of the cause of the worsening oxygenation might be appropriate. One of the causes of worsening oxygenation might be overvolume due to acute kidney injury in chronic kidney disease. However, we believed that the cause of worsening oxygenation was not only overvolume but also aggravation of ARDS by COVID-19 pneumonia. According to the computed tomography, COVID-19 pneumonia progressed on day 3. The radiologist suggested that inflammatory findings were stronger than pulmonary congestion. Therefore, we introduced ECMO to stabilize oxygenation and rest the lungs. We then removed excessive water and improve metabolic acidosis by CRRT.

Third, it may have reduced inflammatory substances. We administered lopinavir/ritonavir to control the virus and improve inflammation.<sup>6</sup> No virus was detected in tracheal sputum after ECMO withdrawal. Another possibility was removal of inflammatory substances by CRRT, however, we did not exam inflammatory cytokines such as interleukin-1B and  $\gamma$ -interferon.<sup>7</sup> Additional research is needed.

To the best of our knowledge, this is the first report of VV-ECMO used to treat severe COVID-19 pneumonia in Japan. During the 2009 flu pandemic (H1N1), the

effectiveness of ECMO was established through regional or national coordination of ECMO referral centers with dedicated interhospital retrieval teams.<sup>8</sup> However, in Japan, many hospitals are ECMO capable but have low case volumes, and centralization has not been adequate compared with the UK or Sweden.

In conclusion, to treat severe COVID-19 pneumonia by ECMO, we should recognize lung plasticity and appropriately implement ECMO following Extracorporeal Life Support Organization guidelines. At present, given the increasing concern about pandemics, we suggest that countries, such as Japan, should expedite centralization of ECMO and the collection of data, and researchers should undertake further investigations to respond to the crisis caused by COVID-19.

## ACKNOWLEDGEMENTS

WE THANK OUR colleagues in the Department of Emergency Medicine, Yokohama City University.

## DISCLOSURE

Approval of the research protocol: N/A.

Informed consent: Written informed consent was obtained from the patient for the publication of this case report.

Registry and the registration no. of the study/trial: N/A.

Animal studies: N/A.

Conflict of interest: None.

## REFERENCES

- 1 Wang D, Hu B, Hu C *et al* Clinical characteristics of 138 hospitalized patients with 2019 novel coronavirus-infected pneumonia in Wuhan, China. *JAMA* 2020; 323: 1061–9.
- 2 Brodie D, Slutsky AS, Combes A. Extracorporeal life support for adults with respiratory failure and related indications: a review. *JAMA* 2019; 322: 557–68.
- 3 World Health Organization. Clinical management of severe acute respiratory infection when novel coronavirus (2019-nCoV) infection is suspected—interim guidance. Published January 28, 2020. Accessed February 11, 2020.
- 4 Maclaren G, Fisher D, Brodie D. Preparing for the most critically ill patients with COVID-19: The potential role of extracorporeal membrane oxygenation. *JAMA* 2020. <https://doi.org/10.1001/jama.2020.2342>. [Epub ahead of print]
- 5 Determann RM, Royakkers AA, Haitsma JJ *et al* Plasma levels of surfactant protein D and KL-6 for evaluation of lung injury in critically ill mechanically ventilated patients. *BMC Pulm. Med.* 2010; 10: 6.

- 6 Chu CM, Cheng VC, Hung IF *et al* Role of lopinavir/ritonavir in the treatment of SARS: initial virological and clinical findings. *Thorax* 59: 252–6.
- 7 Huang C, Wang Y, Li X *et al* Clinical features of patients infected with 2019 novel coronavirus in Wuhan, China. *Lancet* 2020; 395: 497–506.
- 8 Sukhal S, Sethi J, Ganesh M, Villablanca PA, Malhotra AK, Ramakrishna H. Extracorporeal membrane oxygenation in severe influenza infection with respiratory failure: A systematic review and meta-analysis. *Ann. Card. Anaesth.* 2017; 20: 14–21.