

Review

Open Access

## Phylloides tumor of the breast: a rare neoplasm, though not that innocent

Michael Stamatakos\*<sup>1</sup>, Sofia Tsaknaki<sup>1</sup>, Konstantinos Kontzoglou<sup>1</sup>, John Gogas<sup>1</sup>, Alkiviades Kostakis<sup>1</sup> and Michael Safioleas<sup>2</sup>

Address: <sup>1</sup>Department of Propedeutic Surgery, Medical School, University of Athens, Laiko General Hospital, Athens, Greece and <sup>2</sup>Department of Surgery, Medical School, University of Athens, ATTIKON General Hospital, Athens, Greece

Email: Michael Stamatakos\* - [stamatakosmih@yahoo.gr](mailto:stamatakosmih@yahoo.gr); Sofia Tsaknaki - [stamatakosmih@yahoo.gr](mailto:stamatakosmih@yahoo.gr); Konstantinos Kontzoglou - [stamatakosmih@yahoo.gr](mailto:stamatakosmih@yahoo.gr); John Gogas - [stamatakosmih@yahoo.gr](mailto:stamatakosmih@yahoo.gr); Alkiviades Kostakis - [stamatakosmih@yahoo.gr](mailto:stamatakosmih@yahoo.gr); Michael Safioleas - [stamatakosmih@yahoo.gr](mailto:stamatakosmih@yahoo.gr)

\* Corresponding author

Published: 20 February 2009

Received: 8 July 2007

Accepted: 20 February 2009

*International Seminars in Surgical Oncology* 2009, **6**:6 doi:10.1186/1477-7800-6-6

This article is available from: <http://www.issoonline.com/content/6/1/6>

© 2009 Stamatakos et al; licensee BioMed Central Ltd.

This is an Open Access article distributed under the terms of the Creative Commons Attribution License (<http://creativecommons.org/licenses/by/2.0>), which permits unrestricted use, distribution, and reproduction in any medium, provided the original work is properly cited.

### Abstract

**Background:** Cystosarcoma phylloides (CP) is an extremely rare form of breast cancer with an unpredictable clinical course. The histological characteristics of this neoplasm have not proved to offer much in the estimation of prognosis of these patients.

**Patients and methods:** In our clinics, in a time period of 38 years, 22 patients with cystosarcoma phylloides were treated. There were 5 cases of malignancy, 15 cases with benign tumors, and two cases histologically characterized as borderline neoplasia. Metastases were manifested in one patient. All patients were on a 5-year follow-up, except in five cases, one operated three years ago and four operated within the last two years.

**Results:** 16 of 22 patients did not present any signs of local recurrence or metastases. There were three patients that manifested local recurrence and underwent supplementary onectomy or mastectomy and are free of recurrence ever since. One patient with metastatic CP died.

**Conclusion:** Independently of its histopathological behavior, CP is a tumor difficult to be treated. Meticulous follow-up is mandatory in order to manage possible recurrence of the neoplasm.

### Background

Cystosarcoma phylloides (CP) constitutes a rare form of breast neoplasia, which represents less than 1% of total breast neoplasias and only 2,3% of all fibro-epithelial breast tumors [1-4]. It was first described by Muller in 1838, who also introduced the term "cystosarcoma phylloides" because of the extensions of the tumor mimicking the shape of leaves, intruding within the cystic cavities of the tumor [5]. This neoplasm is manifested in women of all ages, including adolescent and the elderly, with the

majority ranging between 35 and 54 years [6-10]. Multiple studies have been conducted during the recent years concerning the comprehension of the biological behavior of CP [11,12]. The histological classification of these neoplasms into benign, malignant and borderline has not proven to be successful, because the benign form of cystosarcoma phylloides could manifest metastases, while cases with malignant type of CP finally presented an excellent prognosis [13-15].

### Presentation of our experience

In the time period between 1968 and 2007, 22 women of a mean age of 38 years, presented in our clinics with the diagnosis of cystosarcoma phylloides. Among them 19 were operated for breast tumor, which was proved by the histological examination to be a cystosarcoma phylloides. The remaining three were previously treated in other institutions and were referred to our hospital for further treatment.

The main complaint among these women was a palpable, painless mass of the breast. Two patients presented pain of the breast region, while one patient mentioned tenderness of the respective axilla. In 11 patients the mass was located on the right breast, while in the remaining 11 patients it was found in the left breast. The clinical examination revealed a solitary mobile tumoral lesion in all the patients, measuring between 3–12 cm. Three patients presented with dilated veins of the overlying skin and in one case bluish discoloration of the skin of the breast above the tumor was present. A palpable mass of the respective auxiliary region was observed in two women.

The initial management was surgical in 21 of 22 cases, including tumor resection within healthy borders in 12 patients and simple mastectomy in 5 cases. The two patients with enlarged lymph glands were treated by modified radical mastectomy, and there were two cases where subcutaneous mastectomy and silicone prostheses insertion was performed. Among them, there was a woman who presented at our clinic with the diagnosis of benign cystosarcoma phylloides, from a recent breast biopsy performed elsewhere, who underwent wide local excision of the remaining tumor. This patient had two local excisions of a benign cystosarcoma phylloides eight and four years previously. There was also one patient who manifested local recurrence of benign CP, having undergone simple mastectomy six months before at another institution. The remaining patient had undergone a previous simple mastectomy three years ago for the management of malignant CP and did not present any signs of local recurrence, but only clinical signs of pulmonary and pleural metastasis.

### Results

Histological examination of the resected breast segment revealed a benign lesion in 15 cases, a malignant tumor in 4 cases, while in the remaining two cases the neoplasm was characterized as borderline. The enlarged lymph nodes resected in two patients were established by the pathologicoanatomic examination as presenting signs of reactive hyperplasia, and no metastatic element was identified in them.

The woman who presented with pulmonary and pleural metastasis, established by clinical examination and laboratory control (chest X-rays, pleural aspiration and cytological examination) died three months after the diagnosis.

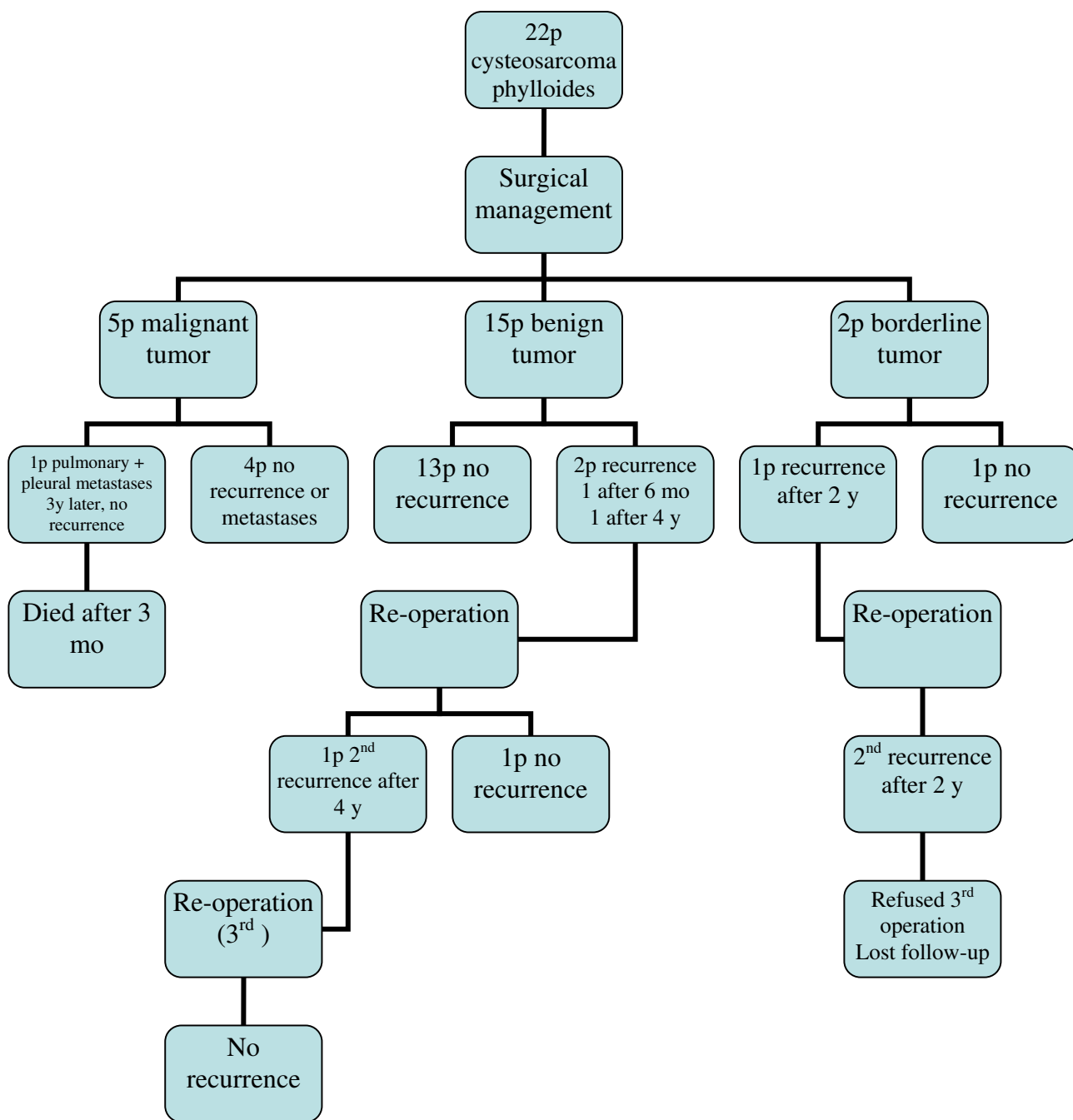
All the remaining patients were followed-up for 5 years for signs of recurrence. One of the patients with a CP characterized as borderline manifested local recurrence two years after initial onectomy. She was managed by wide total excision of the tumor, though she came back two years after the second operation with signs of a new recurrence. She refused to undergo a third operation for esthetic reasons and was lost on follow-up. Another woman appeared four years after primary surgical treatment with a locally recurred lesion; a wide local excision was performed. However, the histological examination demonstrated that the tumor was a fibroadenoma, thus this case was not considered as a recurrent CP. The remaining women did not manifest any signs of recurrence during follow-up. The last five patients who were treated in our institution for cystosarcoma phylloides were operated one of them three years ago, two of them one year ago and the remaining two were treated within the year 2007, so they have not yet completed the 5-year follow-up; until today all five are free of recurrence symptoms and signs.

Figure 1 demonstrates the clinical course of all 22 patients treated in our hospital, since the disease first appeared.

### Discussion

Cystosarcoma phylloides is a rare breast tumor, which presents a rapid development among young women. It usually takes over a quarter or half of the affected breast. On palpation it is mobile with clear borders. Due to the big size of the tumor, the overlying skin is tense, and presents a visible and dilated venous plexus. As a result, skin ulceration may easily be created. Enlargement of the auxiliary lymph nodes is a rare symptom. These tumors are most commonly benign and only 10% of them present a malignant behavior. They do not manifest breast fascia infiltration, though they invade in adjacent tissues. At a rate of 50% these neoplasms give metastasis to the bones and viscera, mainly hematogenously [16]. Another common characteristic seems to be their frequently observed local recurrences, independently of malignancy [17].

Laboratory control, such as ultrasonography, mammography, etc., in combination with the clinical examination and the self-examination will definitely lead to the recognition of a lesion variably sized. Small tumors may be characterized as fibroadenomas [18], while larger ones look like sarcomas of undefined appearance, create ten-



**Figure 1**  
**Clinical course of 22 patients with cysteosarcoma phylloides.**

sion on the skin and may present regions of superficial hemorrhage or necrosis. The prognostic value of immuno-histochemical indexes for the cystosarcoma phylloides provides very little to a definitive prognosis. This is due to the small number of studies upon this subject, as well as the variety of histological classifications for CP [19-21].

Through the years, all types of breast surgery have been used for the management of cystosarcoma phylloides.

Radical mastectomy is no longer applied, and because the tumor is heamatogenously disseminated, resection of auxiliary lymph nodes is not justified [20,22]. Nowadays,

the preferred procedure is local resection of the tumor within healthy borders (1–2 cm) in order to prevent local recurrence [12,23]. A total mastectomy is performed if necessary, such as in cases of large tumors, which occupy the whole breast [23–25]. For cystosarcomas which have already manifested metastases, there is no sufficient treatment available for a successful control of the disease [26]. The role of chemotherapy and radiotherapy remains uncertain [27–30]. Today, however, the studies upon estrogen and progesterone receptors in these tumors seem to provide hopeful results, useful for the hormonal management of CP [30,31].

### Conclusion

Cystosarcoma phylloides is a rare neoplastic condition of the breast, which belongs to the non-epithelial tumors. The classification by authors into benign and malignant is not particularly successful, because the natural history of the tumor is not always related to its histological image. Its equivocal biological behavior may affect the patients' prognosis and survival, and thus it remains an unsolved puzzle, which evolving studies will try to clarify in the future.

### Abbreviations

CP: Cystosarcoma phylloides.

### Consent

Written informed consent was obtained from the patients.

### Competing interests

The authors declare that they have no competing interests.

### Authors' contributions

MS was the surgeon who performed the operations and edited part of the manuscript. ST carried out literature search, revision of bibliography and helped to prepare the draft. KK was the surgeon who performed the operation and edited most of the manuscript. JG was the surgeon who performed the operations. MS was the surgeon who performed the operations.

### References

- Gogas JG: **Cystosarcoma Phylloides: A clinicopathological analysis of 14 cases.** *International Surgery* 1979, **64**:77-80.
- Kessinger A, Folley JF, Loron HM, Miller DM: **Metastatic cystosarcoma phylloides: a case report and review of the literature.** *J Surg Oncol* 1972, **4**:131-47.
- Vorherr H, Vorherr UF, Kutvirt DM, Key CR: **Cystosarcoma phylloides: epidemiology, pathophysiology, pathobiology, diagnosis, therapy and survival.** *Arch Gynaecol* 1985, **236**:173-81.
- Tan EY, Tan PH, Yong WS, Wong HB, Ho GH, Yeo AW, Wong CY: **Recurrent phyllodes tumours of the breast: pathological features and clinical implications.** *ANZ J Surg* 2006, **76**:476-80.
- Muller J: **Über den Feineren Bau und die Formen der Krankhaften Geschwulstre.** Berlin, G. Reimer; 1938:54.
- Parker SJ, Harries SA: **Phyllodes tumours.** *Postgrad Med J* 2001, **77**:428-35.
- Cohn-cedermark G, Rutqvist LE, Rosendahl I: **Prognostic factors in cystosarcoma phylloides: a clinicopathologic study of 77 patients.** *Cancer* 1991, **68**:2017-22.
- Cheng SP, Chang YC, Liu TP, Lee JJ, Tzen CY, Liu CL: **Phyllodes tumor of the breast: the challenge persists.** *World J Surg* 2006, **30**:1414-21.
- Palmer ML, De Risi DC, Pelikan A, Patel J, Nemoto T, Rosner D, Dao TL: **Treatment options and recurrence potential for cystosarcoma phylloides.** *Surg Gynec Obstet* 1990, **170**:193-6.
- Rajan P, Cranor M, Rosen P: **Cystosarcoma phylloides in adolescent girls and young women: a study of 45 patients.** *Am J Surg Pathol* 1998, **22**:64-9.
- Pietruszka M, Barnes L: **Cystosarcoma phylloides. A clinicopathologic analysis of 42 cases.** *Cancer* 1978, **41**:1947.
- Oberman HA: **Cystosarcoma phylloides.** *Cancer* 1965, **18**:697.
- West TL, Weiland LH, Clagett OT: **Cystosarcoma phylloides.** *Ann Surg* 1971, **173**:520.
- Blinchert-Toft M, Hansen JPH, Hansen OH, Schiødt T: **Clinical course of cystosarcoma phylloides related to histologic appearance.** *Surg Gyn Obst* 1975, **140**:429.
- McDivitt RV, Urban JA, Farrow JW: **Cystosarcoma phylloides.** *John Hopkins Med J* 1967, **120**:33.
- Treves N, Sunderland DA: **Cystosarcoma phylloides of the breast—a malignant and a benign tumor, a clinicopathological study of seventy-seven cases.** *Cancer* 1951, **4**:1286-32.
- Haagensen CD: **Diseases of the breast.** Philadelphia, Saunders; 1965.
- Tomimaru Y, Komoike Y, Egawa C, Motomura K, Inaji H, Kataoka TR, Koyama H: **A case of phyllodes tumor of the breast with a lesion mimicking fibroadenoma.** *Breast Cancer* 2005, **12**:322-6.
- Chen WH, Cheng SP, Tzen CY, Yang TL, Jeng KS, Liu CL, Liu TP: **Surgical treatment of phyllodes tumors of the breast: retrospective review of 172 cases.** *J Surg Oncol* 2005, **91**:185-94.
- Norris HJ, Taylor HB: **Relationship of histologic features to behavior of cystosarcoma phylloides. Analysis of 94 cases.** *Cancer* 1967, **20**:2090.
- Dacic S, Kounelis S, Kouri E, Jones M: **Immunohistochemical profile of cystosarcoma phylloides of the breast: a study of 23 cases.** *The Breast Journal* 2002, **8**:376-81.
- McGregor GI, Knowlting MA, Este FA: **Sarcoma and cystosarcoma phylloides. Tumors of the breast: a retrospective review of 58 cases.** *Am J Surg* 1994, **167**:447-80.
- Haagensen CD: **Cystosarcoma phylloides in disease of the breast.** 2nd edition. W.B. Saunders Co. Ed; 1971:227.
- Ross DE: **Malignancy occurring in cystosarcoma phylloides.** *Ann Surg* 1954, **88**:243.
- Maier VWP, Rosemond GP, Wittenberg P, Tassom EM: **Cystosarcoma phylloides mammae.** *Oncology* 1968, **22**:145.
- Asoglu O, Ugurlu MM, Blanchard K, Grant CS, Reynolds C, Cha SS, Donohue JH: **Risk factors for recurrence and death after primary surgical treatment of malignant phyllodes tumors.** *Ann Surg Oncol* 2004, **11**:1011-7.
- Carabell SC, Goodman RT: **Radiation therapy for soft tissue sarcoma.** *Semin Oncol* 1981, **8**:201-6.
- Hawkins RE, Schofield JB, Wiltshaw E, Fisher C, McKinna JA: **Chemotherapy for metastatic cystosarcoma phylloides: ifosfamide is an active drug.** *Cancer* 1992, **69**:2271-5.
- Burton GV, Hart LL, Leight GS, Iglehart JD, McCarty KS, Cox EB: **Cystosarcoma phylloides: effective therapy with cisplatin and etoposide chemotherapy.** *Cancer* 1989, **63**:2088-92.
- Joshi SC, Sharma DN, Bahadur AK, Maurya R, Kumar S, Khurana N: **Cystosarcoma phylloides: Our institutional experience.** *Australasian Radiology* 2003, **47**:434-7.
- Palshof T, Blickert-Taft M, Daehnfelt L: **Estradiol binding protein in cystosarcoma phylloides of the breast.** *Eur J Cancer* 1980, **16**:591-3.