


Case Report

Paraplesia after surfing in a young female novice surfer: a case report on surfer's myelopathy

Hidehiko Nakano,¹  Daisuke Yamamoto,² Hiroshi Yamagami,¹ Ichiro Sekine,^{1,2} and Hisashi Ofuchi¹

¹Emergency Department, and ²Department of Neurology, Shonan Kamakura General Hospital, Kamakura, Kanagawa, Japan

Background: Surfer's myelopathy is a non-traumatic spinal cord injury that was first described in a publication in 2004. However, most emergency physicians are not familiar with this rare disease.

Case Presentation: The patient was a 19-year-old female novice surfer. She had experienced back discomfort without trauma during her surfing lessons. The discomfort turned to dysesthesia of both legs. She could not walk after 1 h and was brought to our hospital. Physical examination revealed weakness and dysesthesia of both legs, absent deep tendon reflexes, bilaterally positive Babinski reflex, and bladder and rectal disturbance. Spine magnetic resonance imaging revealed T2 prolongation from T7 to the medullary cone. She was diagnosed with surfer's myelopathy and treated conservatively. She recovered well and was discharged on day 28.

Conclusion: Emergency physicians must be better informed about surfer's myelopathy. Novice surfers and instructors should be educated on the early signs and symptoms of this condition.

Key words: Emergency Department, central nervous system, surfing, spinal cord injury, spinal cord ischemia

INTRODUCTION

Surfing is a popular sport, with approximately 2 million surfers participating at different levels in Japan. When a young female novice surfer with non-traumatic spinal cord injury presented at Shonan Kamakura General Hospital (Kamakura, Japan), the recognition of surfer's myelopathy among emergency physicians was very poor, even though the Shonan area, where our hospital is located, is one of the most famous domestic surfing spots. This disease is rare, but emergency physicians should be aware of it as it is thought that patients will call an ambulance when this disease develops.

CASE

A 19-year-old healthy woman was transferred to the emergency department at our hospital for paraplegia. She had enjoyed a second surfing lesson in the morning

Corresponding: Hidehiko Nakano, Shonan Kamakura General Hospital, 〒247-8533 1370-1 Okamoto, Kamakura, Kanagawa, Japan. E-mail: be.rann1988jp@gmail.com.

Received 24 Jan, 2019; accepted 13 Mar, 2019; online publication 5 Apr, 2019

Funding information

No funding information provided.

without any trauma. She experienced discomfort in her hip during the lesson, and it progressed to dysesthesia of bilateral legs at the end of the lesson. She rested for 1 h; however, her legs had gradually become weak. She then called for an ambulance as she could not walk by herself.

She was conscious, and her other vital signs were normal. No traumatic mark was found during the examination. Neurological findings were normal in the upper extremities. Manual muscle testing score in flexion and extension of the hip and knee joints was 2/5 and in flexion and extension of the ankle joint was 4/5. Patellar and Achilles tendon reflexes were absent and Babinski reflexes were bilaterally positive. Dysesthesia in her bilateral legs and bladder and bowel disturbance were also found.

Laboratory data, lumbar spine X-ray imaging, and computed tomography were normal. Whole-spine magnetic resonance imaging (MRI) revealed a high-intensity area at the center of the spinal cord from T7 to the medullary cone on T2-weighted imaging (Fig. 1A). Lumbar puncture was carried out, and cerebrospinal fluid testing was normal except for slightly elevated protein levels (60.90 mg/dL).

Surfer's myelopathy was suspected and she was admitted to our hospital. We treated her with steroid pulse therapy (methylprednisolone 1,000 mg/day) from day 1 to day 3 because demyelinating spinal cord lesions, such as multiple sclerosis and neuromyelitis optica, were not clearly

excluded. Treatments for surfer's myelopathy are not established, but as her condition was severe, we also administered i.v. edaravone for 5 days, and undertook hyperbaric oxygen therapy 20 times according to spinal cord infarction, as the estimated etiology of surfer's myelopathy is ischemia.

After admission, additional blood tests to screen for thrombotic factors and vasculitis in addition to cerebrospinal fluid tests for the presence of multiple sclerosis and neuromyelitis optica were all found negative, so the patient was diagnosed with surfer's myelopathy.

Computed tomography angiography of the spine artery on day 2 revealed no vascular abnormality (Fig. 1B). A follow-up MRI of the cervical and thoracic spine was carried out on day 6 and that of the lumbar spine on day 9, none of which revealed any signal abnormality, edema, or atrophy of the spinal cord (Fig. 2).

During rehabilitation, she could walk with a walker from day 4, with a cane from day 6, and by herself from day 9; she could climb stairs from day 12. Urination disorder persisted, and she undertook catheter urination by herself. As the motor function recovered well, she was discharged home on day 28.

DISCUSSION

SURFER's myelopathy is a non-traumatic spinal cord injury of novice surfers, first reported by Thompson *et al.*¹ According to the review of 2016 by Freedman *et al.*,² only 64 cases had been reported until that time. Many cases

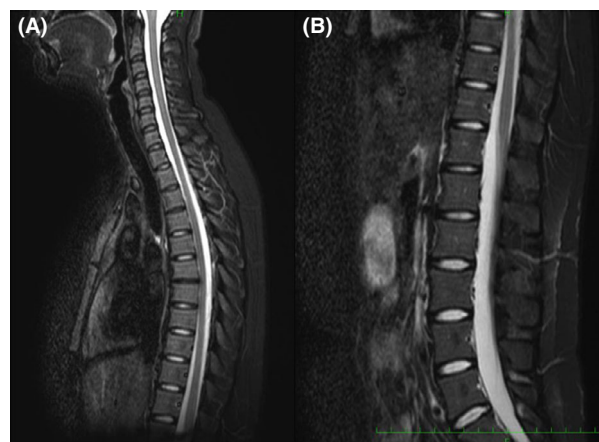


Fig. 2. Follow-up magnetic resonance imaging (MRI) of a 19-year-old woman diagnosed with surfer's myelopathy. A, Cervical and thoracic spine MRI on day 6. B, Lumbar spine MRI on day 9.

have been reported from Hawaii, and 32 Asian cases include Japanese cases;³ therefore, we should be aware this rare disease in Japan.

The etiology is considered to be spinal cord ischemia following the hyperextension of the spine involved in surfing.² As a mechanism of spinal cord infarction, the following three hypotheses have been proposed: (i) arterial ischemia due to physical compression, leading to injury, vasospasm, etc. of the Adamkiewicz artery, (ii) inferior vena cava

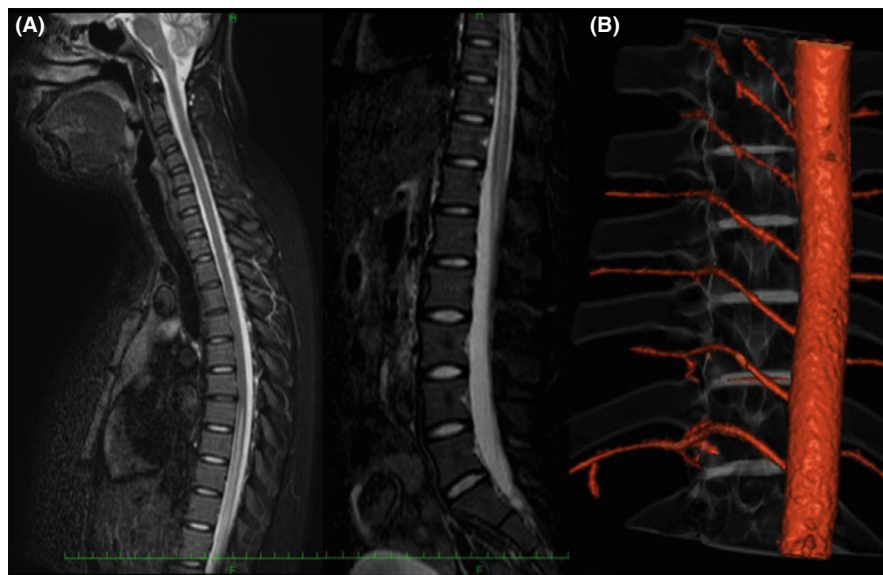


Fig. 1. Initial imaging results of a 19-year-old woman diagnosed with surfer's myelopathy. A, Whole-spine magnetic resonance imaging on day 1. B, Computed tomography angiogram of the spinal artery on day 2.

Table 1. Cases of suspected surfer's myelopathy not due to surfing

Report	Age (years)	Sex	Cause	Lesion
Lenn ¹¹	10	F	Fall from skateboard in lying position	T10–12
Tosi <i>et al.</i> ¹²	16	F	Handstand	Cone
Davis <i>et al.</i> ¹³	6	F	Cartwheel	T10–conus
Yasui <i>et al.</i> ¹⁴	8	M	Handstand	T9–conus
Yagishita <i>et al.</i> ¹⁵	5	F	Three-point handstand	T8–conus
Klontzas <i>et al.</i> ⁹	28	M	Stand-up paddle surfing	T12
Maharaj <i>et al.</i> ⁸	51	M	Cargo lifting	T12–L1
Albuja <i>et al.</i> ⁷	16	F	Back flip	T5
Albuja <i>et al.</i> ⁷	13	M	Friends jumped onto back	T5–7

compression and vesicular ischemia by Valsalva maneuver, (iii) fibrocartilaginous embolism.³ One case report mentions abnormal findings in angiography;² however, definite causes have not yet been determined.

Nakamoto *et al.*⁴ reported MRI characteristics in 23 patients, and all cases had “pencil-like” longitudinally extensive high-intensity T2-weighted signal abnormalities extending from the mid-thoracic to the conus, which were located at the center of the spinal cord. However, gadolinium enhancement was not typically observed. Chang *et al.*⁵ reported MRI characteristics in 19 patients, among which six showed restricted diffusion with changes on apparent diffusion coefficient mapping, suggesting an ischemic etiology of this disease.

In the review of Freedman *et al.*,² steroids were considered in 53 cases and given to 30 (57%). Most cases were managed according to the National Acute Spinal Cord Injury Study 3 protocol. A neurological outcome was described in 22 cases, and neurological improvement was found in 12 cases (55%). Among the remaining 10 cases without neurological improvement, seven cases were American Spinal Injury Association Impairment Scale (ASIA) class A. Overall, 80% of cases with ASIA class B or above improved. In addition, Freedman *et al.*² suggested treatment with tissue plasminogen activator and nicardipine, cerebrospinal fluid drainage, and induced hypertension targeting a mean arterial pressure of 85 mmHg for at least 24 h.

According to the report of Nakamoto *et al.*,⁴ no correlation was noted between MRI findings and disease prognosis, whereas the ASIA classification on admission is correlated with prognosis. In the report of Freedman *et al.*,² 51.6% experienced complete paralysis (ASIA class A or B) and 19.4% recovered; no cases recovered from ASIA class A. Conversely, Inagaki *et al.*⁶ reported a case that recovered from ASIA class A to D. As neurological improvement usually occurs within 24–72 h,² mild cases might not be

diagnosed and patients might not seek medical attention. The actual prognosis may be better if these cases are included.

Among case reports of surfer's myelopathy without surfing, we found three reports of four cases,^{7–9} by searching PubMed with the key words “surfer's myelopathy” and “without surfing.” In addition, Segami *et al.*¹⁰ reported cases that resemble surfer's myelopathy.^{11–15} We could confirm a total of nine cases reported (Table 1), among which five pediatric cases related to gymnastics are conspicuous. Therefore, surfing instructors as well as gymnastics educators need to be informed about this injury.

CONCLUSION

THE SPINAL CORD injury that can occur following a hyperextension of the spine during surfing is called surfer's myelopathy. There are also case reports related to gymnastics. Emergency physicians should be informed about this injury, and surfing instructors as well as gymnastics educators should be notified.

DISCLOSURE

Approval of the research protocol: N/A.

Informed consent: Informed consent was obtained from the patient's family for publication of this case report and accompanying images.

Registry and the registration no. of the study/trial: N/A.

Animal studies: N/A.

Conflict of interest: None declared.

REFERENCES

- 1 Thompson TP, Pearce J, Chang G *et al.* Surfer's myelopathy. *Spine (Phila Pa 1976)* 2004; 29: E353–6.

- 2 Freedman BA, Malone DG, Rasmussen PA *et al.* Surfer's myelopathy: a rare form of spinal cord infarction in novice surfers: a systematic review. *Neurosurgery* 2016; 78: 602–11.
- 3 Tashiro J, Hida K. Surfer's myelopathy from personal experience of a neurologist. *Spine Spinal Cord* 2016; 29: 770–5.
- 4 Nakamoto BK, Siu AM, Hashiba KA *et al.* Surfer's myelopathy: a radiologic study of 23 cases. *AJNR Am. J. Neuroradiol.* 2013; 34: 2393–8.
- 5 Chang CW, Donovan DJ, Liem LK *et al.* Surfer's myelopathy: a case series of 19 novice surfers with nontraumatic myelopathy. *Neurology* 2012; 79: 2171–6.
- 6 Inagaki T, Ando T. Surfer's myelopathy recovered prominently: a case report. *Spine Spinal Cord* 2016; 29: 777–81.
- 7 Albuja AC, Qaiser S, Lightner DD *et al.* Surfer's myelopathy without surfing: a report of two pediatric patients. *Spinal Cord Ser. Cases* 2017; 3: 17008.
- 8 Maharaj MM, Phan K, Hariswamy S *et al.* Surfer's myelopathy: a rare presentation in a non-surfing setting and review of the literature. *J. Spine Surg.* 2016; 2: 222–6.
- 9 Klontzas ME, Hatzidakis A, Karantanas AH. Imaging findings in a case of stand up paddle surfer's myelopathy. *BJR Case Rep.* 2015; 1: 20150004.
- 10 Segami K, Kanzaki K, Nakajima T *et al.* Surfer's myelopathy: a case report. *Spine Spinal Cord* 2016; 29: 787–90.
- 11 Lenn NJ. Spinal cord infarction due to minor trauma. *Neurology* 1977; 27: 999.
- 12 Tosi L, Rigoli G, Beltramello A. Fibrocartilaginou embolism of the spinal cord: a clinical and pathogenetic reconsideration. *J. Neural. Neurosurg. Psychiatry* 1996; 60: 55–60.
- 13 Davis GA, Klug GL. Acute-onset nontraumatic paraparesis in childhood: fibrocartilaginous embolism or acute myelitis? *Childs Nerv. Syst.* 2000; 16: 551–4.
- 14 Yasui K, Hasegawa Y, Ando T *et al.* Spinal cord infarction due to minor trauma in children. *Spine Spinal Cord* 2008; 21: 1003–7.
- 15 Yagishita A. Image diagnostic training learned from cases vol.11. *Spine Spinal Cord* 2013; 26: 1001–4.