

# A novel presentation of tubular adenoma of the breast as an intraductal mass: Diagnostic considerations and pathologic correlation

Sir,

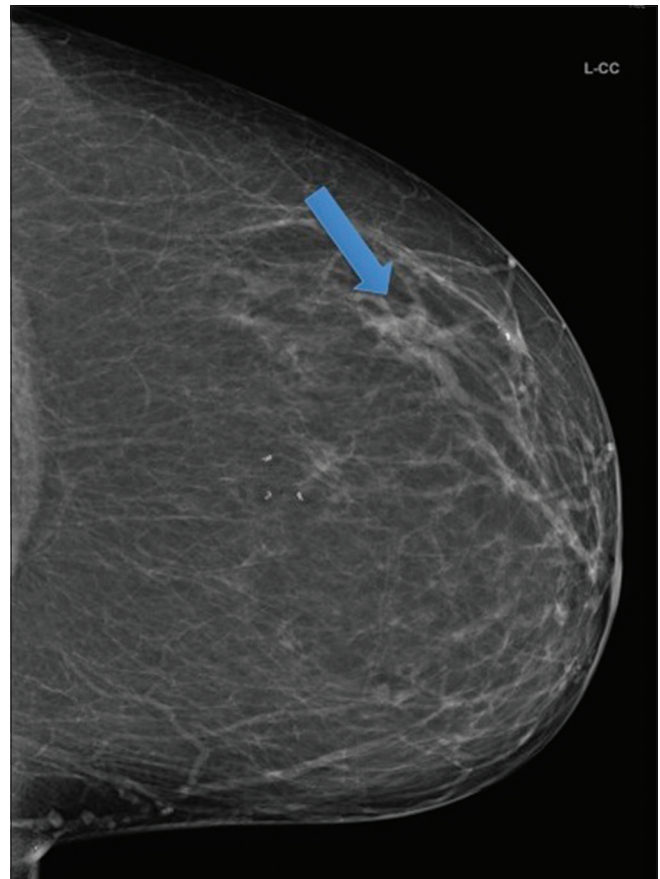
Tubular adenoma is a benign breast lesion, typically presenting as a palpable breast mass in a young woman. We present a novel case of tubular adenoma presenting as an intraductal mass, the first described case in the literature to our knowledge. There is limited information regarding the spectrum of imaging findings of this entity in the literature, which can pose a diagnostic and management challenge. We seek to broaden the realm of known imaging characteristics of tubular adenomas, and thus aid in accurate pathologic–radiologic correlation after tissue sampling. Lack of information on imaging characteristics has perhaps contributed to the standard recommendation for surgical resection in order to achieve diagnostic confirmation. Improving presurgical diagnostic confidence with both accepted radiological and pathological features would aid in cases where nonsurgical management is being sought. In addition, a more informed and confident discussion between the patient and the clinician could occur.

Tubular adenomas of the breast typically present in women of reproductive age, particularly under 35 years of age, as solid, circumscribed, noncalcified masses which are usually palpable. A less typical but well-described presentation of tubular adenoma is that of a non-circumscribed solid mass in an older woman, which may have associated microcalcifications (usually of low-grade suspicion).<sup>[1]</sup> Tubular adenoma should also be considered in the differential diagnosis of a gradually enlarging breast mass in a postmenopausal patient.<sup>[2]</sup>

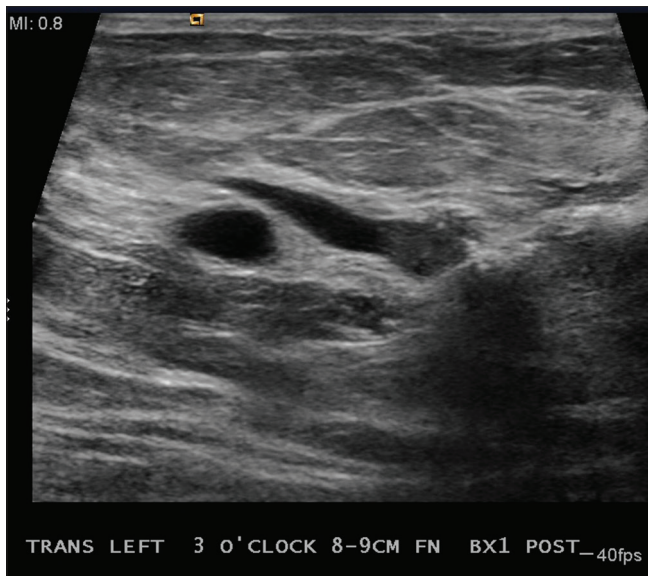
Our patient is a 56-year-female who presented with increased clear-yellow nipple discharge from the left breast, and was found to have an area of dilated ducts on diagnostic mammography [Figure 1], which were new from prior exams. These ducts appeared as focal tubular-like densities on mammography, with one having an apparent abrupt cut-off to its lumen, raising the suspicion for an intraductal abnormality with resultant ductal obstruction. Targeted ultrasound was performed, and a solid, intraductal mass was identified [Figures 2 and 3]. Ultrasound-guided biopsy was performed, and pathology demonstrated small, crowded glands in scant

fibrous stroma, which was consistent with a tubular adenoma [Figure 4]. This lesion demonstrated benign features, with no evidence of malignancy. Surgical consultation was recommended.

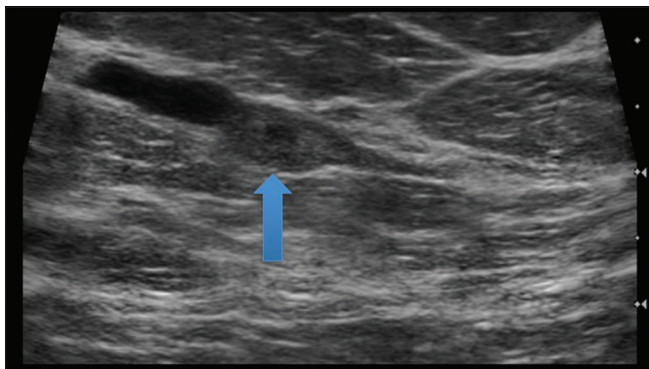
Tubular adenomas can appear very similar to fibroadenomas on imaging, presenting as oval, hypoechoic solid masses, and in fact are closely related pathologically. Tubular adenomas have small, tightly packed glandular elements (acini and tubular elements), with uniform tubules which are lined by single-layer epithelial cells. There are



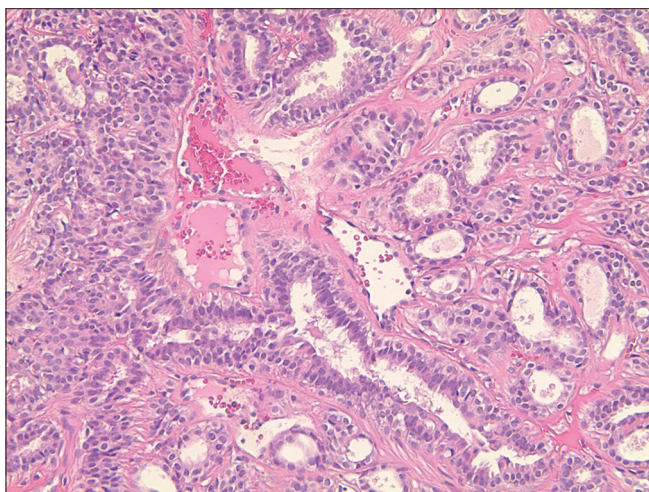
**Figure 1:** Diagnostic craniocaudal left mammographic view demonstrating an area of tubular densities compatible with dilated ducts within the outer breast (arrow)



**Figure 2:** Targeted left breast ultrasound demonstrating a 10 mm hypoechoic solid mass within a dilated duct. No appreciable internal blood flow was detected on color Doppler



**Figure 3:** Sonographic image confirming intraductal location of the mass (arrow); the walls of the duct surround the mass and are expanded by it, with the adjacent duct segment demonstrating dilatation due to the obstructive nature of the mass



**Figure 4:** Hematoxylin and eosin stain demonstrating scant stroma with tightly packed, uniform tubules lined by single-layer epithelial cells

minimal myoepithelial cells and scant stroma [Figure 4]. Fibroadenomas have abundant stroma and large glandular elements and ducts. Additional considerations include other solid masses as well as ductal carcinoma *in situ* or malignancy, particularly in cases where indeterminate microcalcifications are observed. In the setting of an intraductal mass – as in our case – considerations include intraductal debris or clot (particularly if Doppler examination fails to demonstrate internal vascularity), or intraductal neoplasms such as papillomas or papillocarcinomas. Given our patient's increased nipple discharge, new imaging findings, and the suggestion of ductal obstruction, foremost consideration was given to an intraductal neoplasm, with debris/clot felt to be less likely. Tissue sampling was necessary given the concern for neoplasm and possible malignancy.

Tissue sampling, typically accomplished by ultrasound-guided biopsy, is necessary for the diagnosis of tubular adenomas, and is usually prompted in the clinical setting of a new or enlarging solid breast mass. In a case where typical imaging features and classic histology are present with radiologic–pathologic concordance, one could argue against surgical excision of this benign lesion. At present, however, surgical excision remains the treatment of choice in order to establish a definitive diagnosis. Broadening the range of accepted imaging patterns of tubular adenomas to include intraductal masses may assist in cases where radiologic–pathologic concordance is questioned or nonsurgical management is being sought.

Outcome is excellent in this benign breast lesion. Instances of *in situ* or invasive malignancy arising within tubular adenomas have been reported in the literature, however, are very rare.<sup>[3]</sup> Short-term or annual follow-up with mammography and/or ultrasound, as well as continued patient surveillance for new symptoms or palpable masses, is recommended.

Considering the uniqueness of the presentation of tubular adenoma of the breast in our case, adaptation of the management approach and treatment recommendation were necessary. In an instance where novel diagnostic features of an entity are encountered, a conversation with the pathologist can be helpful in determining the presence or absence of typical pathologic features and the overall diagnostic confidence. Furthermore, the surgeon should be privy to these conversations because surgical approach may be influenced (e.g., acceptable closer margins).

#### Learning points

- Tubular adenoma is a benign breast lesion usually presenting as a solid, palpable mass in a young woman which may be confused with a fibroadenoma on imaging examinations

- Although a “typical” presentation is known, tubular adenomas have been shown to present with a variety of features. However, there is limited available information within the literature
- To our knowledge, ours is the first case of a tubular adenoma presenting as an intraductal mass. This report should assist in future cases of tubular adenomas and in accurate radiologic–pathologic correlation post-biopsy
- Surgical consultation is the recommended treatment for these benign lesions in order to establish a definitive diagnosis. Increasing presurgical diagnostic confidence would be helpful in cases where nonoperative management is being sought.

**Financial support and sponsorship**

Nil.

**Conflicts of interest**

There are no conflicts of interest.

**Suzanne M Smith Iorfido, Mahendra Shah<sup>1</sup>,  
S Yasir Zaidi<sup>2</sup>, Stephen Iorfido<sup>3</sup>**

Department of Diagnostic Radiology, Detroit Medical Centre, Wayne State University, <sup>1</sup>Diagnostic Radiologist and Breast Imager, <sup>2</sup>Department of Pathology, Detroit Medical Center, Sinai Grace Hospital, <sup>3</sup>Diagnostic Radiology Resident, Detroit Medical Center, Huron Valley Sinai Hospital, Detroit, Michigan, USA  
E-mail: suzsmith422@gmail.com

**References**

1. Soo MS, Dash N, Bentley R, Lee LH, Nanthan G. Tubular adenoma of the breast: Imaging findings with histologic correlation. *AJR Am J Roentgenol* 2000;174:757-61.
2. Salemis N, Gemenetz G, Karagkiouzis G, Seretis C, Sapounas K, Tsantilas V, *et al.* Tubular adenoma of the breast: A rare presentation and review of the literature. *J Clin Med Res* 2014;4:64-7.
3. Saimura M, Anan K, Mitsuyama S, Ono M, Toyoshima S. Ductal carcinoma *in situ* arising in tubular adenoma of the breast. *Breast Cancer* 2015;22:428-31.

This is an open access article distributed under the terms of the Creative Commons Attribution-NonCommercial-ShareAlike 3.0 License, which allows others to remix, tweak, and build upon the work non-commercially, as long as the author is credited and the new creations are licensed under the identical terms.

Access this article online	
<b>Quick Response Code:</b>	<b>Website:</b> www.ijri.org
	<b>DOI:</b> 10.4103/0971-3026.202958

**Cite this article as:** Smith Iorfido SM, Shah M, Zaidi SY, Iorfido S. A novel presentation of tubular adenoma of the breast as an intraductal mass: Diagnostic considerations and pathologic correlation. *Indian J Radiol Imaging* 2017;27:112-4.

© 2017 Indian Journal of Radiology and Imaging | Published by Wolters Kluwer - Medknow