

Mucormycosis in COVID Diabetic Patients: A Horrifying Triad!

Parshika Panwar¹, Anish Gupta², Amit Kumar³, Bhavna Gupta⁴, Shiv C Navriya⁵

ABSTRACT

Infectious diseases with the coronavirus disease-2019 (COVID-19) can be linked to various microbial and fungal coinfections. Mucormycosis is an invasive opportunistic infection that enters as inhalation of fungal spores through the nose or paranasal sinuses in diabetic and immunocompromised patients. We present our experience of managing seven cases of recent COVID-19 infection with uncontrolled diabetes who developed rhino-orbital mucormycosis. All patients were diagnosed by clinical examination and imaging and managed by emergency surgical debridement and liposomal amphotericin-B. A lethal triad of impaired immunity due to COVID-19 infection, state of hyperglycemia, increased use of steroids, or rampant broad-spectrum antimicrobials works as fertile soil and may assist in the growth or alleviation of a fungal infection. Healthcare professionals must be aware of the potential of secondary invasive fungal infections in diabetic patients with moderate to severe category of COVID-19 infectious disease, especially on steroid therapy.

Keywords: COVID, Diabetes mellitus, Hyperglycemia, Mucormycosis, Steroid.

Indian Journal of Critical Care Medicine (2021): 10.5005/jp-journals-10071-24025

INTRODUCTION

Coronavirus disease-2019 (COVID-19), caused by the novel severe acute respiratory syndrome coronavirus 2 (SARS-CoV-2) virus, can induce a range of symptoms that vary from minor to life-threatening pneumonia. Numerous bacterial and fungal coinfections can be caused by preexisting morbidities (diabetes and lung diseases) or develop as a hospital-acquired infection.¹ We present seven cases with known diabetes and recent moderate to severe COVID-19 infection who developed rhino-orbito-maxillary mucormycosis during their treatment for COVID-19 pneumonia.

CASE SERIES

We have described the seven cases with rhino-orbito-maxillary mucormycosis and COVID-19 infection, which we have come across in the last 2 weeks from May 1, 2021, to May 15, 2021, at our dedicated COVID tertiary care center. Demographic and clinical details of these cases are summarized in Table 1. All patients in our series had moderate to severe COVID pneumonia based on CT severity score and diabetes mellitus (DM) with uncontrolled blood sugars, five being the chronic diabetics and two recently diagnosed. Four patients were referred with features of mucormycosis and three developed evidence of sinusitis during their hospital stay for COVID treatment. Six patients had received broad-spectrum antibiotics, only three patients received steroids as per guidelines, and five patients who were managed in intensive care unit (ICU) were required oxygen support. Facial pain with swelling, eyelid edema, and nasal blockade were the commonly presented symptoms. Blood investigations revealed raised serum ferritin in two patients, HbA1c of >10 in two patients, and urine ketone positive without acidosis in one patient. All patients were diagnosed based on history, clinical examination, radiological imaging (Figs 1 to 4) and managed by a multidisciplinary team (consisting of ENT specialist, treating physician, critical care expert) approach. All patients underwent emergency surgical debridement (Figs 1 to 4), received intravenous amphotericin-B

¹Department of General Medicine, All India Institute of Medical Sciences, Rishikesh, Uttarakhand, India

²Department of CTVS, All India Institute of Medical Sciences, Rishikesh, Uttarakhand, India

³Department of ENT, All India Institute of Medical Sciences, Rishikesh, Uttarakhand, India

⁴Department of Anaesthesia, All India Institute of Medical Sciences, Rishikesh, Uttarakhand, India

⁵Department of Urology, All India Institute of Medical Sciences, Rishikesh, Uttarakhand, India

Corresponding Author: Shiv C Navriya, Department of Urology, All India Institute of Medical Sciences, Rishikesh, Uttarakhand, India, Phone: +91 9958365510, e-mail: drshivnavriya2004@gmail.com

How to cite this article: Panwar P, Gupta A, Kumar A, Gupta B, Navriya SC. Mucormycosis in COVID Diabetic Patients: A Horrifying Triad! *Indian J Crit Care Med* 2021;25(11):1314–1317.

Source of support: Nil

Conflict of interest: None

(5 mg/kg body weight), injection insulin for DM along with the care of COVID pneumonia. All patients were doing well in the first week of postoperative period.

DISCUSSION

The most common Mucorales of Zygomycetes class causing deadly fungal infection mucormycosis is *Rhizopus oryzae* belonging to Mucoraceae family can be found in soil and rotting organic matter like spoiled foods, leaves, compost piles, or rotten wood.² Paultauf described the mucormycosis first in 1885 and classified it into six types based on symptomatic presentation and site of involvement including rhino-orbito-cerebral, pulmonary, cutaneous, gastrointestinal, disseminated, and miscellaneous.³ Inhaling fungal spores from the air often affects the sinuses or lungs

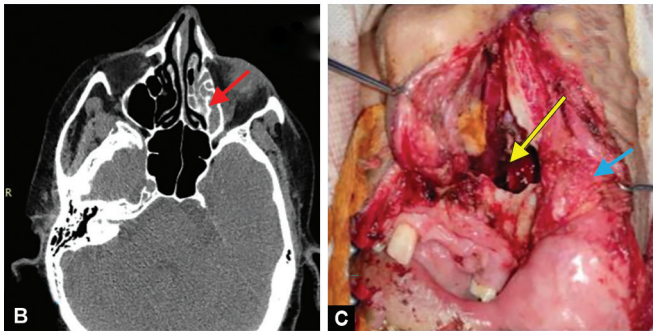
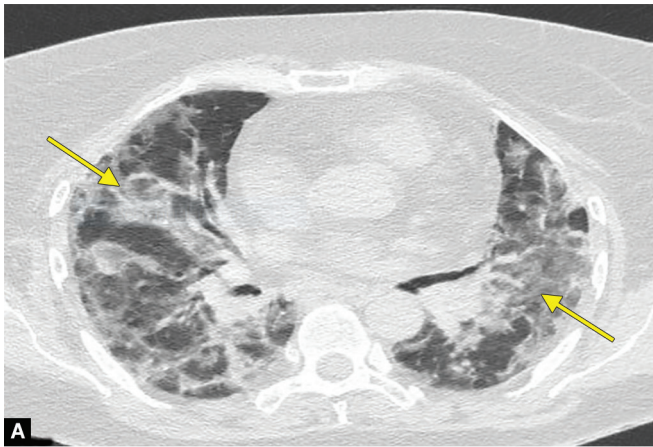
Table 1: Demography and clinical profile of COVID-associated mucormycosis cases

Parameter	Case 1	Case 2	Case 3	Case 4	Case 5	Case 6	Case 7
Age (in years)/sex	58/F	59/M	69/M	54/M	65/M	50/M	72/F
Presenting complaints	Left eyelid edema, ptosis, and eye prominence	Left-side facial heaviness, pain, and watering eyes	Right infraorbital facial swelling	Redness of right eye with decreased vision	Swelling of right eye with vision loss	Drooping right eyelid with right nasal obstruction	Altered mental status × 2 days
Day after COVID-positive	4	15	5	4	21	14	17
Severity of COVID	Moderate	Severe	Severe	Moderate	Moderate	Severe	Severe
Broad-spectrum antibiotics	Yes	Yes	No	Yes	No	Yes	Yes
Requirement of oxygen	Yes 6 L/minute	Yes, 8 L/minute	No	No	Yes, 8 L/minute	Yes, 12 L/minute	Yes, 15 L/minute
Experimental therapy	None	None	None	None	None	None	None
History of steroid use, dose, and duration	Dexamethasone 6 mg OD—3 days	Methyl prednisolone 16 mg BD—5 days	None	None	None	Methyl prednisolone 8 mg BD—5 days	None
Comorbidity	T2DM for 5 years	T2DM (Recent dx)	T2DM 8 years	T2DM	T2DM, HTN	T2DM (Recent dx)	T2DM
Blood sugars (at the time of admission)	370 mg/dL	405 mg/dL	403 mg/dL	310 mg/dL	234 mg/dL	219 mg/dL	312 mg/dL
Management of DM	Insulin	Insulin	Insulin	Insulin	Insulin	Insulin	Insulin
Other abnormal investigations	D-dimer 1.16 mg/L Urine ketone positive, no acidosis	CRP—52.45 mg/L, IL-6—45.75 pg/mL	Swab microscopy—filamentous fungi	Ferritin 731.8 HbA1c 13.2	HbA1c 10.7 D-dimer 1.23	HbA1c 11.2	Ferritin 4063
Imaging	CT PNS and brain	MRI PNS	CT PNS	CT PNS		CT PNS	
Antifungal agent	Liposomal amphotericin-B	Liposomal amphotericin-B	Liposomal amphotericin-B	Liposomal amphotericin-B	Liposomal amphotericin-B	Liposomal amphotericin-B	Liposomal amphotericin-B
Intervention	Left medial maxillectomy with debridement through lateral rhinotomy incision	left medial maxillectomy via Weber-Ferguson incision with lynch extension	Emergency surgical debridement	Right medial maxillectomy + right orbital decompression	Right medial maxillectomy + right orbital decompression	Right medial maxillectomy with debridement	Left total maxillectomy with orbital exenteration + tracheostomy
Outcome (in the first week of postoperative period)	Improved	Improved	Improved	Improved	Improved	Improved	Stable

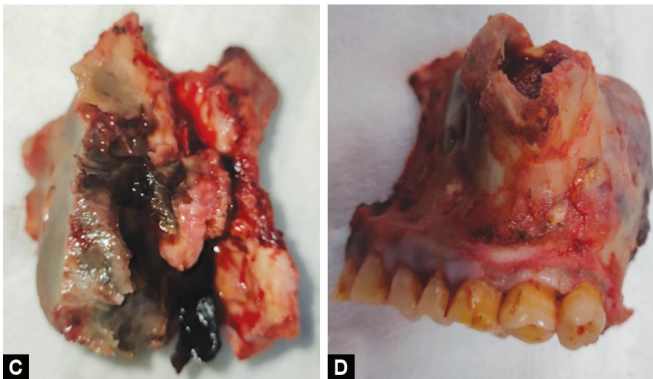
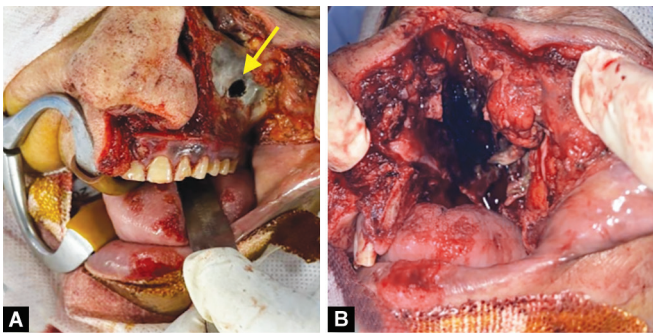
or allows the fungus to penetrate the skin through cuts, scrapes, burns, or other open wounds that may cause infection. Rhino-orbito-cerebral mucormycosis and pulmonary mucormycosis are the two common forms of COVID-19 associated mucormycosis.¹

Mucormycosis mainly affects people who have comorbidities or are taking medications that cause immunosuppression. COVID-19 is linked to a high rate of secondary infections, both bacterial and fungal, most likely due to immune dysregulation. COVID-19 infection is associated with reduced numbers of T lymphocytes, CD8+T and CD4+T cells, altered innate immunity predisposing to opportunistic invasive fungal infection.^{4,5} Mononuclear and polymorphonuclear phagocytes are the first line

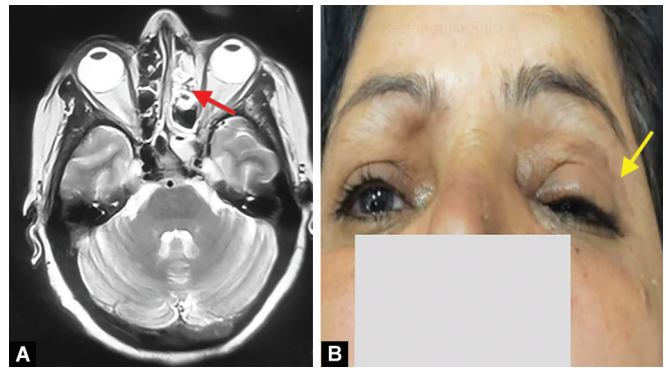
of defense preventing the inhaled spores of Mucorales invading into deeper tissues via producing oxidative metabolites and cationic peptide defensins.⁶ Steroids and hyperglycemia cause impairment in the ability of phagocytes responding to invading organisms resulting in impaired chemotaxis, dysfunctional phagocytes, and defective intracellular killing.⁷ Furthermore, it has been demonstrated that ketoacidosis associated with uncontrolled diabetes potentiates the mucormycosis by two mechanisms. Firstly, *Rhizopus arrhizus* produces the ketoreductase enzyme in diabetic patients, allowing to use ketone bodies of patient.⁸ Secondly studies have shown that Mucorales utilize iron for growth and ketoacidosis favors the release of iron from protein-bound form.^{2,9} Patients with



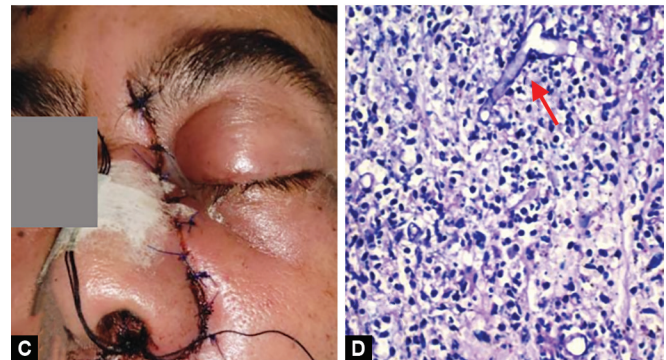
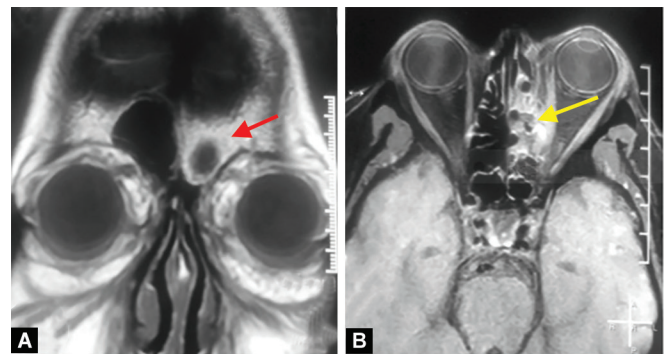
Figs 1A to C: (A) Axial CT image showing ground glass opacities in bilateral lung fields suggestive of COVID pneumonia; (B) Axial CT image showing obliteration of left maxillary ostiomeatal complex, maxillary, and ethmoid sinusitis with no bony erosion; (C) Intraoperative field images after debridement of unhealthy tissue with black discoloration (bold yellow arrow) and raised skin flaps for the procedure (bold blue arrow)



Figs 2A to D: (A) Intraoperative photograph showing maxillary sinus invaded by mucor, bold yellow arrow; (B) Photograph after debridement and removal of sinuses; (C) and (D) Specimen of total maxillectomy with dead necrotic tissue



Figs 3A and B: (A) MRI brain with orbit showing enhancing mucosal thickening with significant soft tissue edema involving left maxillary, ethmoidal, and sphenoid sinuses (bold red arrow) without the involvement of brain; (B) Clinical photograph showing edematous left cheek and eyelid, prominent left eye with chemosis



Figs 4A to D: (A) T2-weighted coronal magnetic resonance imaging showing obliteration of left maxillary sinus with surrounding soft tissue edema; (B) T2-weighted axial magnetic resonance imaging showing heterogeneous enhancement of ethmoid sinus suggestive of sinusitis; (C) Postoperative photograph showing incision line and approach; (D) Hematoxylin and eosin (H&E X400) photomicrograph showing broad nonseptate fungal hyphae, accompanied by numerous neutrophils and histiocytes in necroinflammatory background

impaired cellular or humoral immunity have inadequate defense leading to invasion by Mucorales in paranasal sinuses. Fungus further invades into deeper tissues and arteries causing thrombosis, ischemia, and necrosis. The widespread use of steroids, monoclonal antibodies, and broad-spectrum antibiotics as part of the COVID-19 armamentarium can result in the development or exacerbation of preexisting fungal diseases.⁴ Our experience highlights the significant association of uncontrolled blood sugars with the emergence of mucormycosis even in the absence of steroid therapy; similar findings were noted in recently published case series by

Sarkar et al. in which all patients were diabetic with raised blood sugars and all received steroids as per guidelines.¹⁰

Diagnosis and Management

High index of clinical suspicion and appropriate imaging of the involved part with CT or MRI is needed to diagnose mucormycosis. Definitive diagnosis almost always needs histopathological examination as microscopy, culture, or imaging has limitations.¹⁰ Unfortunately, delayed diagnosis in mucormycosis is associated with fatal outcomes. Management of mucormycosis includes timely diagnosis, emergency surgical debridement, correction of underlying predisposing factors, and antifungal agents. European Confederation of Medical Mycology (ECMM) group has developed the global guidelines for the management of mucormycosis and recommends urgent medical and surgical intervention in suspected or confirmed cases because of the progressive nature of the infection. For medical management intravenous liposomal amphotericin-B is recommended as first line therapy, intravenous isavuconazole, and oral or intravenous posaconazole is preferred if first-line therapy is contraindicated or not responding.¹¹

Recently Indian council of Medical Research (ICMR) also issued evidence-based advisory regarding the emergence of mucormycosis with COVID-19. It recommends a multidisciplinary team approach with extensive surgical debridement, control of blood sugars and ketoacidosis, aim to discontinue steroid rapidly, antifungal therapy with intravenous liposomal amphotericin-B 5–10 mg/kg body weight without slow escalation and adequate hydration.¹²

Remedies for Prevention

The increase in mucormycosis among COVID-19 patients is due to poorly controlled blood sugars and immune dysregulation. Steroid use may potentiate both these predisposing factors so it should be used sparingly in COVID-19 therapy as per standard protocols.^{4,5,12} In our series also uncontrolled blood sugar was the most important factor leading to the development of mucormycosis. The inclusion of any medication entails an additional responsibility to comprehend its impact on the unanticipated adverse sequel. While receiving steroid treatment, it is imperative to strictly control blood sugars on insulin as continuing the patients on OHA (particularly biguanides) may add to metabolic insult by being unpredictable and having lactic acidotic potential.¹³ If the COVID-19 patient is on oxygen assistance, the humidifier for oxygen therapy should be filled with distilled water, fill up to about 10 mm below the maximum fill line, should be changed daily and the humidifier should be washed in mild soapy water, dried in air before reuse.¹⁴

The COVID-19 patient's overall cleanliness should be preserved; any fresh complaints especially facial pain, swelling or numbness, orbital pain or swelling, blurred or double vision must be acknowledged and evaluated as soon as possible. In presence of warning sign or symptoms, should not hesitate to get early aggressive investigations. Patients are instructed to wear mask and to cover body part with proper clothes at the time of discharge; they should be educated regarding early signs and symptoms of mucormycosis.¹⁴ There should be no time lag between discussion and decision!

- Diabetic status: strict control
- Dose and duration of steroids: Strike hard (in crisis) and wean quickly (till crisis)
- De-escalation of the scenario (steroid stewardship)
- Device's cleanliness care (indwelling catheters, central line, or any dressing or humidifiers are often the nidus of infection).

CONCLUSION

Physicians should be aware of the possibility of invasive secondary fungal infections in patients with COVID-19 infection, especially in poorly controlled diabetics. The use of therapeutic agents including steroids and antibiotics should be closely controlled to achieve the best possible therapeutic result at the lowest possible dosage and for the shortest possible time. Timely detection of invasive fungal infection and treatment with antifungal agents as well as operative intervention can reduce the mortality and morbidity.

ORCID

Parshika Panwar  <https://orcid.org/0000-0003-0582-5426>

Anish Gupta  <https://orcid.org/0000-0002-4704-6271>

Amit Kumar  <https://orcid.org/0000-0002-6491-5010>

Bhavna Gupta  <https://orcid.org/0000-0002-3108-0408>

Shiv C Navriya  <https://orcid.org/0000-0003-4859-3979>

REFERENCES

1. Mehta S, Pandey A. Rhino-orbital mucormycosis associated with COVID-19. *Cureus* 2020;12(9):e10726. DOI: 10.7759/cureus.10726.
2. Bouza E, Muñoz P, Guinea J. Mucormycosis: an emerging disease? *Clin Microbiol Infect* 2006;12(7):7–23. DOI: 10.1111/j.1469-0691.2006.01604.x.
3. Viterbo S, Fasolis M, Garzino-Demo P, Griffa A, Boffano P, Iaquineta C, et al. Management and outcomes of three cases of rhinocerebral mucormycosis. *Oral Surg Oral Med Oral Pathol Oral Radiol Endod* 2011;112(6):e69–e74. DOI: 10.1016/j.tripleo.2011.04.048.
4. Garg D, Muthu V, Sehgal IS, Ramachandran R, Kaur H, Bhalla A, et al. Coronavirus disease (Covid-19) associated mucormycosis (CAM): case report and systematic review of literature. *Mycopathologia* 2021;186(2):289–298. DOI: 10.1007/s11046-021-00528-2.
5. Gangneux JP, Bougnoux ME, Dannaoui E, Cornet M, Zahar JR. Invasive fungal diseases during COVID-19: we should be prepared. *J Mycol Med* 2020;30(2):100971. DOI: 10.1016/j.mycmed.2020.100971.
6. Waldorf AR. Pulmonary defense mechanisms against opportunistic fungal pathogens. *Immunol Ser* 1989;47:243–271. PMID: 2490078.
7. Chinn RY, Diamond RD. Generation of chemotactic factors by *Rhizopus oryzae* in the presence and absence of serum: relationship to hyphal damage mediated by human neutrophils and effects of hyperglycemia and ketoacidosis. *Infect Immun* 1982;38(3):1123–1129. DOI: 10.1128/iai.38.3.1123-1129.1982.
8. Pandey A, Bansal V, Asthana AK, Trivedi V, Madan M, Das A. Maxillary osteomyelitis by mucormycosis: report of four cases. *Int J Infect Dis* 2011;15(1):e66–e69. DOI: 10.1016/j.ijid.2010.09.003.
9. Spellberg B, Edwards J Jr, Ibrahim A. Novel perspectives on mucormycosis: pathophysiology, presentation, and management. *Clin Microbiol Rev* 2005;18(3):556–569. DOI: 10.1128/CMR.18.3.556-569.2005.
10. Sarkar S, Gokhale T, Choudhury SS, Deb AK. COVID-19 and orbital mucormycosis. *Indian J Ophthalmol* 2021;69(4):1002–1004. DOI: 10.4103/ijo.IJO_3763_20.
11. Global guideline for the diagnosis and management of mucormycosis: an initiative of the European Confederation of Medical Mycology in cooperation with the Mycoses Study Group Education and Research Consortium. *Lancet Infect Dis* 2019;19(12):e405–e421. DOI: 10.1016/S1473-3099(19)30312-3.
12. RECOVERY Collaborative Group, Horby P, Lim WS, Emberson JR, Mafham M, Bell JL, et al. Dexamethasone in hospitalized patients with Covid-19. *N Engl J Med* 2021;384(8):693–704. DOI: 10.1056/NEJMoa2021436.
13. https://www.mohfw.gov.in/pdf/Clinical_Guidance_on_Diabetes_Management_at_COVID19_patient_Management_Facility.pdf.
14. https://www.icmr.gov.in/pdf/covid/techdoc/Mucormycosis_ADVISORY_FROM_ICMR_In_COVID19_time.pdf.