

Contents lists available at [ScienceDirect](http://www.elsevier.com/locate/TJEM)

Turkish Journal of Emergency Medicine

journal homepage: <http://www.elsevier.com/locate/TJEM>

Typical pericarditis ECG findings after falling from height. The PR segment depression or ST segment elevation?

Murat Sucu, MD ^{*}, Gokhan Altunbas, MD, Fatma Yilmaz Coskun, MD

Gaziantep University, Department of Cardiology, Gaziantep, Turkey

ARTICLE INFO

Article history:

Received 7 March 2017

Received in revised form

29 April 2017

Accepted 16 May 2017

Available online 26 May 2017

Keywords:

ECG

Pericarditis

Trauma

ABSTRACT

Acute pericarditis (AP) following blunt thoracic trauma is rare and difficult to diagnosis. A 43-year-old man with offered to the emergency department (ED) after falling from height before a week ago. The ECG performed in the ED was abnormal, ECG revealed PR segment depression in leads DII, DIII, aVF, and V3-6 and a preliminary diagnosis of acute inferolateral STEMI was presumed. Patients have evidence of systemic inflammation, including leukocytosis, elevated erythrocyte sedimentation rate. We are reporting a case of post-traumatic acute pericarditis presenting with PR-segment depression and normal cardiac enzymes mimicking acute STEMI.

Copyright © 2017 The Emergency Medicine Association of Turkey. Production and hosting by Elsevier B.V. on behalf of the Owner. This is an open access article under the CC BY-NC-ND license (<http://creativecommons.org/licenses/by-nc-nd/4.0/>).

1. Introduction

Blunt chest trauma can result in severe injuries to the all of the intrathoracic organs. Acute pericarditis (AP) following blunt thoracic trauma is rare and difficult to diagnosis. AP is the most common disorder of the pericardium. AP may manifest following trauma to the pericardium or after iatrogenic causes.¹ AP has a rare clinical presentation, physical findings, and ECG changes. AP has been noted to occur in as many as 22% of patients after penetrating cardiac injury but has also been reported after blunt thorax injury.² The ECG patterns in AP follow a typical evolution as the disease progresses from the acute inflammatory phase through resolution. The duration of ECG abnormalities varies with the different etiologies and may proceed from 1 week to months.³ The 12-lead electrocardiogram (ECG), acquired by the clinician for the suspicion for acute coronary syndrome, must be viewed according to the clinical situation. The ECG is not the diagnostic test of choice for evaluating a patient with traumatic heart injury.

2. Case report

A 43-year-old man with offered to the emergency department (ED) after falling from height before a week ago. The pneumothorax, a mediastinal shift, lung collapse and pleural effusion was not observed in the on the posterior-anterior chest radiograph. The ECG performed in the ED revealed PR segment depression in leads DII, DIII, aVF, and V3-6 derivations (Fig. 1) and a preliminary diagnosis of acute inferolateral ST-Elevation Myocardial Infarction (STEMI) was presumed. Results of laboratory tests were as follows; WBC: 14.700, sedimentation first hour 80, the first cardiac enzymes were normal; Creatin Kinase 50 U/L (normal value 20–200 U/L), CKMB 30 U/L (normal value 0–25 U/L) and Troponin T High Sensitivity <0.004 ng/ml (normal value < 0.04 ng/ml). Apart from signs of inflammation, laboratory investigations were otherwise normal. Upon transfer, to the intensive care unit, the patient complained of chest pain, which was presumed to be due to musculoskeletal system trauma. He had no history of cardiovascular disorders, hypertension, dyslipidemia, and positive family history of coronary artery disease. There was a history of diabetes mellitus and smoking. Blood pressure was 110/70 mmHg, pulse 120 beats/min, and temperature 37.8 °C. Cardiac examination was normal. There was no pericardial rub. The transthoracic echocardiographic examination showed a normal biventricular systolic function without any myocardial segmental wall motion abnormalities and pericardial effusion. The patient was then taken to the cardiac angiography

^{*} Corresponding author.

E-mail address: sucu@gantep.edu.tr (M. Sucu).

Peer review under responsibility of The Emergency Medicine Association of Turkey.

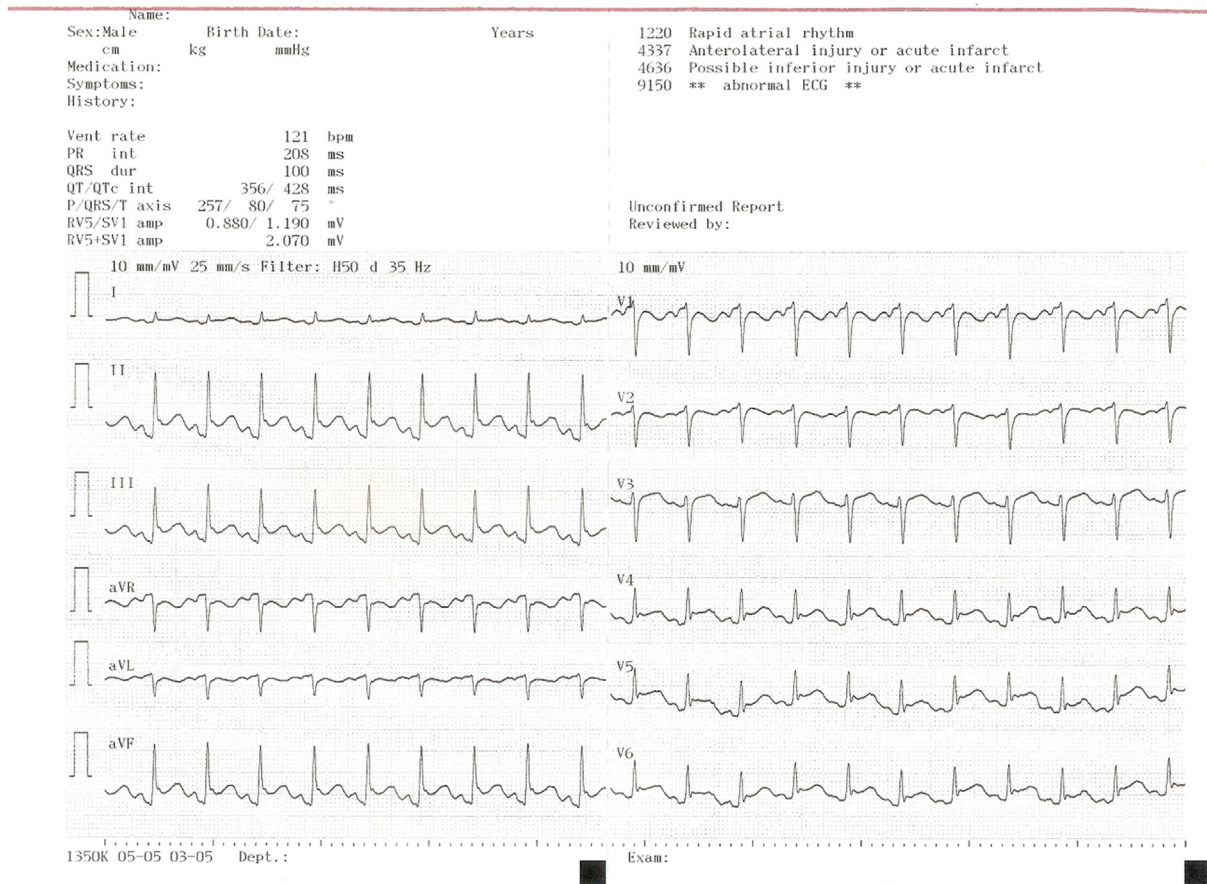


Fig. 1. Acute pericarditis with diffuse PR-segment depression and concave upwards ST-segment elevation (except V1 and aVR derivations where PR-elevation is noted). PR-depression and ST-segment elevation with downward sloping TP-segment (Spodick's sign).

laboratory, which showed normal coronary arteries with the normal coronary flow. He was transferred to the cardiology clinic.

3. Discussion

The ECG results were AP, myocardial contusion, stress cardiomyopathy, pneumothorax, intracranial hemorrhage, pulmonary embolism, aortic dissection, a left ventricular aneurysm, hyperkalemia, or benign early repolarization(4). The ST-segment elevation with pneumothorax might be the acute increase in right-sided cardiac pressures caused by elevated pulmonary vascular resistance related to the collapsed lung, leading to right ventricular pressure overload, ischemia, and injury.⁴ Our patient's lung was not collapsed and pneumothorax. Blood potassium level was normal. Furthermore, electrocardiography excluded of early repolarization. The left ventricular aneurysm was eliminated by echocardiographic examination and there were not Q waves on the ECG. Incorrect interpretation of the ECG may also affect the rate of missed acute ST-segment elevation myocardial infarction (STEMI) in the ED. The ECG is being used blunt trauma patients with chest pain. In the emergency setting, it is not always easy to differentiate AP from acute STEMI based on ECG findings.⁵ Surawicz et al. described ST-segment elevation in 90% of patients in their patients who had proven AP and they described ST-segment depression in aVR and V1 derivations.⁶ The most common pattern involved ST-segment elevation in derivations DI, DII, and V5–V6, which was present in 70% of patients. More involvement that is extensive indicated by

the additional ST-segment elevation in DIII, aVL, aVF, and V3–V4 derivations were not uncommon. However, in addition to ST-segment elevation, ST-segment depression may be present. The PR-segment depression is observed later after the ST-segment returns to baseline and could be of help in the differential diagnosis of ST-segment changes due to bundle branch block, acute STEMI or left ventricular hypertrophy. In patients with AP, PR depression can be accepted as a sign of inflammation of the pericardium.⁷ The major differences of ECG changes in patients with AP and acute STEMI are as follows⁸;

1. ST-segment elevation in AP is classically diffuse except aVR and V1 derivations and is characteristically concave upwards without reciprocal changes differentiating it from ischemic changes.
2. ST-segment elevation in AP is generally ≤ 5 mm, but in STEMI ST-elevation is ≥ 2 mm in two contiguous derivations.
3. In the acute phase of the AP, the changes develop gradually which shows spread of the inflammation of various parts of the pericardium. AP causes ST-segment elevation in both the limb and precordial derivations, differentiating it from characteristic regional changes in STEMI.
4. The ratio of the height of the ST-segment junction to the height of the apex of the T wave of more than 0.25 in DI, V4, V5 and V6 derivations.
5. Pathologic Q waves or atrioventricular block is seen in acute STEMI.

6. The atrial tissue injury is present with AP which is seen on ECG as PR-segment elevation in aVR derivation and PR-segment depression in other derivations.⁹
7. A down-sloping TP-segment (Spodick's sign) in patients with AP and this sign is best seen in DII and lateral precordial derivations. The Spodick's sign may an important distinguishing electrocardiographic tool between the AP and acute STEMI.¹⁰
8. The ECG of acute STEMI shows prolonged QRS duration and shortened QT-interval in leads with ST-segment elevation.¹¹

The patient's ECG demonstrated PR-segment depression in addition to ST-segment elevation, further supporting the diagnosis of AP. This case shows that PR-segment depressions are frequent in the AP and that careful evaluation of the PR segment is a helpful means for patients presenting with ST-segment elevations in the ED.

4. Conclusion

The PR-segment depression is a frequent ECG change associated with acute pericarditis. We are reporting a case of post-traumatic acute pericarditis presenting with PR-segment depression and normal cardiac enzymes mimicking acute STEMI. A rapid and accurate diagnosis and the decision is critical on account of providing appropriate management and avoid unneeded and harmful therapies.

Funding

None declared.

Conflict of interest

None declared.

References

1. Spodick DH. Pericardial diseases. In: Braunwald E, Zipes DP, Libby P, eds. *Heart Disease: A Textbook of Cardiovascular Medicine*. sixth ed. Philadelphia: WB Saunders; 2001:1823–1876.
2. Wiegand L, Zwillich CW. The post-cardiac injury syndrome following blunt chest trauma: case report. *J Trauma*. 1993;34:445–447.
3. Surawicz B, Knilans T. Pericarditis and cardiac surgery. In: Surawicz B, Knilans T, eds. *Chou's Electrocardiography in Clinical Practice*. Philadelphia: WB Saunders; 2001:239–255.
4. Rechenmacher Stephen, Jurewitz Daniel, Southard Jeffrey, Amsterdam Ezra. Barking up the wrong tree: regional pericarditis mimicking STEMI. *Am J Med*. 2013;126(8):679–681.
5. Imazio Massimo, Demichelis Brunella, Cecchi Enrico, et al. Cardiac troponin i in acute pericarditis. *J Am Coll Cardiol*. 2003;42(12):2144–2148.
6. Surawicz B, Lassiter KC. Electrocardiogram in pericarditis. *Am J Cardiol*. 1970;26:471–474.
7. Kudo Yoshihiro, Yamasaki Fumiyasu, Doi Yoshinori, Sugiura Tetsuro. Clinical correlates of pr-segment depression in asymptomatic patients with pericardial effusion. *J Am Coll Cardiol*. 2002;39(12):2000–2004.
8. Alraies MC, Klein ALQ. Should we still use electrocardiography to diagnose pericardial disease? *Cleve Clin J Med*. 2013;80:97–100.
9. Porela Pekka, Kytö Ville, Nikus Kjell, Eskola Markku, Airaksinen KEJ. PR depression is useful in the differential diagnosis of myopericarditis and ST elevation myocardial infarction. *Ann Noninvasive Electrocardiol*. 2012;17(2):141–145.
10. Makaryus JN, Makaryus AN, Boal B. Spodick's sign. *Am J Med*. 2008;121:693–694.
11. Rossello Xavier, Wiegerinck Rob F, Alguersuari Joan, et al. New electrocardiographic criteria to differentiate acute pericarditis and myocardial infarction. *Am J Med*. 2014;127(3):233–239.