

R E V I E W

The Use of Orthopedic Surgical Implants for Forensic Identification: An Overview

Abrar Hasan Bukhamseen, Abrar Ali Aldhameen, Nouf Tareq Alzayat, Maria Mahdi Alqadeeb, Bashair Khalid Alotaibi, Raghad Ibrahim Aljohani, Ritesh G. Menezes

College of Medicine, King Fahd Hospital of the University, Imam Abdulrahman Bin Faisal University, Dammam, Saudi Arabia

Abstract. *Background and aim:* Identification of human bodies is a necessary step in forensic practice. DNA analysis, fingerprints, and dental charting are considered conventional identification methods. However, these methods are not always applicable. Orthopedic surgical implantable devices provide valuable identity information when conventional methods of identification are not applicable or in challenging circumstances. This paper aims to review the usage of orthopedic implantable devices for forensic human identification. *Methods:* A search for relevant articles using the PubMed database in January 2021 identified 8 articles that met the inclusion criteria. *Results:* These articles highlighted the importance of the use of orthopedic implantable devices as an additional method for positive identification, especially in disaster situations. It is a method that needs antemortem and postmortem radiographs, comprehensive information of the orthopedic implantable device like company and serial number, logo, name, medical records of previous surgical intervention, and for the family member's history to match with the identification details. *Conclusions:* Efforts should be made to include all information pertaining to orthopedic implantable devices in the medical records. Educating and training forensic experts on the use of such devices in the identification process is essential, as this technique is practical, low-cost, and time-saving. (www.actabiomedica.it)

Key words: forensic identification, orthopedic implantable device, disaster victim identification, postmortem radiograph

Introduction

Human identification is of paramount importance in forensic practice. Postmortem identification is significant in any death investigation involving unidentified bodies, dismembered body parts, or skeletal remains. In a decomposed or skeletonized corpse, visual identity is compromised. The use of fingerprints, dental charting, and DNA analysis and profiling are established methods employed in forensic human identification (1,2).

However, concerning disaster victim identification or cases of excessive thermal alteration, the conventional methods of identification may be challenging and not always applicable. Thus, prosthetic artifacts are one of the most critical tools in establishing the identity due

to their components that can survive these circumstances compared to organic tissue (3,4). Artificial surgical implants recovered from skeletal remains usually contain information that helps in the identification process where prior knowledge about the remains lacks. The serial and lot numbers on the implanted devices can identify the manufacturers, distributors, or hospitals (5).

For example, Simpson et al. demonstrated the utility of such devices in the identification process through their audit of files archived at Forensic Science SA in Adelaide, South Australia (6). In three circumstances, the identification came from the use of antemortem and postmortem radiograph comparisons, not through the device's actual tracking. The use of radiographs for identification requires having a presupposition of the victim's identity (a closed population) (6). Matoso et

al. also clarified the importance of documentation of the orthopedic implant device's information (serial number and company name) in a burned human body. The company clearly detailed the following tracking information: patient's name; date of surgery; type of surgical procedure and operated body part; address of the hospital where the surgery was performed; surgeon's name; description and identification details of the device (7). Blessing and Lin illustrated the significance of identifying bodies by using the orthopedic implant device serial number (8). By comparing the serial number on the implanted device with that documented in hospital records a positive identification was achieved in several cases where visual identification of the deceased was not possible (8).

As this paper discusses, orthopedic implants can also provide variable and valuable information that helps the investigation. In recent times, it is not uncommon to find skeletal remains with surgically implanted orthopedic devices (9). Hence, a forensic expert needs to be aware of the different varieties of orthopedic implants and the means of using the serial numbers on such devices for the purpose of identifying the deceased. Herein, this study aims to review the literature on the use of orthopedic surgical devices for forensic identification.

Methods

We conducted a systematic literature search to identify articles that reported the use of orthopedic implantable devices in the positive forensic identification of decedents. The related search was conducted on January 26, 2021, using the PubMed search engine. The string of relevant keywords used in the literature search is presented in Table 1. The resulting records were screened in accordance with the PRISMA guidelines (Figure 1). Only articles published in English that met the inclusion criteria were included. Review articles and articles with limited view text were excluded. Articles that discussed the usage of cardiac conduction devices, dental implants, and cochlear implants in the identification of decedents were also excluded.

Table 1. The search strategy

Database	PubMed
Date of search	January 26, 2021
Search terms	(orthopedic implant OR orthopedic bone plate OR orthopedic device OR surgical implant OR surgical device OR orthopedic prosthetic implant OR prosthetic implant OR prosthetic device OR implanted medical device) AND (forensic identification OR cremation identification OR disaster victim identification OR positive identification OR human remains identification OR skeletal remains identification)
Search results	1350
Included items/articles	8

Results and discussion

Out of 1350 records that were initially screened, a total of 8 articles met the inclusion criteria. These articles (Table 2) reported various circumstances in which the presence of orthopedic surgical implant devices played a major role in the forensic identification process of the deceased (5-8,10-13).

Using orthopedic surgical implants, whenever applicable, can be an efficient, time-saving, and low-cost approach in identifying bodies when compared to higher cost and time-consuming methods such as DNA profiling (7).

Implantable orthopedic devices found in unidentified dead bodies can be used to provide valuable information pertaining to personal identification (Table 3). For example, the conclusion that the victim had access to the means necessary for the major surgery, which in specific demography may be applicable to narrow down the search. A case was reported in India where the remains of a human skeleton were found in a forest, and the information about the sex and age of the deceased was limited (10). There was evidence of surgical correction of the left femoral intertrochanteric fracture by a dynamic hip screw assembly. The metal plate had a serial number and showed a marking that represented a manufacturer's name. The manufacturer supplied the device to a particular rural district of central India, in which major orthopedic surgeries such

as the one mentioned in the present case were only performed in a few hospitals. The police narrowed down the search to three major hospitals where three surgeries were performed with orthopedic plates with the same serial number. Contact details were retrieved and two of the patients were alive and the son of the third reported that his father had dementia and had been missing for a month. Identification was achieved by tracking the plate serial number, and some remains of the skeleton were obtained for further DNA confirmation (10). The presence of orthopedic devices may give a hint of the age of the victim, based on the device type and the region where the device is found im-

planted. For instance, hip fractures are more common in the older population. Furthermore, a comparison of antemortem and postmortem radiography can be used if a previous presumption of the victim's identity already exists (7). A study was conducted by Simpson et al. where the archives of Forensic Science SA in Adelaide, South Australia, were investigated for cases in which the deceased's recognition was limited by skeletonization, decomposition, incineration process, or by the discovery of broken, incomplete skeletons (6). In 8 cases, the bones' radiographic examination was done, looking for any distinctive features that could help in the identification of human remains. Out of 8, 6 were

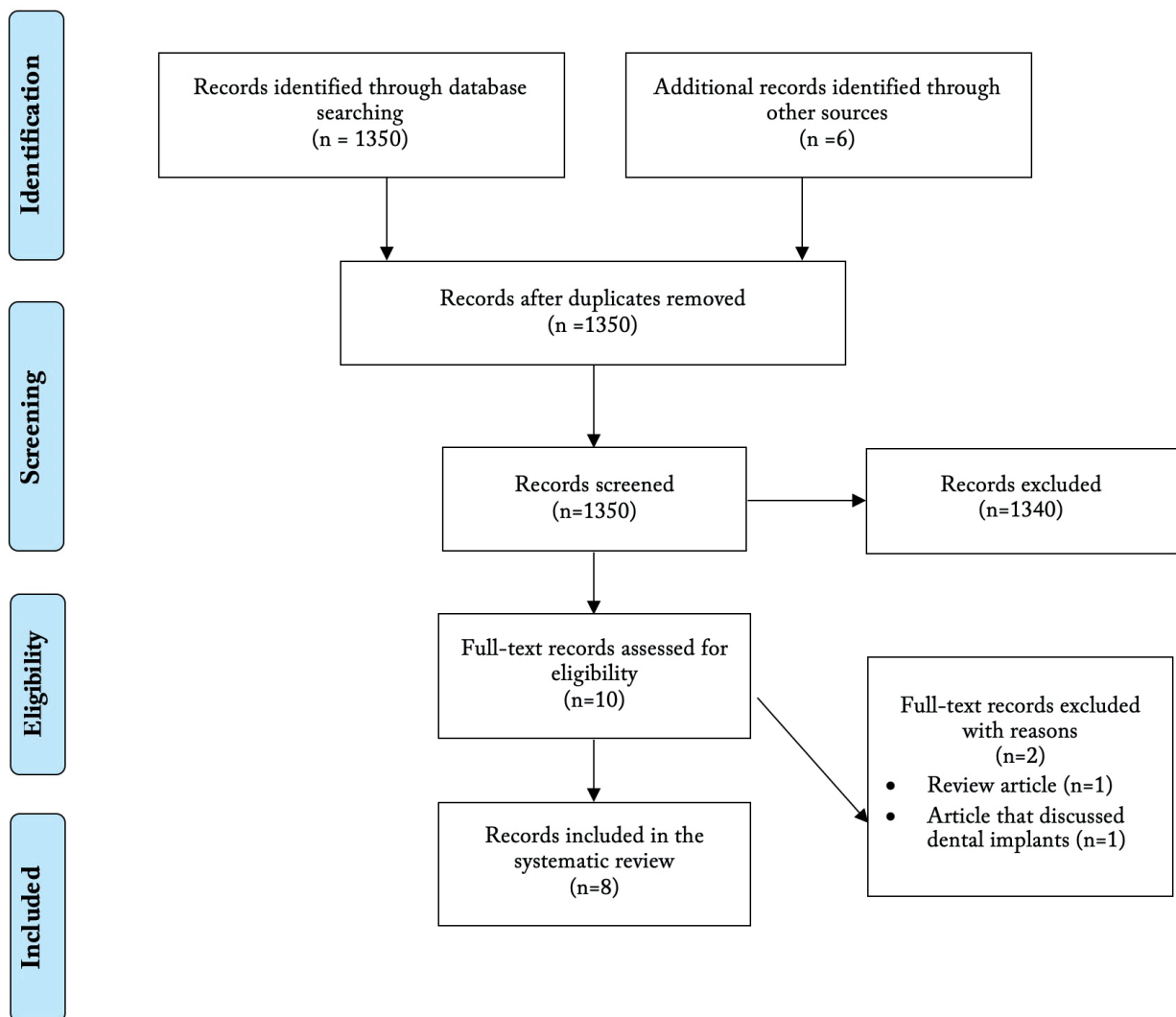


Figure 1. PRISMA flowchart (<http://www.prisma-statement.org/>) depicting the selection of articles

Table 2. The use orthopedic implanted device for forensic identification

Country	Publication year	Situation	Cases with orthopedic implanted devices	Identification among the cases with orthopedic implanted devices	Orthopedic devices used in identification	Reference
USA	1999	Burned body	1	Positive	Osteostimulator	(11)
Australia	2003	Burned body	1	Positive	Metal plate containing three screws	(12)
Australia	2007	Incinerated body, Skeletal remains, Skeletonized body, Bone fragments	5	3 cases with positive identification	<ul style="list-style-type: none"> • Right hip prosthesis • Two metal Harrington rods connecting vertebrae • Orthopedic plate fixed to the left ulna • Fragment of ulna with a metal plate • Fragment of humerus with a metal plate 	(6)
Japan	2017	2011 East-Japan earthquake and tsunami victims	8	2 cases with positive identification	<ul style="list-style-type: none"> • Intramedullary nail system for the tibia • Cortical bone screw (46-mm long) • Bilateral artificial knee joints • Bipolar cup of an artificial hip joint • Femoral stem • Plate system for the radius • Bilateral artificial hip joints • Nail system for the humerus 	(13)
Brazil	2013	Burned body	1	Positive	Orthopedic device surgically fixed in the left ulna by 6 screws	(7)
Japan	2014	Decomposed body	1	Positive	• Intramedullary nail in the right femur	(5)
USA	2018	Decomposed bodies, Extensive blunt facial trauma victims	7	4 cases with positive identification	<ul style="list-style-type: none"> • Prosthetic shoulder joint (n = 2) • Prosthetic knee joint (n = 2) • Ankle (malleolar) fixation plate • Intramedullary femoral rod • Clavicle fixation plate 	(8)
India	2021	Skeletal remains	1	Positive	Dynamic hip screw assembly with a side plate and 5 cortical screws	(10)

Table 3. List of the advantages of orthopedic surgical implant devices for forensic identification

The means of orthopedic surgical implant devices usage for forensic identification	Reference
Clues to the identification of circumstances of injury or disease for which the implant was used	(5, 10)
The implication of a specific demography of the deceased	(10)
The implication of the age of the deceased	(10)
A comparison of antemortem and postmortem radiography for previously presumed victim	(6,7)
The serial number in the implants and further tracking	(8)

found to have antemortem records. However, in the remaining 2 cases, no antemortem records were available. Only 5 cases had orthopedic implanted devices. A postmortem radiograph was taken and compared to antemortem radiographs of the suspected deceased individual aiding in identification in 3 cases(6).

The serial number in the orthopedic implants also plays an essential role in identification. A retrospective study was done in the USA to assess the practicality of using serial numbers on implanted medical devices in identification. 608 forensic autopsy records were reviewed. 56 out of 608 required a different method of identification due to decomposition, contact gunshot wound of the face, extensive blunt traumatic injuries of the face, or charring of the face. 8 out of 56 had known implanted medical devices, in which 4 were identified by using the serial number on the devices (8).

There are various causes of death worldwide, and some of which can result in unidentified bodies. Burns victims were the dominant reported cases in the forensic literature review where implant devices played a significant role in the identification process. In 1999, a case report about a burned body found in a car due to a fire was published (11). Along with the remaining bone fragments, a device with multiple wires connected to the vertebrae bodies, T10 to T12, was found. However, no serial number was found on the device. The identification was accomplished by obtaining postmortem radiographs and confirming its identity with the orthopedic surgeon who implanted the device (11). Another publication reported that a severely burned body at a temperature of 800-1000 °C was found in a rural house fire. Conventional methods of identification could not be used; thus, the details of the dental and skeletal remains were obtained. An orthopedic surgical plate was found amongst the remains and compared with the written antemortem hospital records. The comparison was consistent with the postmortem details, and the identification was achieved (12).

Implanted orthopedic devices and surgical records can be efficient for both the family of the deceased and the forensic expert in identifying the dead body. A publication reported that a forensic anthropology center in Sao Paulo, Brazil, began examination procedures to identify an unknown burned human body on April 25th, 2011 (7). The claimant family members were in-

terviewed, obtaining the following data: description of the victim's tattoo; history of orthopedic surgery for a left forearm bone fracture. However, they did not know any information about the dentist the missing person used to visit. The forensic experts could not identify any information from the fingerprints because of the burn. There were missing teeth, a visible green tattoo in the upper third of the right arm, and a fixed metal plate in the left ulna. The claimant family members provided a left forearm radiograph of the missing person and a document given by the company that dealt with the sale of orthopedic surgical devices with full tracking information about the patient and the procedure. Finally, a positive identification was made with low-cost procedures (7).

Orthopedic surgical implants can also be used in identifying various types of victims other than burns, for example, drowning, earthquake, and tsunami victims (5,13). A body of an unknown woman was found floating in a river; there were no personal belongings found to confirm the decedent's identity (5). The important identification related autopsy findings were multiple parallel linear scars on the anterior left forearm that appeared to be caused by previous self-inflicted incised injuries. In contrast, three linear scars on the upper lateral right thigh that appeared to be caused by previous surgery were also evident. Plain radiography of the right thigh was done, showing an intramedullary nail in the right femur. Findings revealed that Aesculap AG (Tuttingen, Germany) manufactured the intramedullary nail that was implanted. The device was composed of six parts and the lot numbers of four of them were noted. Lot numbers were identified by the manufacturer, and hospital (5). Victim identification using orthopedic surgical implants was attempted in the 2011 East-Japan earthquake and tsunami disaster (13). Out of 331 sets of unknown human ashes preserved in the temples after the cremation, 8 had a non-combustible orthopedic implant. Out of the 8, the lot numbers were fully legible in 2, which led to positive identification (13).

Overall, alternative methods of identification are vital in various scenarios like severely decomposed bodies or severely charred bodies where conventional methods of identification are likely to fail. Thus, the forensic expert needs another method to confirm the dead body's identity in these cases. One of these meth-

ods is identification using the orthopedic implant devices if the deceased person underwent any orthopedic implant surgery antemortem. When identifying the orthopedic device, it is crucial to obtain information like a specific serial number and comprehensive details on the manufacturer like the logo, name, and company number. However, all this information must be written in the patient's medical record to identify and confirm the decedent's identity. Moreover, the history furnished by the claimant family members must be matched with the forensic identification details.

Conclusion

In conclusion, once a person has officially been announced as missing, it would be significant to maintain all medical records, including radiographs and dental records. Orthopedic devices provide an additional method of identification in forensic practice. Limited research on forensic identification using implanted devices is found in this review. Moreover, only a few cases were found to have antemortem radiographs or sufficient medical record information about the implanted devices. Future directions should be toward using implanted devices in the identification process, wherever applicable, due to the low-cost and time-saving procedures involved, and the non-combustible nature of such devices. Finally, there is an increased need to educate forensic experts in the usage of implants for identification purposes and to influence all medical doctors to record comprehensive information about the manufacturer like the logo, name, and company number of the implants used by them in surgical practice.

Conflict of Interest: Each author declares that he/she has no commercial associations (e.g., consultancies, stock ownership, equity interest, patent/licensing arrangement etc.) that might pose a conflict of interest in connection with the submitted article.

References

1. Shepherd R, Simpson K, Payne-James J (ed). *Simpson's Forensic Medicine*, 14th Edition. CRC Press; 2017.
2. Ciaffi R, Gibelli D, Cattaneo C. Forensic radiology and personal identification of unidentified bodies: a review. *Radiol Med* 2011; 116: 960-8.
3. de Boer HH, Roberts J, Delabarde T, Mundorff AZ, Blau S. Disaster victim identification operations with fragmented, burnt, or commingled remains: experience-based recommendations. *Forensic Sci Res* 2020; 5: 191-201.
4. Christopher WS, Steven AS. Analysis of human cremains. In: John JS, Michael WW, John SK, 2nd eds. *The Analysis of Burned Human Remains*. Elsevier Inc; 2015: 83-103.
5. Takeshita H, Nagai T, Sagi M, et al. Forensic identification using multiple lot numbers of an implanted device. *Med Sci Law* 2014; 54: 51-3.
6. Simpson EK, James RA, Eitzen DA, Byard RW. Role of orthopedic implants and bone morphology in the identification of human remains. *J Forensic Sci* 2007; 52: 442-8.
7. Matoso RI, Benedicto ED, de Lima SH, Prado FB, Daruge E, Junior ED. Positive identification of a burned body using an implanted orthopedic plate. *Forensic Sci Int* 2013; 229: 168.e1-5.
8. Blessing MM, Lin PT. Identification of bodies by unique serial numbers on implanted medical devices. *J Forensic Sci* 2018; 63: 740-4.
9. Wilson RJ, Bethard JD, DiGangi EA. The use of orthopedic surgical devices for forensic identification. *J Forensic Sci* 2011; 56: 460-9.
10. Khartade HK, Meshram V, Garg SP, Mishra DK. Identification of skeletal remains by orthopaedic implant: a case report and brief review of the literature. *Med Sci Law* 2021; 61: 150-4.
11. Bennett JL, Benedix DC. Positive identification of cremains recovered from an automobile based on presence of an internal fixation device. *J Forensic Sci* 1999; 44: 1296-8.
12. Bassed R. Identification of severely incinerated human remains: the need for a cooperative approach between forensic specialities - a case report. *Med Sci Law* 2003; 43: 356-61.
13. Numata N, Makinae H, Yoshida W, Daimon M, Murakami H. Disaster victim identification using orthopedic implants in the 2011 East-Japan earthquake and tsunami. *Tohoku J Exp Med* 2017; 241: 219-23.

Correspondence

Received: 30 October 2021

Accepted: 29 December 2021

Rujittika Mungmunpantipantip

Private Academic Consultant, Bangkok Thailand

Email: rujittika@gmail.com