

Chronic bilateral sleeve fracture of the patellae in a healthy child: a case report

Jia-Yi Shao, Yu-Ping Yang, Ying-Fang Ao

Institute of Sports Medicine, Peking University Third Hospital, Beijing Key Laboratory of Sports Injuries, Beijing 100191, China.

To the Editor: Sleeve fracture of the patella is considered as a unique type of patellar injury to the pediatric population. It is a special type of avulsion fracture in which the avulsed fragment comprises of a small bony fragment from the patella, accompanied by a large portion of articular cartilage.^[1] It makes up approximately half of patellar fracture in children.^[2] However, the occurrence of this injury bilaterally is extremely rare and there has been only few reports regarding the treatment and prognosis to this injury during its chronic phase. Here we reported a case of chronic bilateral sleeve fracture of the patellae in a 13-year-old healthy boy, who got injured in a running competition. To the author's best knowledge, this is the first case of chronic bilateral sleeve fracture of the patellae in current English literature.

A 13-year-old boy, who was previously healthy but suddenly felt weakness in both knees and hit the ground in a running competition, was initially admitted to a local hospital. The magnetic resonance imaging (MRI) showed that he had bilateral discontinuities of the patellar tendon, so the local hospital decided to perform an operation to this boy. However, he got a fever before the surgery, reaching a high temperature of 39.0°C. The blood test indicated that lymphocyte counting was extremely low, with CD4 144/μL, but other laboratory results were unremarkable. After 1 week of antibiotic treatment, his temperature went back to normal range and CD4 level raised up to 400/μL.

He was then transferred to our hospital. On inspection, the boy had atrophy of the quadriceps, swelling of both knees and high-riding patellae. The palpation indicated that there was a tender palpable gap at the inferior poles of bilateral patellae. He had difficulty straightening both of his legs, and the active range of motion (ROM) of both knees is 40° to 110°. The lateral radiographs exhibited small tiny avulsed bony fragments of the bilateral patellae and patella alta [Figure 1A]. The computed tomography and MRI later

confirmed the bilateral patellar sleeve fracture [Figure 1B, 1D and 1E].

In hospital, the boy suffered from an upper respiratory infection, so the antibiotics was used and consequently the surgery was postponed 2 weeks until he was fully recovered. He underwent a surgery of open reduction and internal fixation of both knees 2 months after the initial injury. Prophylactic antibiotics were used during the perioperative period. In operation, a midline incision was applied. The avulsed fragments of bone and cartilage were all removed. Three 2-mm diameter transosseous tunnels were drilled from the inferior pole to the anterior side of middle part of the patella, then Orthocord sutures (DePuy Mitek, USA) were used to rigidly fix the patellar tendons [Figure 1C].

Postoperatively, the patient was immobilized in bilateral straight splints for 3 weeks, followed by routine physical therapy. The patient regained full and painless ROM at 1-year follow-up, and MRI at 1-year follow-up showed good continuities of the bilateral patellar tendons and healing of the fracture [Figure 1F–1G].

Sleeve fracture of the patella is a special type of avulsion fracture in which the avulsed fragment comprises a small bony fragment from the patella, accompanied by a large portion of articular cartilage. Sleeve fracture of the patella is considered as a unique type of patellar injury to the child.

The treatment options for this injury include nonoperative and operative treatment. Conservative treatment can be applied only to the minimal displaced fracture.^[1,2] Others have to undergo a surgical repair. Recent literatures have shown that early treatment can achieve a good prognosis, while the patient may have severe complications if the treatment is delayed. For these patients with delayed treatment, the injury will turn into chronic phases. The symptoms of chronic patellar sleeve fractures include: nonunion of the fracture, patellar pain, quadriceps

Access this article online

Quick Response Code:



Website:
www.cmj.org

DOI:
10.1097/CM9.0000000000000926

Correspondence to: Yu-Ping Yang, Institute of Sports Medicine, Peking University Third Hospital, Beijing Key Laboratory of Sports Injuries, 49 North Garden Rd, Haidian District, Beijing 100191, China
E-Mail: yyyppvip@163.com

Copyright © 2020 The Chinese Medical Association, produced by Wolters Kluwer, Inc. under the CC-BY-NC-ND license. This is an open access article distributed under the terms of the Creative Commons Attribution-Non Commercial-No Derivatives License 4.0 (CCBY-NC-ND), where it is permissible to download and share the work provided it is properly cited. The work cannot be changed in any way or used commercially without permission from the journal.

Chinese Medical Journal 2020;133(14)

Received: 28-02-2020 Edited by: Xiu-Yuan Hao

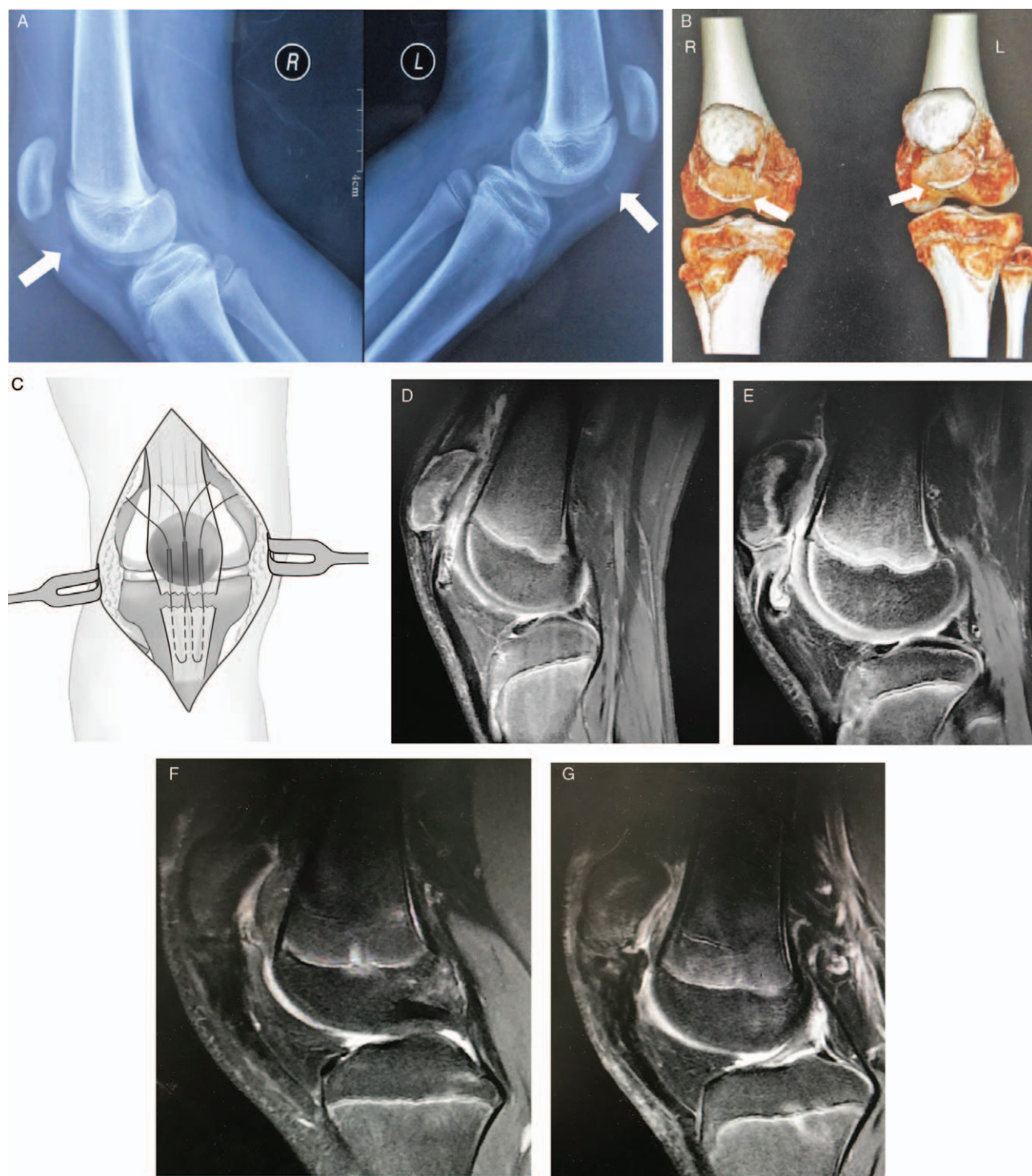


Figure 1: Imaging results and diagram of the operation. (A) Lateral X-ray showed small tiny avulsed fragments and patella alta. (B) 3D reconstructed computed tomography showed the avulsed fragments. (C) Diagram of the operation. (D, E) Preoperative MR images of the right (D) and left (E) knee. (F, G) Postoperative MR images of the right (F) and left (G) knee at 1-year follow-up. White arrows indicated the avulsed fragments.

atrophy, continuous restriction of ROM and patellar alta.^[2-4] And as the avulsed cartilaginous fragment still undergoes the process of chondroosseous transformation, there can be an ossification or ectopic bone formation within the patellar tendon.^[4,5]

For those patients with symptomatic chronic sleeve fracture of the patella, conservative treatment like cast immobiliza-

tion may result in continued quadriceps atrophy,^[2,3] soft tissue healing,^[2] continuous patellar deformity and restriction of ROM.^[3,4,6] Thus, a surgical intervention is a necessity. Surgery has shown improved outcomes in almost all cases^[3-6] (two reports lack in information). The key for the surgery is to reconstruct the patellar tendon with rigid fixation. Four methods have been used to acute patellar sleeve fracture, including transosseous suturing, tension

band wiring, absorbable sutures and suture anchors.^[1] All methods can achieve satisfactory outcomes. However, there has not been an agreement for the treatment of chronic sleeve fracture of the patella. Only two of these four methods (transosseous suturing and tension band wiring) have been reported. Meanwhile, some novel approaches, such as V-Y lengthening of the quadriceps tendon^[4] and Taylor spatial frame^[6] were used if the patient was left untreated more than a year because of the contracture of the soft tissue. In our case, in which the patient was treated two months after the injury, we used transosseous non-absorbable suturing to get the solid fixation on both knees. The patient got excellent outcome on both knees at 1-year follow-up. To our best knowledge, we are the first to describe the outcome of chronic sleeve fracture of the patella using this method.

The surgery complications include avascular necrosis of patella, wound infection, and knee flexion limitations.^[2,3] In our case, we used antibiotics to our patient during the perioperative period, who suffered from infection twice before the surgery. He had no sign of infection after the operation.

In conclusion, chronic bilateral sleeve fracture of the patellae is an extremely rare injury in the pediatric population. We have described the first case of a patient with chronic bilateral sleeve fracture of the patellae. We used the transosseous suturing methods to this patient two months after his injury, which showed satisfactory outcome at 1-year follow-up.

Declaration of patient consent

The authors certify that they have obtained all appropriate patient consent forms. In the form the patient(s)/ or his /her guardian has/have given his/her/their consent for his/her/

their images and other clinical information to be reported in the journal. The patients or his /her guardian understand that his /her/their name(s) and initials will not be published and due efforts will be made to conceal his /her/their identity, but anonymity cannot be guaranteed.

Funding

This study was supported by a grant from the National Key Research and Development Program of China (No. 2019YFF0302305).

Conflicts of interest

None.

References

1. Hunt DM, Somashekar N. A review of sleeve fractures of the patella in children. *Knee* 2005;12:3–7. doi: 10.1016/j.knee.2004.08.002.
2. Grogan DP, Carey TP, Leffers D, Ogden JA. Avulsion fractures of the patella. *J Pediatr Orthop* 1990;10:721–730. doi: 10.1097/01241398-199011000-00004.
3. Wu C-D, Huang S-C, Liu T-K. Sleeve fracture of the patella in children: a report of five cases. *Am J Sports Med* 1991;19:525–528. doi: 10.1177/036354659101900521.
4. Damrow DS, Van Valin SE. Patellar sleeve fracture with ossification of the patellar tendon. *Orthopedics* 2017;40:e357–e359. doi: 10.3928/01477447-20161026-02.
5. Bruijn J, Sanders R, Jansen B. Ossification in the patellar tendon and patella alta following sports injuries in children. *Arch Orthop Trauma Surg* 1993;112:157–158. doi: 10.1007/bf00449996.
6. Potini VC, Reilly MC, Gehrmann RM. Staged treatment of a chronic patellar sleeve fracture using the Taylor spatial frame. *Knee* 2015;22:672–676. doi: 10.1016/j.knee.2015.04.010.

How to cite this article: Shao JY, Yang YP, Ao YF. Chronic bilateral sleeve fracture of the patellae in a healthy child: a case report. *Chin Med J* 2020;133:1744–1746. doi: 10.1097/CM9.0000000000000926