



Case Report

Acute respiratory failure on varicella pneumonia in Indonesian adult with chronic hepatitis B: A case report and review article



Yuly Rahmawati, Daniel Maranatha*

Department of Pulmonology and Respiratory Medicine, Faculty of Medicine, Universitas Airlangga – Dr. Soetomo General Academic Hospital, Surabaya, Indonesia

ARTICLE INFO

Keywords:

Hepatitis B

Pneumonia

Respiratory support

Varicella

ABSTRACT

Background: Varicella pneumonia is a rare clinical manifestations and potentially lethal complications of varicella in a previously healthy adult.

Case presentation: An Indonesian male, 44 years old, Javanese ethnic, complained of progressive dyspnea two days. He had previously been contacting varicella from his daughter 3–4 days before dyspnea onset. He showed typical symptoms of varicella, such as fever and vesicles all over the body. He had been in good health despite having a chronic hepatitis B infection. Chest X-ray on admission revealed bilateral diffuse consolidation with air-bronchogram. Diagnosis of varicella pneumonia was based on typical varicella cutaneous, clinical and chest X-ray findings. We installed mechanical ventilatory support in the isolation ward and he received acyclovir and symptomatic treatment. Ventilatory support was removed on the 3rd day. He successfully recovered on the third day and uninstalled an endotracheal tube.

Discussion: The early and accurate diagnosis of varicella pneumonia was based on disease course and chest X-ray. Managing varicella pneumonia with acute respiratory failure was mechanical ventilator support (when needed), an antiviral, and other symptomatic treatment.

Conclusion: Varicella pneumonia is a rare and severe complication with a good prognosis if diagnosed and treated promptly.

1. Introduction

Varicella pneumonia, first reported in 1942, can be severe and fatal in previously healthy individuals [1,2]. Varicella pneumonia was reported in 0.25–10% of adults, who died around 5–23%. Data from England and Wales show that the proportion of adult deaths from varicella associated with pneumonia is 42.3%. Varicella pneumonia worsens gradually. Approximately 1–6 days post-infection, varicella rash, dyspnea, and cough appear [3]. The complication of varicella pneumonia is dead, confirmed in 400 cases that one patient died [2,4]. Varicella pneumonia can induce significant morbidity in impaired immune status, such as hepatitis B. It can lead to mortality if left untreated [5]. Early treatment using high-dose intravenous acyclovir with mechanical ventilation support on varicella patients with acute respiratory failure is key to successfully managing severe varicella pneumonia [6,7]. We reported a rare topic, in Indonesian males with varicella pneumonia, hepatitis B, and acute respiratory failure who recovered by using an antiviral and mechanical ventilator. We report based on SCARE 2020

guidelines [8].

2. Case presentation

An Indonesian male, 44 years old, Javanese ethnic, was referred to the emergency department with progressive dyspnea, fever, and vesicles all over his body. The first symptom he had was fever. Vesicles initially appeared behind the ear on the 2nd day of fever and then spread along with increasing fever throughout the body. He started experiencing blood-streaked cough, joint and abdominal pain on the 3rd day. He was then admitted to a previous hospital and developed worsening dyspnea during 3-day treatment before being taken to our emergency department. The patient had a history of hepatitis B since seven years ago and was not taking medication, did not smoke, and had contact with his daughter suffering from varicella at home. The patient's current condition is debilitating, pulse rate of $100 \times /\text{min}$, respiratory rate of $40 \times /\text{min}$, axillary temperature of $38.4 \text{ }^\circ\text{C}$, and SO_2 of 86% with 10 L/min non-rebreathing masks. Chest physical examination revealed Ronchi

* Corresponding author. Department of Pulmonology and Respiratory Medicine, Faculty of Medicine, Universitas Airlangga – Dr. Soetomo General Academic Hospital, Jl. Mayjend Prof. Dr. Moestopo No. 6-8, Airlangga, Gubeng, Surabaya, East Java, 60286, Indonesia.

E-mail address: daniel-maranatha@fk.unair.ac.id (D. Maranatha).

<https://doi.org/10.1016/j.amsu.2022.104149>

Received 23 May 2022; Received in revised form 5 July 2022; Accepted 6 July 2022

Available online 14 July 2022

2049-0801/© 2022 The Authors. Published by Elsevier Ltd on behalf of IJS Publishing Group Ltd. This is an open access article under the CC BY-NC-ND license (<http://creativecommons.org/licenses/by-nc-nd/4.0/>).

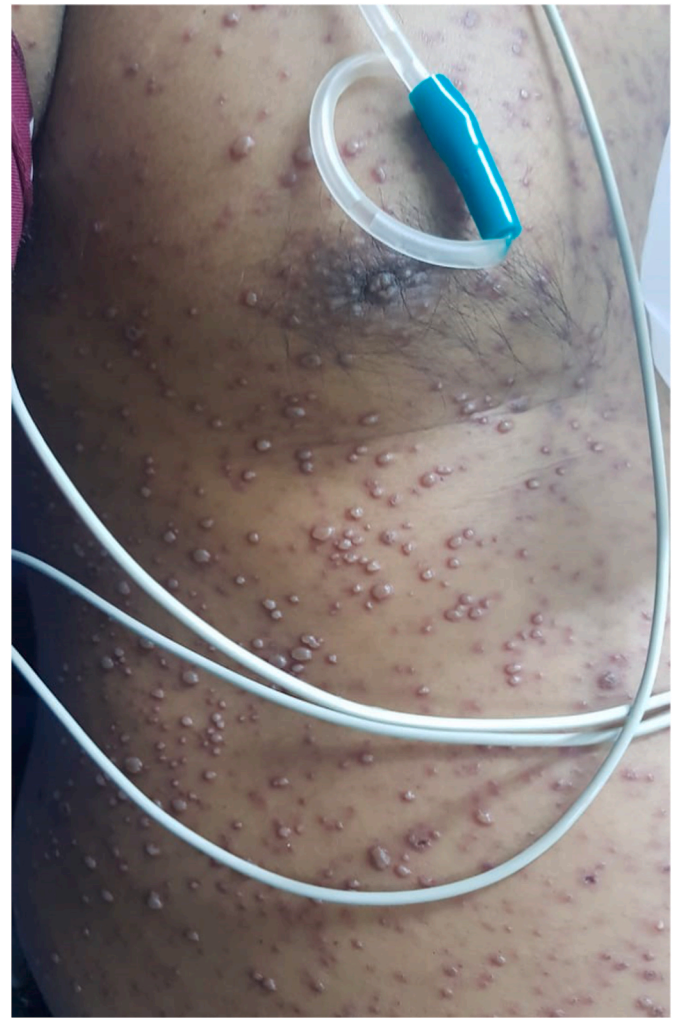
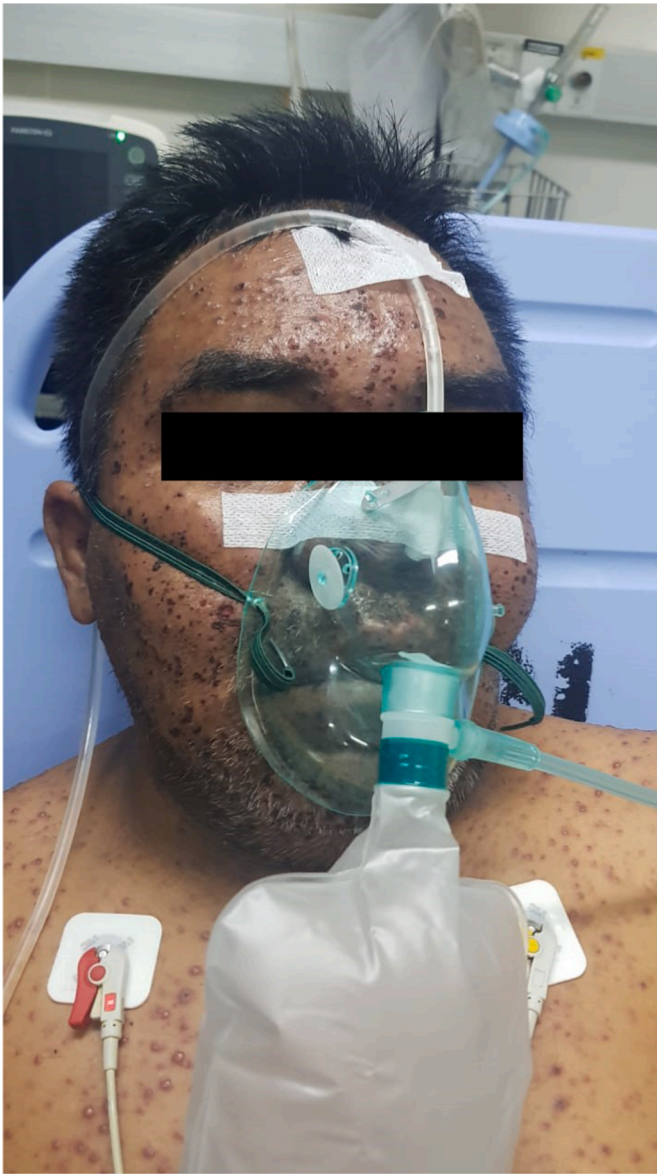
Fig. 1. Skin showed vesicles all over the body during hospital admission.

and wheezing on both hemithorax. The skin showed multiple vesicles filled with cloudy fluid with an erythematous macular base and multiple papules with an erythematous macular base, some erosion (Fig. 1).

Laboratory investigation showed hepatitis B surface antigen (HBsAg) of reactive, alanine transaminase (ALT) of 152 U/L, and aspartate transaminase (AST) of 373 U/L (Table 1). Blood gas analysis showed on O₂ 10 L/minute non-rebreathing mask metabolic alkalosis compensated for respiratory acidosis with severe hypoxemia. However, a chest X-ray showed infiltration in both lungs (Fig. 2). Both sputum and blood cultures showed no growth of germs. The diagnosis was varicella pneumonia and inactive hepatitis B.

He was transferred to the isolation ward due to his active varicella status. Mechanical ventilator support was performed with BIPAP mode, PEEP 8, and FiO₂ 30% because he experienced severe hypoxemia. Other therapy was given, such as acyclovir 4 g/24 hours in divided doses, Meropenem 1 gr/8 hours, topical sodium fusidate 2%, and salicylic acid 10%. On the third day, the ventilator was removed and changed a simple mask with 6 L/min oxygen. Meropenem was stopped on day 4 because the patient showed no sign of bacterial infection. On the sixth day, the Tzank smear test showed a negative result, and the patient was

transferred to the regular ward. The patient's condition improved on the ninth day. As supplemental oxygen therapy was no longer required, discharge planning was undertaken with outpatient follow-up.

3. Discussion

Varicella pneumonia was one of the adults' most severe complications of this infection [9]. The characteristic symptom of varicella is fever accompanied by a skin rash in small vesicles and itching, which usually appears from the chest, back, face and the whole body, followed by fatigue, headache and decreased appetite [10]. People living in the same household with individuals infected with varicella zoster-virus have a significantly higher risk of developing varicella than those exposed for less time [11]. Diagnosis of varicella pneumonia is based on the development of respiratory symptoms with radiological findings of diffuse interstitial, or nodular infiltrates within 10 days following the onset of clinically evident Varicella infection [12]. Varicella pneumonia usually develops within 1–6 days of the onset of varicella. Symptoms include cough, fever, shortness of breath, tachypnea, cyanosis, pleuritic pain and hemoptysis. Ronchi and wheezing may also be found on

Table 1
Laboratory examination result.

Variable	Result
White blood count ($10^3/\mu\text{L}$)	10,860
Basophil (%)	1.5
Eosinophil (%)	0.2
Granulocytes (%)	59
Monocytes (%)	2.9
Lymphocytes (%)	21.8
Hemoglobin (g/dL)	13.8
Platelet ($10^3/\mu\text{L}$)	110
Alanine transaminase (U/L)	152
Aspartate transaminase (U/L)	373
Hepatitis B surface antigen (HBsAg)	Reactive
Human immunodeficiency virus (HIV)	Negative
Blood gas analysis	
pH	7.41
pCO ₂ (mmHg)	45
pO ₂ (mmHg)	57
HCO ₃ (mol/L)	28.5
BE (mol/L)	3.9
SaO ₂ (%)	90
P/F ratio	71.25

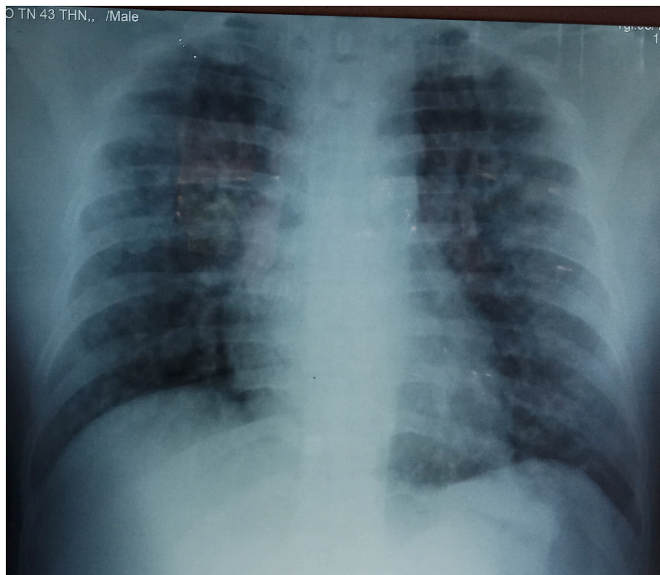


Fig. 2. Chest X-ray showed infiltration in all lobes.

physical examination [13].

Severe varicella pneumonia can be caused by a decrease in the function of T-helper cells in hepatitis patients, resulting in a reduction of cytotoxic CD8. This condition makes the patient susceptible to infection with other viruses such as a varicella-zoster virus (VZV) and a high risk for complications [14,15]. Patients with severe pneumonia may require intubation and mechanical ventilator support [16]. The benefit of mechanical ventilation in oxygenation is that it ensures proper titration of FiO₂ and generates sufficient inspiratory pressure to open collapsed alveoli. Mechanical ventilation is also crucial for removing CO₂ [17]. In addition, the patient was given acyclovir triphosphate, which was used to inhibit viral DNA synthesis by replacing deoxyguanosine triphosphate as a substrate for viral DNA polymerase. The inhibitory concentration of acyclovir required to reduce VZV plaque by 50% is approximately 3 g/ml. Most doses of acyclovir are absorbed slowly after oral administration, with a bioavailability of about 15–30%. The mean peak concentrations under stable conditions were 0.6 and 1.6 g/ml after multiple 200 mg or 800 mg doses. The approved oral amount for VZV is 200 mg (maximum 800 mg) 4–5 times daily for five days [18].

The prognosis of severe varicella pneumonia using current standard

therapy is improving. Several factors, such as early diagnosis, administration of acyclovir, and treatment in the ICU with ventilator support, contributed to the excellent outcome [12,19].

4. Conclusion

Varicella pneumonia is a rare complication of varicella infection. Early diagnosis and fast response are crucial because of the high mortality risk caused by acute respiratory failure. In this case, mechanical ventilator support and antiviral play an influential role in severe varicella pneumonia management.

Provenance and peer review

Not commissioned, externally peer-reviewed.

Funding

The author(s) received no financial support for this article's research, authorship, and/or publication.

Ethical approval

This case report does not require any ethical approval.

Author contribution

All authors contributed to data analysis, drafting and revising the paper, giving final approval of the version to be published, and agreeing to be accountable for all aspects of the work.

Registration of research studies

Name of the registry: -.

Unique Identifying number or registration ID: -.

Hyperlink to your specific registration (must be publicly accessible and will be checked): -.

Research registration

Not applicable.

Consent

Written informed consent was obtained from the patient's parent/guardian to publish this case report and accompanying images. A copy of the written permission is available for review by the Editor-in-Chief of this journal.

Guarantor

Daniel Maranatha is the person in charge of the publication of our manuscript.

Declaration of competing interest

Yuly Rachmawati and Daniel Maranatha declare that they have no conflict of interest.

Acknowledgement

We would like thanks to our editor, "Fis Citra Ariyanto".

References

- [1] R.N. Davidson, W. Lynn, P. Savage, M.H. Wansbrough-Jones, Chickenpox pneumonia: experience with antiviral treatment, *Thorax* 43 (8) (1988) 627–630, <https://doi.org/10.1136/thx.43.8.627>.
- [2] T. Shalaby, R. Mankragod, Varicella pneumonia, *Br. J. Hosp. Med.* 76 (6) (2015) 365, <https://doi.org/10.12968/hmed.2015.76.6.365> (London, England : 2005).
- [3] B.C. Ho, D.Y. Tai, Severe adult chickenpox infection requiring intensive care, *Ann. Acad. Med. Singapore* 33 (1) (2004) 84–88.
- [4] A.H. Mohsen, M. McKendrick, Varicella pneumonia in adults, *Eur. Respir. J.* 21 (5) (2003) 886–891, <https://doi.org/10.1183/09031936.03.00103202>.
- [5] T.Y. Li, Y. Yang, G. Zhou, Z.K. Tu, Immune suppression in chronic hepatitis B infection associated liver disease: a review, *World J. Gastroenterol.* 25 (27) (2019) 3527–3537, <https://doi.org/10.3748/wjg.v25.i27.3527>.
- [6] A.A. Gershon, J. Breuer, J.I. Cohen, R.J. Cohrs, M.D. Gershon, D. Gildea, et al., Varicella zoster virus infection, *Nat. Rev. Dis. Prim.* 1 (2015), 15016, <https://doi.org/10.1038/nrdp.2015.16>.
- [7] A. Singh, S. Parkash, S.K. Gupta, R.K. Soni, Severe varicella pneumonia in adults: seven years' single-center experience from India, *Indian J. Crit. Care Med.* : Peer-Reviewed Off Publ Indian Soc Crit Care Med 22 (3) (2018) 162–167, https://doi.org/10.4103/ijccm.IJCCM_495_17.
- [8] R.A. Agha, T. Franchi, C. Sohrabi, G. Mathew, A. Kerwan, The SCARE 2020 guideline: updating consensus surgical CAse REport (SCARE) guidelines, *Int. J. Surg.* 84 (2020) 226–230, <https://doi.org/10.1016/j.ijsu.2020.10.034> (London, England).
- [9] E. Chiner, I. Ballester, I. Betloch, J. Blanquer, M.C. Aguar, R. Blanquer, et al., Varicella-zoster virus pneumonia in an adult population: has mortality decreased? *Scand. J. Infect. Dis.* 42 (3) (2010) 215–221, <https://doi.org/10.3109/00365540903428166>.
- [10] G. Andrei, R. Snoeck, Advances and perspectives in the management of varicella-zoster virus infections, *Molecules* 26 (4) (2021), <https://doi.org/10.3390/molecules26041132>.
- [11] A.M. Arvin, Varicella-zoster virus, *Clin. Microbiol. Rev.* 9 (3) (1996) 361–381, <https://doi.org/10.1128/cmr.9.3.361>.
- [12] M. Alanezi, Varicella pneumonia in adults: 13 years' experience with review of literature, *Ann. Thorac. Med.* 2 (4) (2007) 163–165, <https://doi.org/10.4103/1817-1737.36551>.
- [13] A. Mirouse, P. Vignon, P. Piron, R. Robert, L. Papazian, G. Géri, et al., Severe varicella-zoster virus pneumonia: a multicenter cohort study, *Crit. Care* 21 (1) (2017) 137, <https://doi.org/10.1186/s13054-017-1731-0>.
- [14] B. Rehermann, Chronic infections with hepatotropic viruses: mechanisms of impairment of cellular immune responses, *Semin. Liver Dis.* 27 (2) (2007) 152–160, <https://doi.org/10.1055/s-2007-979468>.
- [15] A. Rasche, F. Lehmann, N. Goldmann, M. Nagel, A. Moreira-Soto, D. Nobach, et al., A hepatitis B virus causes chronic infections in equids worldwide, *Proc. Natl. Acad. Sci. U. S. A* 118 (13) (2021), <https://doi.org/10.1073/pnas.2013982118>.
- [16] S.V. Baudouin, The pulmonary physician in critical care . 3: critical care management of community acquired pneumonia, *Thorax* 57 (3) (2002) 267–271, <https://doi.org/10.1136/thorax.57.3.267>.
- [17] L. Gattinoni, M. Quintel, How ARDS should be treated, *Crit. Care* 20 (2016) 86, <https://doi.org/10.1186/s13054-016-1268-7>.
- [18] A. Sauerbrei, Diagnosis, antiviral therapy, and prophylaxis of varicella-zoster virus infections, *Eur. J. Clin. Microbiol. Infect. Dis.* : Off Publ Eur Soc Clin Microbiol 35 (5) (2016) 723–734, <https://doi.org/10.1007/s10096-016-2605-0>.
- [19] S.H. Kim, S.H. Lee, Varicella pneumonia in an immunocompetent young adult in the vaccine Era, *J. Kor. Med. Sci.* 35 (48) (2020) e408, <https://doi.org/10.3346/jkms.2020.35.e408>.