



# Removal of foreign bodies embedded in the urinary bladder wall by a combination of laparoscopy and carbon dioxide cystoscopic assistance: Case report and literature review

Chengyue Jin, Yu Fan, Qian Zhang, Yu Wang, Shiliang Wu, Jie Jin

Department of Urology, Peking University First Hospital, Institute of Urology, Peking University, Urogenital Diseases (Male) Molecular Diagnosis And Treatment Center, National Research Center for Genitourinary Oncology, Beijing, China

**Purpose:** To report a case of combined laparoscopic and carbon dioxide partial cystectomy and foreign body removal and to review the existing literature on the topic.

**Materials and Methods:** A 43-year-old Asian woman was found to have an intrauterine device embedded in the bladder wall during evaluation for chronic pelvic pain and urinary tract infection. She underwent cystoscopic-laparoscopic partial cystectomy, with an uncomplicated postoperative course. She had normal renal function during the follow-up period. This case demonstrates the possibility and safety of performing cystoscopic-laparoscopic partial cystectomy for the removal of a partially implanted intravesical foreign body.

**Results:** The patient recovered without incident and was discharged 7 days after surgery. No abnormalities were noted in the urine output or renal function in the postoperative follow-up period. No complications due to retrograde flow of carbon dioxide up the ureters or air embolism were noted during the procedure or postoperatively.

**Conclusions:** The combination of laparoscopy and air cystoscopy has been shown to be an optimal method for retracting foreign bodies embedded in the bladder wall. Also, air cystoscopy can be used to give doctors a better view in cases in which vision is compromised under water-contrast cystoscopy.

**Keywords:** Cystoscopy; Intrauterine devices; Laparoscopy; Urinary bladder calculi

This is an Open Access article distributed under the terms of the Creative Commons Attribution Non-Commercial License (<http://creativecommons.org/licenses/by-nc/4.0>) which permits unrestricted non-commercial use, distribution, and reproduction in any medium, provided the original work is properly cited.

## INTRODUCTION

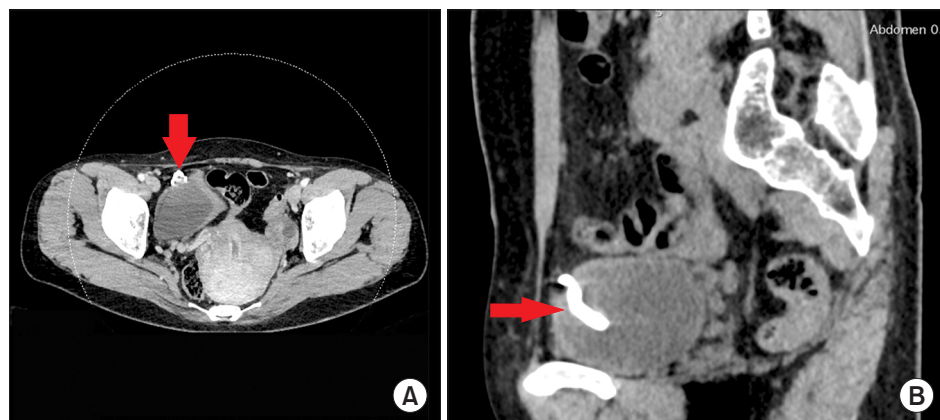Intravesical foreign bodies comprise a wide spectrum of objects and should be included in the differential diagnosis of patients with chronic lower urinary tract problems [1].

Intravesical intrauterine devices (IUDs) are an infrequent complication. Once an IUD has penetrated the urinary bladder, it usually becomes encrusted with calculi [2]. Conventionally, foreign bodies embedded in the bladder wall are removed by open surgery to repair the defect [3].

**Received:** 7 July, 2016 • **Accepted:** 5 September, 2016

**Corresponding Author:** Jie Jin

Department of Urology, Peking University First Hospital, 8 Xishiku Ave. Beijing 100034, China  
TEL: +86-10-68589301, FAX: +86-10-68589301, E-mail: jinjie\_pku@yeah.net



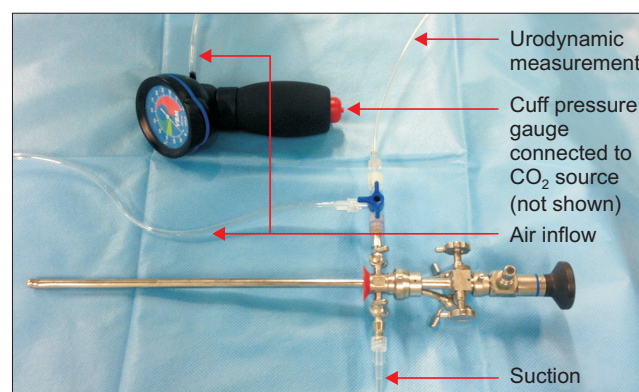
**Fig. 1.** Abdominal computed tomography (A: horizontal section. B: sagittal section) indicating a T-shaped intrauterine device embedded in the bladder wall (red arrow).

However, morbidity is high in this type of open surgery because adhesions resulting from chronic inflammation are common and extensive surgical exploration is usually required. There have been reports of laparoscopic management [4]. However, owing to adhesions, partially penetrated IUDs are often difficult to locate, the procedure can become difficult, and laparoscopic repair may not be feasible. We have introduced a combination of laparoscopy and carbon dioxide irrigated cystoscopy to minimize the morbidity associated with this procedure.

## MATERIALS AND METHODS

A 43-year-old female patient presented with recurrent suprapubic pain and chronic pelvic pain exacerbated by urination for 13 years. She had also experienced chronic dysuria, urinary urgency, low-grade fevers, and increased urinary frequency for 2 years. Further investigation revealed 1 circular IUD and 1 T-shaped IUD, which had been implanted 20 years ago and 14 years ago, respectively. The patient had become pregnant 19 years ago and was told that the first IUD had fallen out spontaneously. Hence, a second IUD had been implanted 14 years previously. An abdominal ultrasound performed 4 years ago showed 2 IUDs and a vesical calculi, and extracorporeal shock wave lithotripsy (ESWL) was performed. However, her symptoms were not alleviated after ESWL.

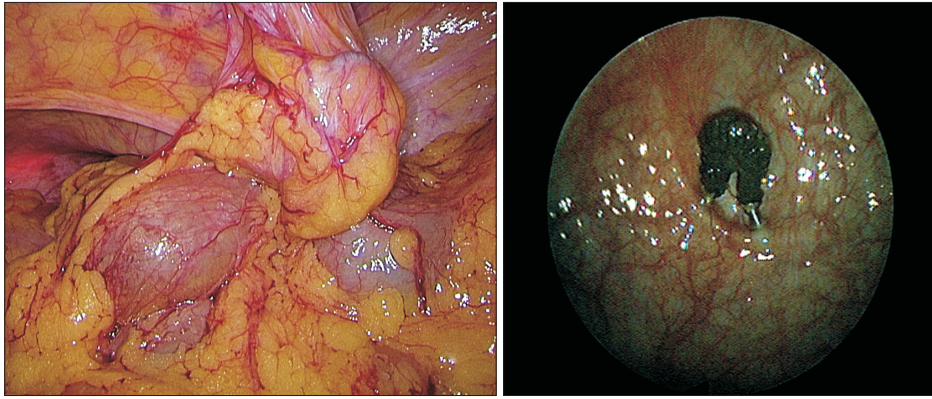
A physical examination revealed no specific findings. Her kidney function was not impaired (creatinine, 65  $\mu\text{mol/L}$ ; blood urea nitrogen, 3.48 mmol/L). The results of urine analysis indicated the following values: specific gravity, 1.023; white blood cells, 1485; red blood cells, 7.3, nitrate, (++) KUB (kidney-ureter-bladder), ultrasound, and abdominal computed tomography (Fig. 1) indicated a T-shaped metal IUD in the bladder wall. Therefore, displacement of the IUD was considered and a hysteroscopy was performed. One IUD



**Fig. 2.** Cystoscope equipped with a pressure-control device.

was removed through hysteroscopy from the uterus but the other IUD was not seen.

Under general anesthesia, the patient was placed in the Lloyd-Davies position and a rigid cystoscope (Olympus F24 70°, Olympus, Tokyo, Japan) was inserted into the bladder with CO<sub>2</sub> insufflation (Olympus UHI-3, Olympus). The cystoscope was equipped with a pressure-control device to maintain insufflation CO<sub>2</sub> pressure at 8 to 10 cmH<sub>2</sub>O (Fig. 2), and all water in the bladder was aspirated. After the foreign body was visualized (Fig. 3), a 12-mm laparoscopic port and a 5-mm port were introduced suprapubically. The CO<sub>2</sub> pressure of the abdominal cavity was controlled at 14 cmH<sub>2</sub>O to achieve adequate distention and positive pressure to the bladder to prevent contamination of the abdominal cavity. Under laparoscopy, pervasive adhesions were seen between the posterior wall of the bladder and omentum, but the IUD was not visualized. The foreign body was located first under cystoscopy and then under laparoscopy with cystoscopic guidance through a laparoscopic grasper introduced from the urethra. After the IUD was located, the air in the bladder was deflated via suctioning from the cystoscope. A harmonic scalpel was used to dissect the peritoneum over the bladder and the foreign body was adequately exposed. Part of the



**Fig. 3.** Laparoscopic and air cystoscopic view of the intrauterine device and calculus.

bladder wall and extraperitoneal fat was removed with the foreign body by the harmonic scalpel with assistance from a grasper to stabilize the foreign body cystoscopically. The foreign body was extracted *en bloc* through the urethra. Blood and urine accumulated in the trigone of the bladder during the procedure and intermittent suction through the cystoscope was necessary to avoid contamination of the abdominal cavity. After the foreign body was successfully removed, the bladder wall was closed with a continuous suture using 2-0 Vicryl sutures (Ethicon, Cincinnati, OH, USA), and the overlying peritoneum was sutured using 3-0 Vicryl sutures. The sealing of the bladder wall was checked by irrigating CO<sub>2</sub> back into the bladder with 8 cmH<sub>2</sub>O pressure, and the bladder expanded under both the laparoscopic and cystoscopic views. The bladder was drained postoperatively by using a three-way Foley catheter. The skin incision used for percutaneous drainage was closed with a simple suture.

## RESULTS

The patient recovered without incident and was discharged 7 days after surgery. No abnormalities were noted in the urine output or renal function in the postoperative follow-up. No complications due to retrograde flow of CO<sub>2</sub> up the ureters or air embolism were noted during the procedure or postoperatively.

## DISCUSSION

Although there is no consensus regarding the management of extrauterine IUDs in asymptomatic patients [4], the World Health Organization recommends that displaced IUDs be removed as soon as possible after a diagnosis has been made owing to possible chronic inflammation and adhesions. Treatment options vary

depending on the location of the displaced IUD in the bladder. Cystoscopy is often utilized to extract IUDs that are completely lodged in the bladder. In cases in which the IUD is embedded in the bladder wall and repair is needed, open surgery and laparoscopy should be considered.

Air cystoscopy, also known as pneumocystoscopy or aerocystoscopy, was once popular in the early 1900s. Trends in management changed when modern endoscopy using fluid for irrigation became the standard of care in the 1920s. There are scarce reports utilizing air cystoscopy since that time. However, all such reports claim that visualization via a gas medium is superior to a liquid medium [5-7]. This has also been our experience, especially when performing cystoscopy with compromised visualization in cases such as removing partially soluble intravesical foreign bodies (e.g., a candle). Because air embolism could become a theoretical issue in surgical procedures requiring air insufflations (laparoscopy and air endoscopy), a pressure-control device is attached to the CO<sub>2</sub> generator. Pressure can be controlled between 8 and 10 mmH<sub>2</sub>O, which is lower than the blood pressure in the vena cava. No signs or symptoms of air embolism were observed in our patient. Similar to our combination of laparoscopy and cystoscopy, Bala et al reported using a 10-mm laparoscopic port passed suprapubically into the bladder under carbon dioxide cystoscopic guidance to remove an intravesical foreign body in a pediatric patient [8]. A similar approach was combined with robotic assistance in a bladder diverticulectomy [9].

Compared to open surgery or laparoscopic removal alone, the advantages of our approach are as follows: (1) the foreign body can be accessed both intra- and extra-vesically, which makes the procedure less difficult; (2) air as an optic medium provides the surgeon a better view of the surgical field (Fig. 3); (3) air pressure is controlled, and thus complication with air embolism is unlikely; and (4) intravesical pressure is kept below intra-abdominal pressure. Consequently, blood

and urine exist only at the dependent part of the bladder and are suctioned through the cystoscope. This is further ensured by removing the IUD transurethrally instead of laparoscopically. Therefore, the peritoneal cavity remains clean and postoperative infectious complications are less likely.

## CONCLUSIONS

The combination of laparoscopy and air cystoscopy has been proved to be an optimal method for retracting foreign bodies embedded in the bladder wall. Also, air cystoscopy can be used to give doctors a better view in cases in which vision is compromised under water-contrast cystoscopy.

## CONFLICTS OF INTEREST

The authors have nothing to disclose.

## REFERENCES

1. Rafique M. Intravesical foreign bodies: review and current management strategies. *Urol J* 2008;5:223-31.
2. Dietrick DD, Issa MM, Kabalin JN, Bassett JB. Intravesical migration of intrauterine device. *J Urol* 1992;147:132-4.
3. Mustafa M. Erosion of an intrauterine contraceptive device through the bladder wall causing calculus: management and review of the literature. *Urol Int* 2009;82:370-1.
4. Shin DG, Kim TN, Lee W. Intrauterine device embedded into the bladder wall with stone formation: laparoscopic removal is a minimally invasive alternative to open surgery. *Int Urogynecol J* 2012;23:1129-31.
5. Hajós L, Szüle E. Pneumocystoscopy. *Z Urol Nephrol* 1971;64:129-30.
6. Matthews PN, Skewes DG, Kothari JJ, Woodhouse CR, Hendry WF. Carbon dioxide versus water for cystoscopy: a comparative study. *Br J Urol* 1983;55:364-6.
7. Parazajder J, Krivec O, Radej M, Kovacic M. Air as an optic medium in diagnostic cystoscopy. *Acta Chir Jugosl* 1977;24(1 Suppl):481-3.
8. Reddy BS, Daniel RD. A novel laparoscopic technique for removal of foreign bodies from the urinary bladder using carbon dioxide insufflation. *Surg Laparosc Endosc Percutan Tech* 2004;14:238-9.
9. Eyraud R, Laydner H, Autorino R, Panumatrassamee K, Haber GP, Stein RJ. Robot-assisted laparoscopic bladder diverticulectomy. *Curr Urol Rep* 2013;14:46-51.