

## Oncology

## Paratesticular Leiomyosarcoma: A Case Report and Review of the Literature



Joana Alfarelos<sup>a,\*</sup>, Gustavo Gomes<sup>a</sup>, Francisco Campos<sup>a</sup>, Mário Matias<sup>a</sup>, Amaral Canelas<sup>a</sup>, Matilde Gonçalves<sup>b</sup>

<sup>a</sup> Department of Urology, Centro Hospitalar de Setubal, Portugal

<sup>b</sup> Department of Pathology, Centro Hospitalar de Setubal, Portugal

## ARTICLE INFO

## Article history:

Received 9 October 2016

Received in revised form

29 October 2016

Accepted 2 November 2016

## Keywords:

Paratesticular

Sarcoma

Leiomyosarcoma

## ABSTRACT

Paratesticular sarcomas are rare. Most cases reported in the literature are depending on retrospective analysis of case reports, small series, literature reviews, and expert opinion and they show different outcomes depending on several variables. The majority indicate that this may be an indolent tumor with a potential for cure if treated early.

We present a case of a 58 year old man with a history of painless enlargement of the right testis. The ultrasound showed an extratesticular lesion and a right excisional of the mass was performed. The pathological examination revealed a leiomyosarcoma, and was then completed with a right radical inguinal orchiectomy.

A review of the literature regarding paratesticular sarcomas presentation, diagnosis and treatment is presented in this article.

© 2016 The Authors. Published by Elsevier Inc. This is an open access article under the CC BY-NC-ND license (<http://creativecommons.org/licenses/by-nc-nd/4.0/>).

## Introduction

Soft tissue sarcomas of the genitourinary tract account for less than 5% of all sarcomas and only 2% of urological malignancies.<sup>1</sup> Paratesticular tumors, which include those arising from testicular tunics, epididymis and spermatic cord are rare and their incidence is difficult to estimate.<sup>2</sup> Due to its rarity, there is no robust evidence regarding the ideal workout for diagnosis, treatment and follow-up.

## Case presentation

A 56-year old male patient presented to his urologist with a painless enlargement of the right scrotal content, which had gradually extended during the past 2 months. He had controlled hypertension. Results of the physical examination revealed a 3 cm swelling arising from the lower pole of the right testicle. The mass was subcutaneous, firm and non-tender. Scrotal ultrasonography identified a hypoechoic nodule in the lower pole of the right testis apparently independent from the epididymis, measuring approximately 30 × 28 mm (Fig. 1). Tumor markers (B-HCG), alpha-fetoprotein (AFP) and lactate dehydrogenase (LDH)

were normal and body computerized tomography (CT) showed no signs of metastasis.

Under anesthesia, it was performed a right radical orchiectomy (Fig. 2). The mass was characterized as a Leiomyosarcoma (LMS) of the spermatic cord, grade 1, according to National Federation of French Cancer Center Institute System (NFFCS). The tumor was 3,5 cm in diameter and well differentiated. There was no necrosis and presented 13 mitosis in 10 high-power field (HPF). It was AE/AE – Alfa-actin + and Desmin + (Fig. 3). A PET scan showed no signs of residual tumor and he is under surveillance for 13 months.

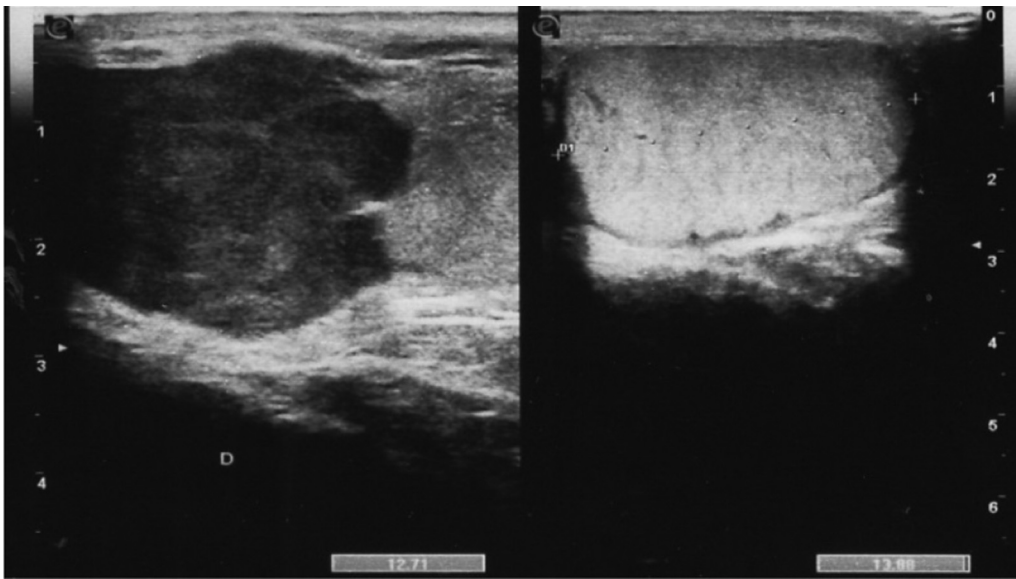
## Discussion

Masses within the scrotal sac can be testicular or paratesticular. Paratesticular tumors are rarer, less than 5% of the cases.<sup>3</sup> It has been estimated that 30% of paratesticular tumors are malignant<sup>4</sup>, and sarcomas are the most common type (90%).<sup>4</sup>

The paratesticular region is a complex anatomical area that includes the contents of the spermatic cord, testicular tunics, epididymis, fat-ligament-muscle supporting tissues and vestigial remnants such as the appendices epididymis and testis.<sup>5</sup> Histogenetically, this area is composed of a variety of epithelial, mesothelial and mesenchymal elements. Neoplasms arising from this region therefore form a heterogeneous group of tumors with different behavioral patterns.<sup>5</sup> Although it is often difficult to

\* Corresponding author.

E-mail address: [joanaalfarelos@gmail.com](mailto:joanaalfarelos@gmail.com) (J. Alfarelos).



**Figure 1.** Scrotal ultrasound: 3 cm heterogeneous lesion, closed to the testis.

determine with certainty the exact site of origin, it is thought that the spermatic cord is the most common, accounting for 90%.<sup>2</sup> Histological subtypes include LMS, rhabdomyosarcoma, liposarcoma, fibrosarcoma and undifferentiated pleomorphic sarcoma, being liposarcoma the most common.<sup>3,4</sup>

Sarcomas, like most malignant tumors, are classified according to their grade and stage. There are different grading systems proposed for sarcomas, of which the NFFCS has been shown to be reproducible among pathologists and correlates with the clinical outcome. Grading is based on the evaluation of the number of mitosis, the percentage of necrosis and the severity of nuclear pleomorphism and can be divided in 3 grades (Table 1). Other classification is the TNM system, which grades tumors according

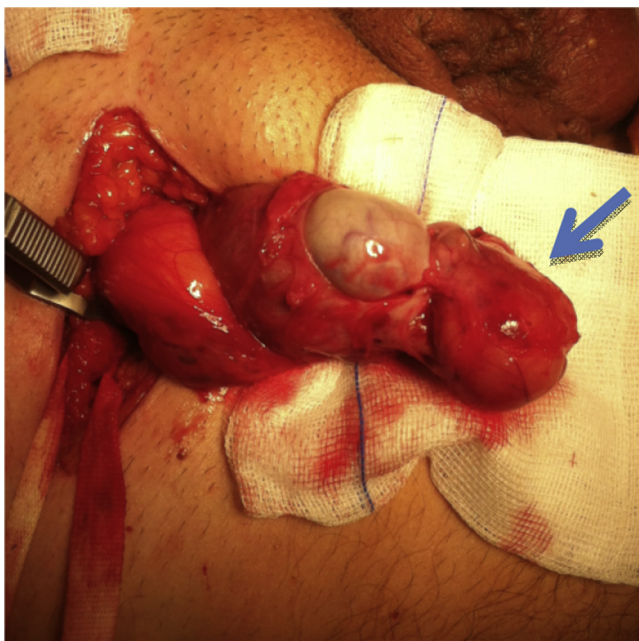
to their degree of differentiation into four grades: well differentiated, moderately differentiated, poorly differentiated and undifferentiated. The main prognostic factors of sarcomas are the site, size and grade of primitive tumors and nodal or distant metastasis.

LMS is a malignant soft tissue tumor that can arise from any tissue containing smooth muscle. Paratesticular LMS originates from the spermatic cord, the scrotum (testicular tunica, dartos muscle and scrotal subcutis) or the epididymis. The most common type arises from undifferentiated mesenchymal cells of the cremasteric muscle and vas deferens.<sup>1,4</sup> The epididymal form is less frequent and arises from the smooth muscle surrounding the basement membrane of the epididymis canal.<sup>4</sup> The dartos layer is the origin of the scrotal types. The first two aforementioned types drain into the retroperitoneal lymph nodes in contrast with the last type, which drains into the inguinal, external and internal iliac nodes. The most common mode of spread is lymphatic, followed by hematogenous and by local extension to scrotum, inguinal canal or pelvis.<sup>1</sup> Hematogenous metastases are primarily pulmonary or hepatic. Histologically, LMS is characterized by typical features of spindle cell neoplasm with fascicular architecture, foci of cytologic atypia, and mitoses. A large amount of necrosis is generally observed in high-grade tumors. Neoplastic cells immune-stain for smooth muscle actin and desmin.

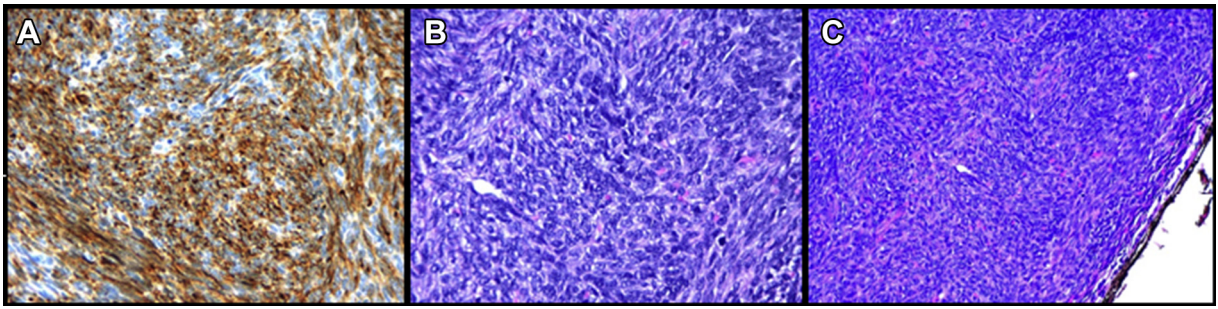
Paratesticular LMS is difficult to diagnose preoperatively and a definitive diagnosis requires a histologic examination of a resected specimen to observe morphological and immunohistochemical differentiation.

There is a lack of information on the natural history, histological criteria for diagnosis and recommendations for treatment because of the rarity of this disease.

Most paratesticular LMS present as painless, slow growing scrotal tumors, occasionally accompanied by a small hydrocele in men of middle or older age. In the physical examination, it is possible to define the size, mobility, consistency, location and relation to testis and epididymis. The findings are by no means specific to a tumor type and cannot distinguish between benign and malignant tumor or sometimes may be indistinguishable from testicular tumors, thus resulting in initial misdiagnosis. The age of the patient at presentation and the onset and duration of symptoms



**Figure 2.** During surgery, image of the right testis with the lesion (arrow).



**Figure 3.** Immunohistochemical pattern of studied tumor: (A) Desmin positivity 40 (B) Intermediate mitotic activity Hematoxylin-Eosin (HE) staining  $\times 40$  (C) Surgical margin with tumor, HE staining,  $40\times$ .

**Table 1**

French federation of cancer center sarcoma group grading system.

Tumor differentiation	
Score 1 sarcomas that closely resemble normal adult mesenchymal tissues.	
Score 2 sarcomas for which histologic typing is certain.	
Score 3 embryonal and undifferentiated sarcomas, synovial sarcoma, and sarcomas of uncertain differentiation.	
Mitotic count	
Score 1 0–9 mitoses/10 hpf	
Score 2 10–19 mitoses/10 hpf	
Score 3 $\geq 20$ mitoses/10 hpf	
Tumor necrosis	
Score 0 no necrosis.	
Score 1 $< 50\%$ tumor necrosis.	
Score 2 $\geq 50\%$ tumor necrosis.	
Histologic grade (tumor differentiation + mitotic count + tumor necrosis)	
Grade 1 (low grade)	Total score: 2 or 3
Grade 2 (intermediate grade)	Total score: 4 or 5
Grade 3 (high-grade)	Total score: 6, 7, or 8

FNCLCC, Fédération Nationale des Centres de Lutte Contre le Cancer; hpf, high-power field.

may provide helpful clues.<sup>5</sup> Ultrasound is the exam of choice in the initial management of a scrotal mass. In general, benign tumors are homogeneous and hyperechoic, whereas malignant ones are either homogeneously hypoechoic or have a heterogeneous pattern of hypo-hyperechoic areas with high vascularization. CT and magnetic resonance imaging are useful to delimitate the tumor extension. PET-CT is useful to see the nodal involvement.

The accepted treatment is radical inguinal orchiectomy, including the surrounding soft tissue; however, the optimal local

and systemic treatment remains controversial. No consensus with regard to regional lymph node excision has been reached, radiotherapy and chemotherapy. The tumor tends to show local recurrence as wide resection margins can be difficult to obtain in the paratesticular region (Fig. 1).

### Conclusion

This patient had a low grade leiomyosarcoma that had typical findings in the history, examination and went for the usual surgery. Although the good prognosis, is necessary long term follow-up to prevent recurrence and distant metastasis.

### Conflict of interest

None.

### References

1. Moloney James, Drumm John, Fanning Deirdre M. A rare case of paratesticular leiomyosarcoma. *Clin Pract.* 2012;2:e29. <http://dx.doi.org/10.4081/cp.2012.e29>.
2. Pérez Juan, Licham Milagros, Godoy Mariela, et al. Sarcomas paratesticulares en el paciente adulto. Manejo y evolución de la enfermedad. *Actas urológicas españolas.* 2009;33(6):639–645.
3. Unlu Yasar, Huq Gulben, Ozyalvacli Gulzade, et al. Paratesticular sarcomas: A report of seven cases. *Oncol Lett.* 2015;9:308–312.
4. Kyrtatzi Irene, Lolis Evangelos, Antypa Eleni, et al. Imaging features of a huge spermatic cord leiomyosarcoma: Review of the literature. *World J Radiol.* 2011 April 28;3(4):114–119.
5. Mechri M, Ghozzi S. A rare cause of scrotal mass: Primary leiomyosarcoma of epididymis. *BMJ Case Rep.* 2009.