


CASE REPORT

Seizures in activating calcium-sensing receptor antibodies positive autoimmune hypoparathyroidism and preponderance of steroids therapy: A case report

Qaisar Ali Khan¹  | Ameena Shahi¹ | Alishba Shahi² | Abdul Baqi³ | Tamara Tango⁴ | Ravina Verma⁵ | Asrah Abdul Hamid⁶ | Priyadharshini Saravanan⁷ | Mazhar Alam¹ | Ismail Khan Shinwari¹ | Hoor Ul Ain⁸

¹DHQ and Teaching Hospital KDA Kohat, Kohat, Pakistan

²Lady Reading Hospital Peshawar, Peshawar, Pakistan

³Mercy Saint Vincent Medical Centre, Toledo, Ohio, USA

⁴Faculty of Medicine Universitas, Indonesia, Indonesia

⁵St. George's University School of Medicine, St. George's, Grenada, West Indies

⁶Karachi Medical & Dental College, Karachi, Pakistan

⁷Pondicherry institute of Medical Sciences, Pondicherry, India

⁸Jinnah Medical College Peshawar, Peshawar, Pakistan

Correspondence

Ravina Verma, St. George's University School of Medicine, St. George's, Grenada, West Indies.
Email: ravinaverma51@gmail.com

Abstract

A 55-year-old female patient presented with generalized tonic-clonic seizures. Laboratory evaluation revealed low calcium (4.9 mg/dl), low PTH (0.9 pg/ml), and positive activating CaSR antibodies. The condition was diagnosed as autoimmune hypoparathyroidism. Calcium and vitamin D supplements did not correct the patient's hypocalcemia. The addition of prednisone to vitamin supplements showed a better response and corrected the hypocalcemia. The patient remained in seizure-free for one year.

KEYWORDS

autoimmune, case report, CaSR antibodies, hypoparathyroidism, seizure

1 | INTRODUCTION

Autoimmune hypoparathyroidism is a primary pathology of the parathyroid gland and involves the autoimmune destruction of the parathyroid gland. The condition is characterized by decreased level of parathyroid hormone (PTH) and low serum calcium that can lead to clinical signs and symptoms.¹ PTH maintains an adequate level of serum calcium in the serum by increasing bone resorption and

increasing renal tubular calcium reabsorption and promoting phosphate excretion from the kidney.² In addition, PTH also activates 1 alpha-hydroxylase enzyme in the kidney which activates vitamin D by hydroxylation at 1 position, the activated vitamin D then helps in the absorption of calcium from the small intestine.² Hypoparathyroidism can be primary hypoparathyroidism or secondary hypoparathyroidism, secondary causes of hypoparathyroidism includes thyroid surgery, cervical radiotherapy, genetic

This is an open access article under the terms of the [Creative Commons Attribution-NonCommercial-NoDerivs](https://creativecommons.org/licenses/by-nc-nd/4.0/) License, which permits use and distribution in any medium, provided the original work is properly cited, the use is non-commercial and no modifications or adaptations are made.

© 2023 The Authors. *Clinical Case Reports* published by John Wiley & Sons Ltd.

disorders (DiGeorge's syndrome, Bartter's syndrome, autosomal dominant hypocalcemia (ADH) 1 and ADH 2), autoimmune diseases (autoimmune polyglandular syndrome), idiopathic, the disorder of magnesium metabolism, and destruction of the parathyroid gland due to iron deposits, copper deposit, or tumor metastases.³

Autoimmune hypoparathyroidism is mainly diagnosed by measuring serum PTH and calcium level, biopsy is not routinely done but can confirm the diagnosis. Activating antibodies against calcium-sensing receptor (CaSR) is sometimes present in the serum and can support the diagnosis of autoimmune hypoparathyroidism.⁴ As low PTH leads to low serum calcium levels, hypoparathyroidism often presents with paresthesia, hyperreflexia (carpal spasms known as Trousseau's sign and facial spasms known as Chvostek's sign), cramps, or tetany. The disorder may manifest acutely with seizures, bronchospasm, laryngospasm, or cardiac rhythm disturbances.^{5,6}

2 | CASE REPORT

A 55-year-old Afghan woman was admitted to a tertiary care hospital with recurrent seizures. She had normal growth and development. She had her first episode of seizures with no obvious cause at the age of 20 years. The patient was put on antiepileptic drugs (sodium valproate 500 mg and levetiracetam 500 mg a day) by a local doctor in the village. Due to financial issues and limited resources, the patient did not undergo a neurology consultation or tertiary care hospital visit. Despite strict adherence to the medication prescribed, the patient's seizures did not resolve for 35 years. She also had a history of renal calculi and cataracts. She did not have any history of surgical procedures in the cervical region. The family history was unremarkable for seizures, other neurological disorders, and autoimmune diseases.

Her physical examination showed a positive Trousseau's sign and a Chvostek sign. The biochemical analysis (Table 1) revealed hypocalcemia and the brain imaging (Figure 1) demonstrated ependymal and basal ganglia calcification. Other causes of hypocalcemia were ruled out (Table 2) and a diagnosis of autoimmune hypoparathyroidism leading to hypocalcemia-induced seizures was made.

The patient was started on 600 mg oral calcium supplements twice a day, 50,000 IU of vitamin D2 weekly injection for 12 weeks, and 500 mg oral sodium valproate twice a day. The patient was advised to check her serum calcium level weekly. Despite these interventions, the patient's serum calcium level did not improve over eight weeks. Prednisone 60 mg once daily was added to the patient's regimen. After the addition of prednisone, the patient's

TABLE 1 Biochemical analysis revealed hypocalcemia

Investigation	Result	Reference Range
Hemoglobin	11.8 g/dl	12.0–16.0
Red blood cells	4.1×10^6 cells/mcl	$3.5\text{--}5.5 \times 10^6$
Total leukocyte count	5.6×10^3 cells/mcl	$4.5\text{--}11.0 \times 10^3$
Platelets	3.76×10^6 cells/mcl	$1.5\text{--}4.5 \times 10^6$
Random blood sugar	127 mg/dl	<200
Magnesium (Mg)	1.8 mg/dl	1.5–2.5
Serum calcium	4.9 mg/dl	7.5–10.0
Serum albumin	3.9 g/dl	3.5–5.5
Serum potassium	4.0 mEq/L	3.5–4.5
Serum sodium	138 mEq/L	135–145
Serum bicarbonate	24 mEq/L	22–26
Chloride	99 mEq/L	90–100
Serum creatinine	0.95 mg/dl	<1.5
Blood urea nitrogen (BUN)	22 mg/dl	5–25

Abbreviations: G/dl: gram per deciliter, mcl: microliter, mg/dl: milligram per deciliter, mEq/L: milli equivalent per liter.

calcium level was raised by 37% (4.9 to 7.8 mg/dl) over the next three weeks. Sodium valproate and prednisone were tapered off and the patient's serum calcium level was stable. The patient was continued on calcium 600 mg and cholecalciferol daily, and she remained seizure-free for one year.

3 | DISCUSSION

Seizures have a broad list of etiologies, including structural, genetic, infectious, metabolic, and immunological causes. Any patient presenting for the first time with seizures should be evaluated by taking a detailed history, doing the relevant clinical examination, and baseline investigations, including serum calcium and magnesium level.⁷ Autoimmune hypoparathyroidism is an endocrine disorder characterized by the autoimmune destruction of the parathyroid gland and indicated by hypocalcemia and low or undetectable levels of parathyroid hormone. Seizures in autoimmune hypoparathyroidism are secondary to hypocalcemia and can clinically present as a generalized tonic-clonic type. This unique case describes a patient in whom the secondary causes of hypoparathyroidism were absent. Although she had no family history of autoimmune disease, she experienced her first seizure in her 20s which makes autoimmune likely to be the etiology. This was supported by positive activating CaSR antibodies in this patient. The management of this case was unique because the patient did not respond to standard

FIGURE 1 Computed tomographic scan of the brain showing ependymal and bilateral basal ganglia calcifications represented by a white square

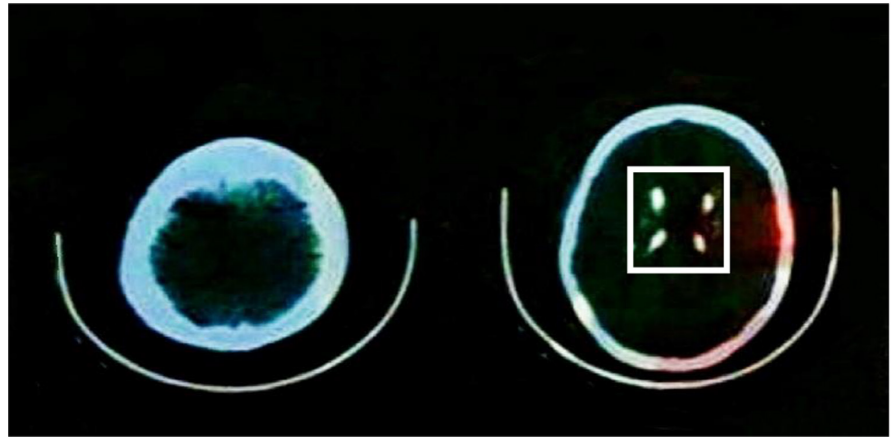


TABLE 2 Further investigation of hypocalcemia showed low PTH and positive CaSR antibodies

Investigation	Result	Reference Range
Parathyroid hormone (PTH)	0.9 pg/ml	10–65
Serum phosphate	7.8 mg/dl	2.5–4.5
Serum 25(OH) vitamin D level	33 ng/ml	20–45
Serum 1,25(OH) vitamin D3 level	11 pg/ml	20–78
Activating calcium-sensing receptor (CaSR)	Positive	-

Abbreviations: mg/dl: milligram per deciliter, ng/ml: nanogram per milliliter, Pg/ml: picogram per milliliter.

therapy of vitamin D and calcium until the addition of prednisone. The addition of prednisone to the supplements corrected the patient's serum calcium level over the period of three weeks. Tapering off the steroids did not change the patient's calcium level. That is why this patient was put on a long-term intake of vitamin D and calcium supplements.

Patients with hypoparathyroidism usually undergo initial examinations, such as electrolytes examination (serum Ca^{2+} and serum Mg^{2+}) and vitamin D measurement. Diagnosis of hypoparathyroidism relies on the measurement of the serum parathyroid hormone which can be absent or low. Further examinations may be performed to establish the underlying etiologies. Genetic screening among family members is conducted to look for genetic defects in the family. Bone biopsy and non-invasive high-resolution skeletal imaging are two modalities used for assessing the impact of hypoparathyroidism on the microarchitecture of the skeleton and the changes in the skeleton following the PTH treatment. Autoantibodies examinations may be performed when suspecting autoimmune hypoparathyroidism.⁸ Activating antibodies against calcium-sensing receptors (CaSR) is sometimes present in

the serum of patients with autoimmune hypoparathyroidism.^{9,10} The presence of these antibodies is not confirmatory because of their low sensitivity (39%) and specificity (83%).¹¹ CaSR, a G protein-coupled receptor whose role is to activate protein kinase C and ERK1/2 pathway which results in modulation of PTH secretion. Production of activating antibodies against CaSR further activates the CaSR which leads to a decreased production of PTH and manifests as hypoparathyroidism.^{12,13} Some patients with hypoparathyroidism also show calcification in the brain which is often evident on computed tomography scans of the brain incidentally. Like in our case these calcifications mainly involve basal ganglia, ventricles, or brain parenchyma. The condition is known as Fahr's syndrome in which hypoparathyroidism is one of the causes.¹⁴

Any etiologies of hypoparathyroidism are treated with the standard therapy of active vitamin D such as calcitriol and calcium supplements. If calcitriol is not available cholecalciferol can also be used. In addition, calcium supplements are given with a dose of 1 to 3 g in divided doses. The desired therapeutic result is to maintain the serum calcium close to the lower limit of the normal range.^{15,16} Moreover, there is an increased possibility of treating patients with CaSR antagonists or CaSR activators when patients are found to have activated or inactivated antibodies to the CaSR, respectively.¹⁵

The use of steroids to treat autoimmune hypoparathyroidism has been reported previously. Previous study by Chamberlin demonstrated the first evidence that a patient with CaSR antibody-mediated hypoparathyroidism who had been refractory to calcitriol and high-dose calcium supplements responded well to immunosuppressive therapy namely prednisone and azathioprine, indicated by improvement of hypocalcemia. The CaSR antibody disappeared following immunosuppressive therapy. Hypocalcemia relapsed when the dose of prednisone was decreased. Administration of high-dose calcitriol and calcium supplements during relapse resulted in hypercalcemia.⁴ The patient in this study had an improvement in

the seizure and improvement of hypocalcemia condition following the combination therapy. The limitation of our study is we did only qualitative testing of circulating CaSR antibodies, the change in the antibody levels has not been measured after administration of steroids. Thus, we did not know whether the combination therapy impacted the circulating CaSR antibodies.

4 | CONCLUSION

The addition of immunosuppressive therapy to the supplementations gives a better response compared to replacement therapy alone. Further study is needed to support the combination of steroids plus vitamins as the therapy for autoimmune hypoparathyroidism. In the future, the research should also compare the efficacy of combination therapy and immunosuppressive therapy alone, so that physicians can provide the best treatment for autoimmune hypoparathyroidism patients.

AUTHOR CONTRIBUTIONS

Qaisar Ali Khan: Conceptualization; data curation; writing – review and editing. **Ameena Shahi:** Conceptualization; data curation; formal analysis. **Alishba Shahi:** Conceptualization; data curation. **Abdul Baqi:** Writing – review and editing. **Tamara Tango:** Writing – review and editing. **Ravina Verma:** Writing – original draft. **Asrah Abdul Hamid:** Writing – original draft. **Priyadharshini Saravanan:** Writing – original draft. **Mazhar Alam:** Writing – original draft. **Ismail Khan Shinwari:** Writing – original draft. **Hoor Ul Ain:** Writing – original draft.

FUNDING INFORMATION

The study received no external funding.

CONFLICT OF INTEREST

There is no conflict of interest to declare.

DATA AVAILABILITY STATEMENT

The data that support the findings of this study are available from the corresponding author upon reasonable request.

ETHICAL APPROVAL

Not required

CONSENT

Written informed consent was obtained from the patient for publication of this case report and any accompanying images. A copy of written consent is available for review by the Editor-in-Chief of this journal.

GUARANTOR

Qaisar Ali Khan

ORCID

Qaisar Ali Khan  <https://orcid.org/0000-0001-8660-9551>

REFERENCES

1. Powers J, Joy K, Ruscio A, Lagast H. Prevalence and incidence of hypoparathyroidism in the United States using a large claims database. *J Bone Miner Res*. 2013;28(12):2570-2576. doi:10.1002/jbmr.2004
2. Khan N, Nawaz M, Ijaz A, et al. Biochemical spectrum of parathyroid disorders diagnosed at a tertiary care setting. *J Pak Med Assoc*. 2020;70(2):243-247. doi:10.5455/JPMA.302643153
3. Brandi ML, Bilezikian JP, Shoback D, et al. Management of Hypoparathyroidism: summary Statement and guidelines. *J Clin Endocrinol*. 2016;101(6):2273-2283. doi:10.1210/jc.2015-3907
4. Chamberlin M, Kemp EH, Weetman AP, Khadka B, Brown EM. Immunosuppressive therapy of autoimmune hypoparathyroidism in a patient with activating autoantibodies against the calcium-sensing receptor. *Clin Endocrinol*. 2018;90(1):213-221. doi:10.1111/cen.13886
5. de Arruda ACG, Guerra ACDZ, Pessoa CH, Marqueline GF, Delfino VDA. Hypoparathyroidism and Fahr's syndrome: case series. *Braz J Nephrol*. 2021;44:592-596. doi:10.1590/2175-8239-JBN-2020-0243
6. Bilezikian JP. Hypoparathyroidism. *J Clin Endocrinol*. 2020;105(6):1722-1736. doi:10.1210/clinem/dgaa113
7. Scheffer IE, Berkovic S, Capovilla G, et al. ILAE classification of the epilepsies: position paper of the ILAE Commission for Classification and Terminology. *Epilepsia*. 2017;58(4):512-521. doi:10.1111/epi.13709
8. Bilezikian JP, Khan A, Potts JT Jr, et al. Hypoparathyroidism in the adult: epidemiology, diagnosis, pathophysiology, target organ involvement, treatment, and challenges for future research. *J Bone Miner Res*. 2011;26(10):2317-2337. doi:10.1002/jbmr.483
9. Goswami R, Brown EM, Kochupillai N, et al. Prevalence of calcium sensing receptor autoantibodies in patients with sporadic idiopathic hypoparathyroidism. *Eur J Endocrinol*. 2004;150:9-18. doi:10.1530/eje.0.1500009
10. Mayer A, Ploix C, Orgiazzi J, et al. Calcium-sensing receptor autoantibodies are relevant markers of acquired hypoparathyroidism. *J Clin Endocrinol Metab*. 2004;89:4484-4489. doi:10.1210/jc.2004-0021
11. Habibullah MMA. *An Investigation of Autoantibodies against the Calcium-Sensing Receptor in Patients with Autoimmune Polyendocrine Syndrome Type 1*. PhD dissertation. The University of Sheffield; 2016.
12. Brown EM. Control of parathyroid hormone secretion by its key physiological regulators. In: Bilezikian JP, Marcus R, Levine MA, Marcocci C, Silverberg SJ, Potts JT, eds. *The Parathyroids: Basic and Clinical Concepts*. Elsevier; 2015:101-118.
13. Hauache OM. Extracellular calcium-sensing receptor: structural and functional features and association with diseases. *Braz J Med Biol Res*. 2001;34:577-584. doi:10.1590/s0100-879x2001000500004

14. Pesić M, Radojkovic D, Radenkovic S, Spasic M, Lukic S. Epileptic seizure as the first sign of hypoparathyroidism. *Vojnosanit Pregl*. 2011;68(1):81-84. doi:[10.2298/vsp1101081p](https://doi.org/10.2298/vsp1101081p)
15. Brown EM. Anti-parathyroid and anti-calcium sensing receptor antibodies in autoimmune hypoparathyroidism. *Endocrinol Metab Clin N Am*. 2009;38(2):437-445. doi:[10.1016/j.ecl.2009.01.001](https://doi.org/10.1016/j.ecl.2009.01.001)
16. Lupi I, Brancatella A, Cetani F, Latrofa F, Kemp EH, Marcocci C. Activating antibodies to the calcium-sensing receptor in immunotherapy-induced hypoparathyroidism. *J Clin Endocrinol*. 2020;105(5):1581-1588. doi:[10.1210/clinem/dgaa092](https://doi.org/10.1210/clinem/dgaa092)

How to cite this article: Khan QA, Shahi A, Shahi A, et al. Seizures in activating calcium-sensing receptor antibodies positive autoimmune hypoparathyroidism and preponderance of steroids therapy: A case report. *Clin Case Rep*. 2023;11:e6901. doi:[10.1002/ccr3.6901](https://doi.org/10.1002/ccr3.6901)