

Diffuse Sarcoidosis Masquerading as Widespread Malignant Disease: A Rare Case Report and Literature Review

Journal of Investigative Medicine High Impact Case Reports
Volume 8: 1–6
© 2020 American Federation for Medical Research
DOI: 10.1177/2324709620938942
journals.sagepub.com/home/hic


Pradnya Brijmohan Bhattad, MD¹ and Vinay Jain, MD²

Abstract

Sarcoidosis is a multisystem granulomatous disease commonly involving the lungs and mediastinal lymph nodes with the exact etiology being unclear. The simultaneous presence of malignant disease such as breast cancer and sarcoidosis has been reported. Sarcoidosis preceding a diagnosis of malignancy and that occurring years after treatment of malignant disease has been noted in the past. The presence of sarcoidosis in the setting of malignant disease carries a high risk of misdiagnosis. In this article, we report the case of a 45-year-old female with stage IA invasive ductal carcinoma of left breast that was in remission for 2 years; however, radiological imaging including magnetic resonance imaging of thoracic spine and positron emission tomography–computed tomography scanning were highly suspicious for malignant disease metastasis versus lymphoma with the widespread lymphadenopathy. Multiple tissue biopsies with histopathological evaluation allowed us to definitively exclude malignant disease metastasis and to correctly diagnose her atypical presentation of sarcoidosis.

Keywords

sarcoidosis, lymphoma, metastatic cancer, positron emission tomography/computed tomography, breast cancer

Sarcoidosis is a chronic systemic granulomatous disease of unknown etiology. Characteristic histological finding in sarcoidosis includes the presence of nonspecific, noncaseating granulomas.^{1–3} Increased incidence of sarcoidosis has been noted in females, African American race, and patients aged 20 to 40 years. Clinical presentation of sarcoidosis is variable according to the stage of the disease and degree of organ involvement; patients may be asymptomatic or may have varied clinical features (Table 1).^{3–6} Frequently, patients may have pulmonary manifestations, constitutional symptoms, visual disturbances, hepatosplenomegaly, peripheral adenopathy, dermatologic manifestations with arthralgias, and neurologic manifestations.^{3,4,7}

Sarcoidosis is often a diagnosis of exclusion. More than 90% of patients will have pulmonary involvement. Skin involvement occurs in about 25% of patients, and erythema nodosum is a common dermatologic manifestation.^{4,7,8} Erythema nodosum in sarcoidosis usually represents panniculitis and should not be biopsied to confirm a diagnosis of sarcoidosis. Diagnosis of sarcoidosis requires suggestive clinical, radiological findings along with exclusion of other conditions that present similarly and a tissue biopsy showing noncaseating granulomas.^{3,4,7,8}

Case Presentation

A 45-year-old female with a past medical history of stage IA invasive ductal carcinoma of left breast that was found

Table 1. Clinical Presentation of Sarcoidosis.^{1,3,5,6,7,16}

1. Respiratory system: cough, dyspnea, chest discomfort, and nonproductive cough
2. Constitutional symptoms: fatigue, weight loss, malaise, and anorexia
3. Skin involvement: erythema nodosum, macules, papules, subcutaneous nodules, and hyperpigmentation
4. Ocular symptoms: conjunctivitis, uveitis, iritis, and blurred vision
5. Hepatosplenomegaly, peripheral lymphadenopathy
6. Myocardial involvement: cardiomyopathy, arrhythmias
7. Arthralgias can be seen in about 40% of cases
8. Neurological symptoms: meningeal involvement, hypothalamic and pituitary lesions, and diabetes insipidus

to be estrogen receptor and progesterone receptor positive; HER 2 neu oncogene nonamplified by fluorescence in situ hybridization diagnosed 2 years ago status post left

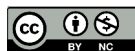¹East Tennessee State University, Johnson City, TN, USA

²James H. Quillen Veterans Affairs Medical Center, Mountain Home, TN, USA

Received May 20, 2020. Revised May 31, 2020. Accepted June 3, 2020.

Corresponding Author:

Pradnya Brijmohan Bhattad, MD, Department of Internal Medicine, East Tennessee State University, Skyline Drive, Johnson City, TN 37604, USA.
Email: pradnyabhattad20@gmail.com



lumpectomy and adjuvant radiation therapy to whole left breast and treated with Tamoxifen therapy. Screening mammogram showed stable postoperative changes in left breast with benign findings. The patient has been in remission for 2 years. She reported mid-low back pain, new-onset skin lesions over bilateral palms, which appeared to be whitish subcutaneous nodules over her palms for a duration of 6 months. Review of systems, physical examination, and vital signs were otherwise unremarkable. Six months prior, the patient had an episode of acute on chronic left elbow olecranon bursitis that was confirmed by histopathology. Laboratory evaluation revealed as follows: cancer antigen (CA) levels were 27.29 units (reference = 0.0-38.6 units). Complete blood count, comprehensive metabolic panel, serum phosphorous, serum magnesium, serum uric acid, serum lactate dehydrogenase, serum 25 OH vitamin D, serum vitamin B₁₂, and serum thyroid-stimulating hormone levels were within normal limits. C-reactive protein was only minimally elevated at 7.1 mg/L (Ref. = 0-5 mg/L). Serum CA15 was within normal limits at 17.3 units (Ref. = 0.0-25). Erythrocyte sedimentation rate was mildly elevated at 43 mm/h. Angiotensin-converting enzyme levels were noted to be in the normal range at 29 U/L (Ref. = 14-82 U/L).

Magnetic resonance imaging (MRI) thoracic spine without contrast was obtained to evaluate patient's back pain. MRI thoracic spine showed numerous clustered supraclavicular, mediastinal, hilar, and upper abdominal lymph nodes suspicious for nodal metastases along with sub centimeter T1 hypointense right vertebral body lesions at T11 and L1, suspicious for bone metastases. MRI thoracic spine findings were suspicious for malignancy and given the patient's recent history of breast cancer, she underwent further evaluation by positron emission tomography-computed tomography (PET-CT). F-18 fludeoxyglucose (FDG) whole body PET-CT demonstrated multiple significantly enlarged mediastinal lymph nodes in the superior mediastinum, paratracheal region, AP window, prevascular, and subcarinal regions. There were multiple enlarged bilateral hilar, cardio phrenic lymph nodes. Prominent lymphadenopathy was noted along the peripancreatic, periportal, gastrohepatic ligament, retrocrural, splenic hilum, periaortic, mesenteric, left common iliac, bilateral external iliac, and left internal iliac regions. A focal splenic lesion measuring 1.5 cm with high normal spleen size was noted. Multiple lung nodules measuring up to 1 cm in the left upper lobe were found. Bony lesions involving T11, L1 vertebral bodies, and pedicle of T1 vertebral body were seen. These widespread lesions on PET-CT were highly suspicious for lymphoma/metastasis. Hepatomegaly was noted as well. As a result, the patient underwent single-photon emission computerized tomography (SPECT) of the thoracic and lumbar spine, which showed no scintigraphic evidence of osteoblastic metastatic disease, no abnormal uptake in the areas of increased FDG uptake involving the T1 spinous process, T11 or L1 vertebral bodies.

As the patient was found to have diffuse lymphadenopathy from neck down to iliac chains with significant standardized uptake values (SUV) with increased activity at T11, L1 on PET-CT scan, she underwent multiple tissue biopsies.

Refer to Figures 3 to 12 for PET-CT and MRI thoracic spine images.

Endobronchial biopsy of left lower lobe, bronchial brushing of left upper lobe, bronchial washing, left hilar, subcarinal, and right paratracheal samples showed no evidence of malignancy and reported as benign bronchial mucosa with non-caseating granulomatous inflammation. Refer to Figure 2 for the histopathological finding of the noncaseating granuloma in our patient. Grocott-Gomori's (or Gömöri) methenamine silver stain, periodic acid-Schiff stain were unremarkable. No fungal, acid-fast microorganisms were noted on microscopy of lung tissue. Morphological, histochemical, immunohistochemical, and flow cytometric evaluation demonstrated no evidence of malignancy in supraclavicular lymph node sample. The patient also underwent T11 bone lesion biopsy with CT guidance. Flow cytometric analysis of T11 vertebral bone biopsy, transbronchial fine needle aspiration, and right supraclavicular fine needle aspiration showed no significant lymphoid immunophenotypic abnormalities. Refer to Figure 1 for a summary of diagnostic workup. The patient was referred for rheumatologic evaluation in the interim, which was deferred due to high suspicion of malignancy given the widespread lymphadenopathy, history of breast cancer until cleared by oncology. As sarcoidosis is a diagnosis of exclusion, our patient underwent extensive evaluation with multiple tissue biopsies to definitively rule out malignancy, especially given the history of breast malignancy and presence of widespread radiographically suspicious lesions. As the patient was definitively excluded of malignant disease with the tissue biopsy findings consistent with noncaseating granulomas and overall presentation with a history of olecranon bursitis, skin lesions on palms, the patient was diagnosed with widespread sarcoidosis that was mimicking malignant disease. Based on overall clinical presentation and patient preference, the patient was not started on steroids on confirmatory diagnosis. The patient has been set up for further management of sarcoidosis and will be followed in an outpatient setting.

Discussion

Diagnosis of sarcoidosis requires compatible clinical and radiographic manifestations, exclusion of other diseases with similar presentation, and a histopathological evidence of noncaseating granulomas.^{7,9,10} Diagnostic tissue sampling should be obtained from the most accessible site of a suspected lesion such as lymph nodes or skin lesions with the exception of erythema nodosum.^{8,10,11} For mediastinal lymph node sampling, endobronchial ultrasound with nodal aspiration is the preferred initial method. Some infectious diseases

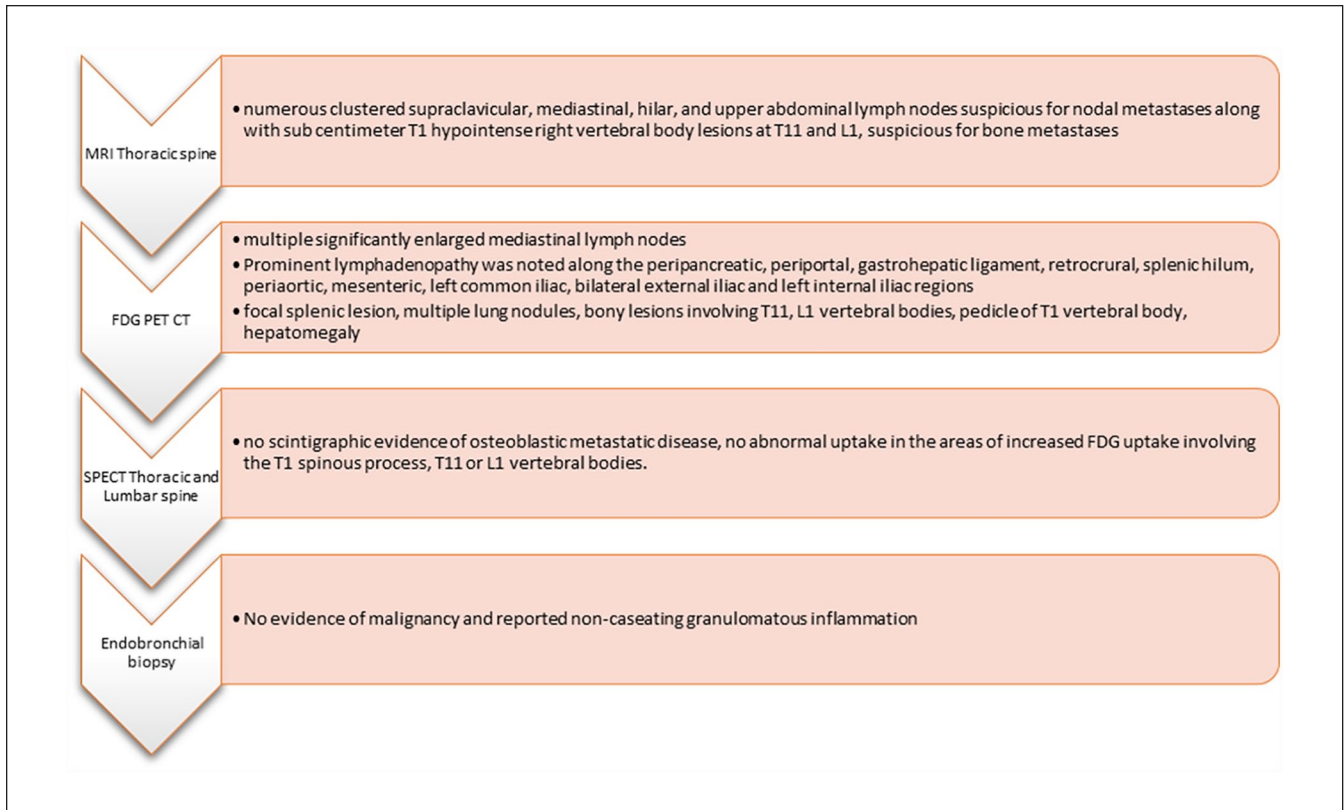

Figure 1. Summary of diagnostic workup.

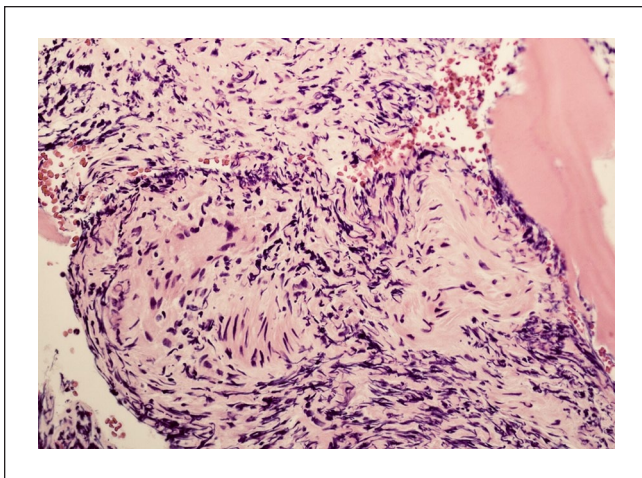


Figure 2. The characteristic pathologic lesion of sarcoidosis is the non-necrotizing granuloma.

such as histoplasmosis or active tuberculosis can present similar to sarcoidosis and hence exclusion of these causes is required.^{8,11,12} PET scanning usually detects cells with high metabolic activity and is helpful to differentiate pathologic lymph nodes from the non-pathologic ones. Sarcoidosis often causes positive PET results and thus, PET testing cannot differentiate sarcoidosis from lymphomas. Mediastinoscopy with

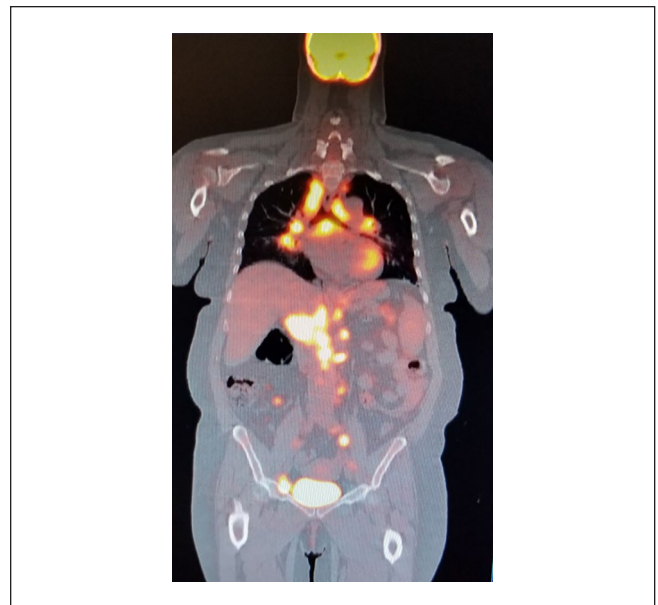


Figure 3. PET-CT demonstrating widespread lesions highly suspicious for lymphoma/metastasis.

excisional biopsy is a second-line diagnostic method if endobronchial ultrasound with nodal aspiration does not confirm sarcoidosis (Table 2).^{7,9,13,14}

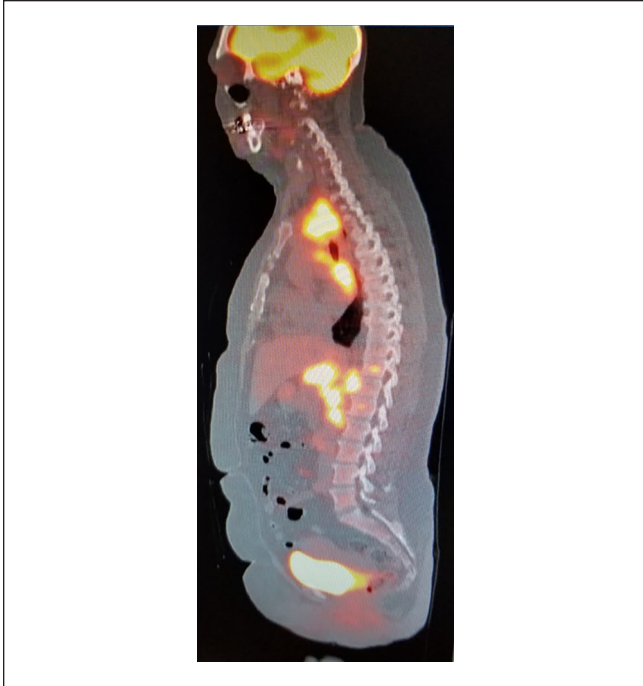


Figure 4. PET-CT demonstrating widespread lesions highly suspicious for lymphoma/metastasis.

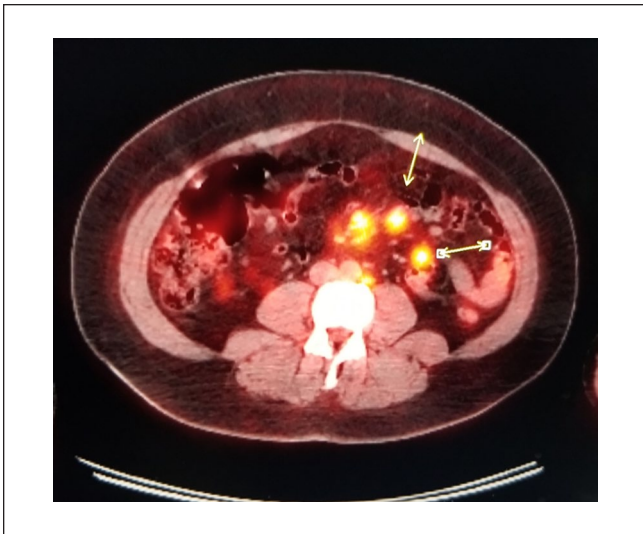

Figure 5. Widespread lesions on PET-CT highly suspicious for lymphoma/metastasis.

A majority of patients with sarcoidosis are expected to have spontaneous remission in 2 years and hence usually do not require any treatment. Patients are closely followed-up with chest X-rays, pulmonary function tests, and clinical evaluation.^{3,7,8,15,16} Corticosteroid therapy is used in patients who have severe symptoms, hypercalcemia, neurologic or cardiovascular or ocular involvement, and progressive pulmonary disease. If patients have refractory disease not

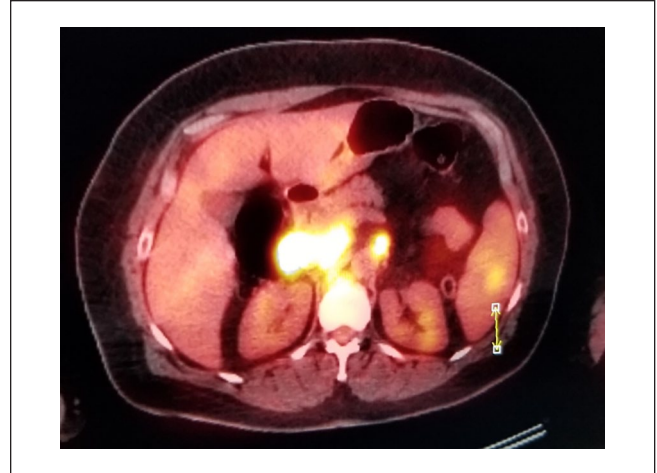

Figure 6. PET-CT demonstrating focal splenic lesion.

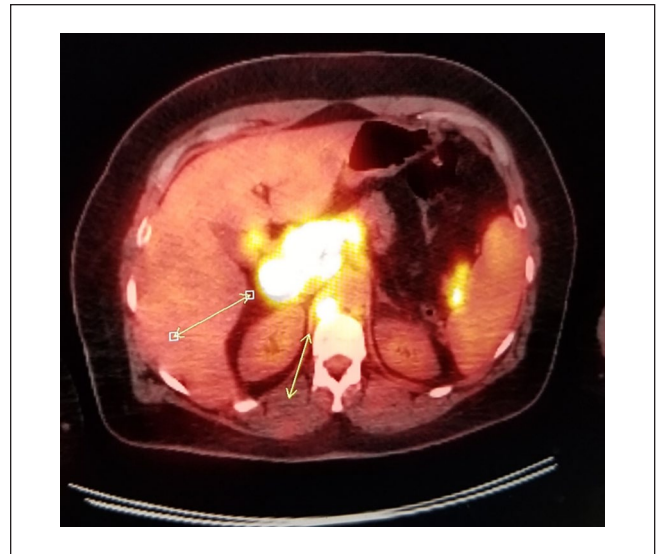

Figure 7. Widespread lesions on PET-CT highly suspicious for lymphoma/metastasis.

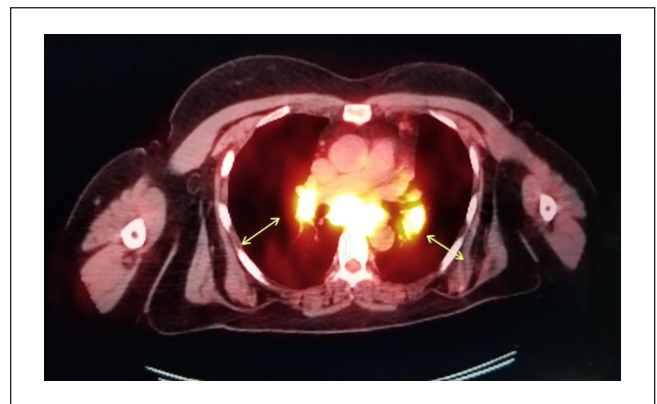


Figure 8. Widespread lesions on PET-CT highly suspicious for lymphoma/metastasis.

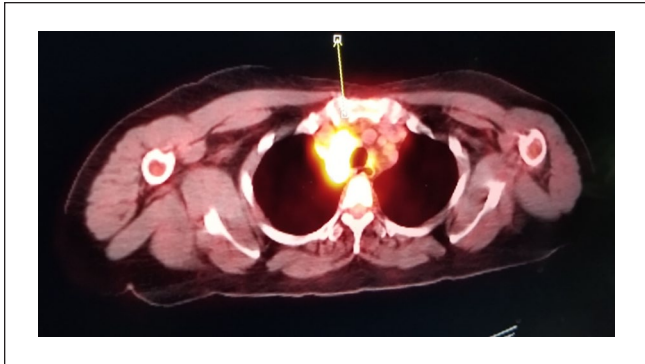


Figure 9. Widespread lesions on PET-CT highly suspicious for lymphoma/metastasis.

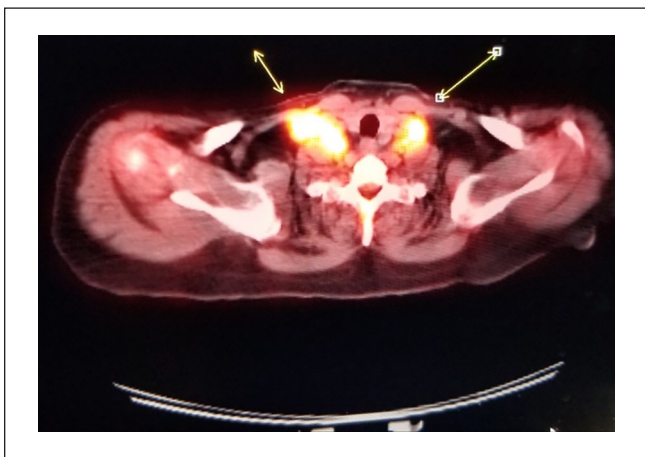

Figure 10. Widespread lesions on PET-CT highly suspicious for lymphoma/metastasis.

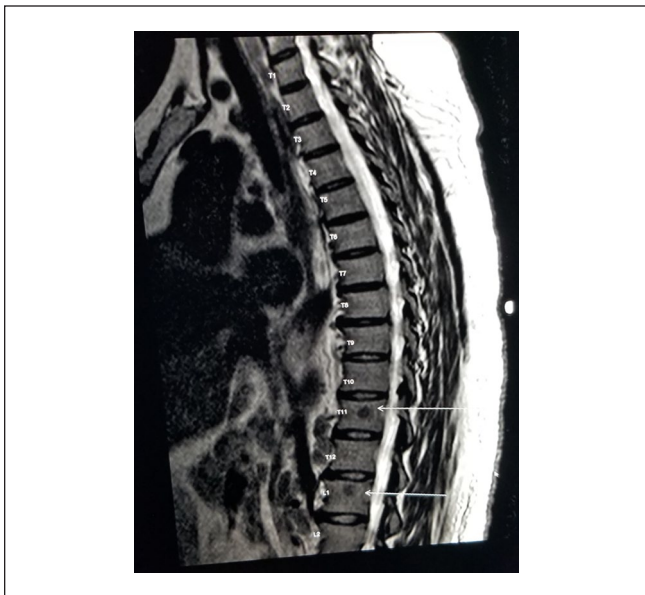


Figure 11. MRI thoracic spine showing vertebral body lesions at T11 and L1, suspicious for bone metastases.

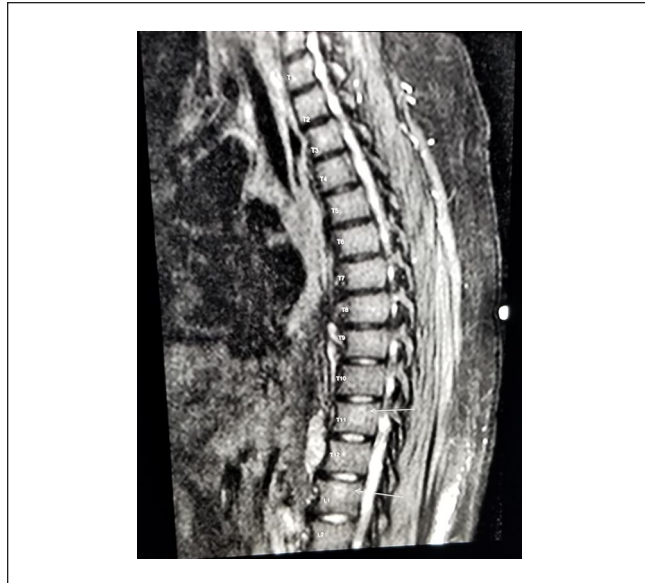

Figure 12. MRI thoracic spine showing vertebral body lesions at T11 and L1, suspicious for bone metastases.

Table 2. Diagnostic Studies for Sarcoidosis.^{1,3,5-8,17}

1. Chest X-ray may show adenopathy of hilar and paratracheal nodes, parenchymal changes.
2. Laboratory evaluation findings include anemia, leukopenia, abnormal liver function tests, hypercalcemia, and hypercalciuria. Angiotensin-converting enzyme is elevated in around 60% of patients with sarcoidosis although it is nonspecific.
3. Pulmonary function tests may be normal or may show restrictive or obstructive pattern.
4. Gallium-67 scan is helpful to localize areas of granulomatous infiltrates.
5. Ophthalmologic examination is required in all patients with suspected sarcoidosis and ocular findings, such as uveitis, conjunctivitis, are common.
6. Biopsy is usually done on accessible tissues that are suspected to have some quite involvement such as skin, lymph nodes. Bronchoscopy with transbronchial biopsy is the procedure of choice for those cases who do not have an easily accessible site for biopsy.

responding to corticosteroids with progression, methotrexate may be useful. Nonsteroidal anti-inflammatory agents are used for erythema nodosum, arthralgias.^{4,7,8,14,17,18}

Conclusion

Sarcoidosis is likely to give abnormal PET scan results and would be difficult to differentiate malignant disease, lymphoma from sarcoidosis based on radiographic findings alone. A diagnosis of sarcoidosis is made only after excluding all other possible similar presentations. Diagnosis of sarcoidosis may become difficult in scenarios where patient had

a recent malignant disease and radiographic evaluation suggesting widespread suspicious disease. Tissue sampling with a histopathological evidence of noncaseating granulomas and exclusion of other causes is required to make a diagnosis of sarcoidosis.

Our patient in this case had a history of breast cancer that was treated with no previous diagnosis of sarcoidosis was found to have widespread lesions on PET/CT imaging, MRI imaging, and the findings on these radiological studies were highly suspicious for malignancy. Multiple tissue biopsies from suspicious lesions were negative for malignancy and she was found to have granulomatous disease. Thus, it becomes important to note that the lesions suspicious for malignancy in radiological studies despite a history of cancer may not always be metastatic or malignant disease and granulomatous disease can be a differential.

Declaration of Conflicting Interests

The author(s) declared no potential conflicts of interest with respect to the research, authorship, and/or publication of this article.

Funding

The author(s) received no financial support for the research, authorship, and/or publication of this article.

Ethics Approval

Ethical approval to report this case was obtained from Department of Veterans Affairs VA, Form 0897.

Informed Consent

Verbal informed consent was obtained from the patient for their anonymized information to be published in this article.

References

- Cohen PR, Kurzrock R. Sarcoidosis and malignancy. *Clin Dermatol*. 2007;25:326-333.
- Tolaney SM, Colson YL, Gill RR, et al. Sarcoidosis mimicking metastatic breast cancer. *Clin Breast Cancer*. 2007;7:804-810.
- Baughman RP, Culver DA, Judson MA. A concise review of pulmonary sarcoidosis. *Am J Respir Crit Care Med*. 2011;183:573-581.
- Ataerigin S, Arslan N, Ozet A, Ozguven MA. Abnormal 18F-FDG uptake detected with positron emission tomography in a patient with breast cancer: a case of sarcoidosis and review of the literature. *Case Rep Med*. 2009;2009:785047.
- Judson MA. Advances in the diagnosis and treatment of sarcoidosis. *F1000Prime Rep*. 2014;6:89.
- Wessendorf TE, Bonella F, Costabel U. Diagnosis of sarcoidosis. *Clin Rev Allergy Immunol*. 2015;49:54-62.
- Iannuzzi MC, Rybicki BA, Teirstein AS. Sarcoidosis. *N Engl J Med*. 2007;357:2153-2165.
- Meillier A, Comodore M. Sarcoidosis: a diagnostic challenge in atypical radiologic findings of unilateral lymphadenopathy. *Oxf Med Case Reports*. 2015;2015:376-377.
- Ito T, Okada T, Murayama K, et al. Two cases of sarcoidosis discovered accidentally by positron emission tomography in patients with breast cancer. *Breast J*. 2010;16:561-563.
- Takanami K, Kaneta T, Yamada T, et al. FDG PET for esophageal cancer complicated by sarcoidosis mimicking mediastinal and hilar lymph node metastases: two case reports. *Clin Nuclear Med*. 2008;33:258-261.
- Kunstmann L, Bständig B, Brucker-Davis F, Mouroux J, Rigot P, Fenichel P. Malignant struma ovarii: false positive PET image for suspected metastasis due to sarcoidosis [in French]. *Ann Endocrinol (Paris)*. 2007;68:51-54.
- Muggia FM, Conti PS. Seminoma and sarcoidosis: a cause for false positive mediastinal uptake in PET? *Ann Oncol*. 1998;9:924.
- Treglia G, Taralli S, Giordano A. Emerging role of whole-body ¹⁸F-fluorodeoxyglucose positron emission tomography as a marker of disease activity in patients with sarcoidosis: a systematic review. *Sarcoidosis Vasc Diffuse Lung Dis*. 2011;28:87-94.
- Brito-Zeron P, Pérez-Alvarez R, Pallarés L, et al. Sarcoidosis: an update on current pharmacotherapy options and future directions. *Expert Opin Pharmacother*. 2016;17:2431-2448.
- Ramadas P, Krishnan P, Pandita A, Paul M, Curtiss C, Gajra A. Lung cancer or sarcoidosis: a diagnostic dilemma. *J Cancer Ther Res*. 2016;5:2.
- Dubrey S, Shah S, Hardman T, Sharma R. Sarcoidosis: the links between epidemiology and aetiology. *Postgrad Med J*. 2014;90:582-589.
- Silva M, Nunes H, Valeyre D, Sverzellati N. Imaging of sarcoidosis. *Clin Rev Allergy Immunol*. 2015;49:45-53.
- Baughman RP, Lower EE. Treatment of sarcoidosis. *Clin Rev Allergy Immunol*. 2015;49:79-92.