

## CASE REPORT OPEN



# Somatic and germline analysis of a familial Rothmund–Thomson syndrome in two siblings with osteosarcoma

Miriam Gutiérrez-Jimeno<sup>1</sup>, Elena Panizo-Morgado<sup>1</sup>, Ibon Tamayo<sup>2</sup>, Mikel San Julián<sup>3</sup>, Ana Catalán-Lambán<sup>1</sup>, Marta M. Alonso<sup>1,4</sup> and Ana Patiño-García<sup>1,4</sup>✉

Rothmund–Thomson syndrome (RTS) is characterized by a rash that begins in the first few months of life and eventually develops into poikiloderma. Associated symptoms are alterations in the teeth, sparse hair, thin eyebrows, lack of eyelashes, low stature, bone abnormalities, hematological illnesses, gastrointestinal disease, malnutrition, cataracts, and predisposition to cancer, principally to bone tumors and skin cancer. Diagnostic certitude is provided by a genetic study involving detection of pathogenic variants of the *RECQL4* gene. We hereby present a familiar case of RTS in two siblings from a Portuguese family, both diagnosed with osteosarcoma. Genomic analysis (203 genes) of both tumors as well as germline analysis of the *RECQL4* gene, thus confirming the syndrome in the family, have been performed. The relevance of clinical recognition of the hallmarks of the disease and thus early diagnosis with early intervention is highlighted.

npj Genomic Medicine (2020)5:51; <https://doi.org/10.1038/s41525-020-00160-x>

## INTRODUCTION

Rothmund–Thomson syndrome (RTS) is an autosomal-recessive genodermatosis with clinical symptoms that develop in early infancy. Symptoms include cutaneous alterations (typically, facial erythema and poikiloderma), hair loss, cataracts, growth delay, skeletal anomalies, premature aging, and an inherited predisposition to cancer (mainly pediatric osteosarcoma)<sup>1–5</sup>. There are few cases described in the literature; most reported cases are from isolated individuals.

Patients who are at the highest risk of developing tumors are those with homozygous or compound heterozygous mutations at the *RECQL4* gene, which belongs to the RecQ helicase family<sup>5</sup>.

We describe the cases of two siblings with confirmed germline compound heterozygous *RECQL4* mutations and with diagnoses of osteosarcoma. The segregation of the mutations in the parents has been analyzed and genomic somatic analysis of both tumors performed.

## RESULTS

### Description of the cases

**Case #1.** Case #1 is the first child (female) of non-consanguineous Portuguese parents. Delivery was at term after a normal pregnancy. Birth weight was 2880 g, and height 25 cm (<p3). Neurodevelopment was normal. The patient was initially studied because of her low height. Bone age corresponded to her chronological age, and insulin-like growth factor-1 (IGF-1) and IGF binding protein-3 (IGFBP-3) levels were normal. The patient was subsequently attended to for facial poikiloderma with telangiectasia. Limbs were treated with laser therapy. Bone X-rays revealed diffuse demineralization. Blood tests found vitamin D deficiency. Comparative genomic hybridization yielded normal results.

At 6 years of age, the patient was attended to at a referral center because, for the previous month, she had had a pain in her right knee that interfered with her sleep. On the basis of computed tomography (CT), X-ray, and nuclear magnetic resonance (MR) imaging and a biopsy, the diagnosis made was of osteosarcoma of the distal right femur, involving both the metaphysis and epiphysis, without distant metastatic disease. Neo-adjuvant chemotherapy with the EURAMOS1 regimen was initiated, and amputation was advised. This regimen consists of two cycles of intravenous methotrexate (12 g/m<sup>2</sup>), Adriamycin (75 mg/m<sup>2</sup>), and cisplatin (120 mg/m<sup>2</sup>) before surgery (MAP therapy). Since the parents wanted to avoid amputation, they switched treatment center. In our center, treatment proceeded with preoperative intra-arterial cisplatin (150 mg/m<sup>2</sup>) and intravenous Adriamycin (100 mg/m<sup>2</sup>) plus vincristine (one dose of 1 mg). After neo-adjuvant treatment, limb-sparing surgery, consisting of tumor resection with distal femur reconstruction with an osteoarticular allograft, was performed. The pathology of the resected tumor was consistent with osteoblastic osteosarcoma of the distal femur with 95% tumor necrosis. Adjuvant chemotherapy was not administered because of the high degree of hematologic toxicity (grade 4 febrile neutropenia) of the neo-adjuvant treatment and because, as a result of receiving additional cycles of neo-adjuvant chemotherapy, the patient had already been subjected to higher final concentrations of anti-neoplastic drugs than those received by other patients under the same regimen.

The patient has been in clinical remission since the end of treatment (3 years and 4 months). She uses a 6.5 cm lift to compensate for bone length dysmetria due to the pathologic fracture of her sarcoma (previous to tumor resection). Further surgery will be required in the future.

<sup>1</sup>Department of Pediatrics, University Clinic of Navarra, Pamplona, Spain. <sup>2</sup>Computational Biology Program, CIMA, Center for Applied Medical Research, Pamplona, Spain.

<sup>3</sup>Department of Traumatology, University Clinic of Navarra, Pamplona, Spain. <sup>4</sup>Solid Tumor Program, CIMA, Center for Applied Medical Research and IdiSNA, Pamplona, Spain.

✉email: [apatigar@unav.es](mailto:apatigar@unav.es)

**Case #2.** Case #2 is the younger brother of case #1. Medical examinations and tests revealed nothing of relevance except for growth delay (less than the third percentile,  $-3SD$ ) despite normal IGF-1 and IGBP-3 levels. The patient was macrocephalic, but by brain MR there were no major alterations. He was diagnosed with celiac disease. Anti-peroxidase and anti-thyroglobulin antibody tests were positive. Thyroid function and thyroid echography were normal. He tested positive for anti-transglutaminase immunoglobulin A (IgA) and IgG.

At 5 years of age, he was attended to in our institution, where MR and CT imaging revealed cysts in the right femur and tibia. There was no indication that these cysts were aggressive. Three months later, however, he complained of pain in the medial face of the proximal right tibia. A biopsy was obtained, and a diagnosis of osteoblastic osteosarcoma of the proximal tibia was established. Additional tests were performed with no evidence of distant metastatic disease. Neo-adjuvant chemotherapy was initiated, with three cycles of intra-arterial cisplatin and intravenous Adriamycin. The tumor was resected. Pathologically, the resected piece was a 100% necrotic osteoblastic osteosarcoma. Adjuvant chemotherapy

was initiated according to the MAP protocol, but, due to the toxicity of high-dose methotrexate, the patient suffered acute liver failure (hypertransaminasemia, hyperbilirubinemia, and coagulopathy), which required treatment with cholestyramine and activated charcoal, and thus chemotherapy was changed to cisplatin with Adriamycin.

The patient was in remission from February to August 2020, when lung metastases (two nodules in the left lung) were detected during scheduled follow-up. Further tests and lung metastasectomy are pending.

Table 1 gives the clinical characteristics of both patients with respect to the clinical signs indicative of a diagnosis of RTS.

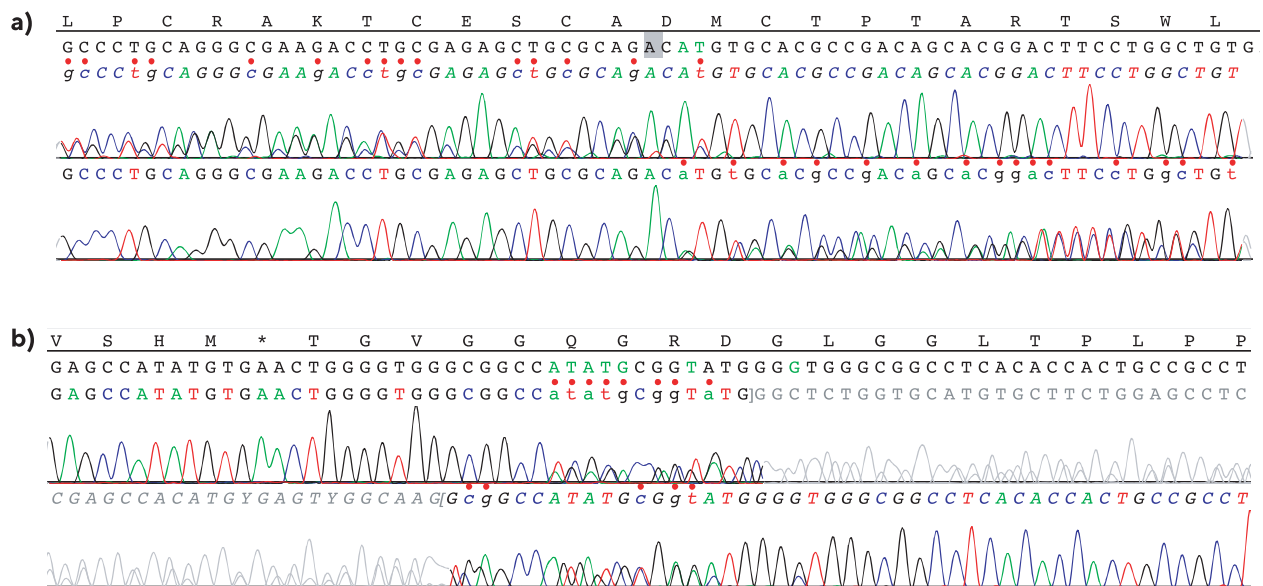
#### Germline genetic analysis

Because both siblings had osteosarcoma, we gave genetic counseling and sequenced germline *RECQL4* genes to test for RTS.

Both siblings were found to be compound heterozygotes for mutations c.1878+32\_1879-27del24 (p.(?)) in intron 11 and c.2492\_2493delAT (p.(His831Argfs\*52)) in exon 15 of the *RECQL4*

**Table 1.** Clinical characteristics of our patients in relation to the clinical signs of RTS.

Clinical sign	Case #1 (sister)	Case #2 (brother)
Erythema on the cheeks and face	Present	Present
Poikiloderma	Present	Present
Sparse scalp hair, eyelashes, and/or eyebrows	Present	Present
Small size, usually symmetric for height and weight	Present	Present
Gastrointestinal disturbance as a young child: chronic vomiting and diarrhea	Present	Present
Dental abnormalities: hypoplastic teeth, enamel defects, delayed tooth eruption	Absent	Absent
Nail abnormalities: dysplastic or poorly formed nails	Absent	Absent
Hyperkeratosis (soles of the feet)	Absent	Absent
Cataracts	Absent	Absent
Skeletal abnormalities: radial ray defects, ulnar defects, absent or hypoplastic patella, osteopenia, abnormal trabeculation	Present	Present
Cancers including skin cancers: basal cell carcinoma, squamous cell carcinoma, osteosarcoma	Present	Present



**Fig. 1** *RECQL4* mutation sequencing. Sanger sequencing of the germline *RECQL4* mutations present in both cases, showing the presence of mutations **a** c.2492\_2493delAT, p.(His831Argfs\*52) and **b** c.1878+32\_1879-27del24 (p.(?)).



Biosystems®. The obtained reads were compared to the consensus sequence of the gene (GenBank Accession Number: NM\_004260.3).

### Somatic genomic analysis

DNA and RNA were extracted from non-decalcified tissue from the diagnostic true-cut biopsy samples of both siblings. Genomic analysis used the OncoPrint™ Childhood Cancer Research Assay from Thermo Fisher; this is an NGS assay based on a 203-gene library. The assay consists on a large translocation/fusion RNA panel for 97 genes (with >1700 fusion isoform variants) and a DNA panel for 82 targets with comprehensive coverage of relevant mutations, 44 targets with full exon coverage (specifically tumor-suppressor genes), and 24 copy number variant targets (Supplementary Table 1). Note that the somatic NGS panel does not include the coding sequence of *RECQL4*, presumably because this gene is currently only useful for diagnosis of RTS syndrome.

### Ethics approval

The genomic analysis of our patients was part of their clinical management in the Clínica Universidad de Navarra. The detailed protocol and publication plan were explained to the parents who signed written informed consent to take part in the study.

### Reporting summary

Further information on research design is available in the Nature Research Reporting Summary linked to this article.

### DATA AVAILABILITY

The datasets generated during and/or analyzed during the current study, corresponding to the DNA genomic analysis, have been uploaded to the SRA database under BioProject accession PRJNA663851 (submission SUB8148545).

Received: 8 August 2020; Accepted: 29 October 2020;

Published online: 04 December 2020

### REFERENCES

- Larizza, L., Roversi, G. & Volpi, L. Rothmund-Thomson syndrome. *Orphanet J. Rare Dis.* **5**, 2 (2010).
- Wang, L. L. et al. Association between osteosarcoma and deleterious mutations in the *RECQL4* gene in Rothmund-Thomson syndrome. *J. Natl Cancer Inst.* **95**, 669–674 (2003).
- Lindor, N. M. et al. Rothmund-Thomson syndrome due to *RECQ4* helicase mutations: report and clinical and molecular comparisons with Bloom syndrome and Werner syndrome. *Am. J. Med. Genet.* **90**, 223–228 (2000).
- Zils, K. et al. Osteosarcoma in patients with Rothmund-Thomson syndrome. *Pediatr. Hematol. Oncol.* **32**, 32–40 (2015).
- Wang, L. L. & Plon, S. E. *Rothmund-Thomson Syndrome*. GeneReviews (University of Washington, Seattle, Seattle, WA, 2020).
- Cao, F. et al. Generalized metabolic bone disease and fracture risk in Rothmund-Thomson syndrome. *Hum. Mol. Genet.* **26**, 3046–3055 (2017).
- Colombo, E. A. et al. Rothmund-Thomson syndrome: insights from new patients on the genetic variability underpinning clinical presentation and cancer outcome. *Int. J. Mol. Sci.* **19**, 1103 (2018).
- Kitao, S. et al. Mutations in *RECQL4* cause a subset of cases of Rothmund-Thomson syndrome. *Nat. Genet.* **22**, 82–84 (1999).
- He, M. Y. et al. Screening of *RB1* gene mutations in Chinese patients with retinoblastoma and preliminary exploration of genotype-phenotype correlations. *Mol. Vis.* **20**, 545–552 (2014).
- Lu, K. H. et al. American Society of Clinical Oncology Expert Statement: collection and use of a cancer family history for oncology providers. *J. Clin. Oncol.* **32**, 833–840 (2014).
- Chen, X. et al. Recurrent somatic structural variations contribute to tumorigenesis in pediatric osteosarcoma. *Cell. Rep.* **7**, 104–112 (2014).
- Sayles, L. C. et al. Genome-informed targeted therapy for osteosarcoma. *Cancer Discov.* **9**, 46–63 (2019).
- Suehara, Y. et al. Clinical genomic sequencing of pediatric and adult osteosarcoma reveals distinct molecular subsets with potentially targetable alterations. *Clin. Cancer Res.* **25**, 6346–6356 (2019).
- Bielack, S. S. et al. Prognostic factors in high-grade osteosarcoma of the extremities or trunk: an analysis of 1,702 patients treated on neoadjuvant cooperative osteosarcoma study group protocols. *J. Clin. Oncol.* **20**, 776–790 (2002).
- Whelan, J. S. et al. Survival from high-grade localised extremity osteosarcoma: combined results and prognostic factors from three European Osteosarcoma Intergroup randomised controlled trials. *Ann. Oncol.* **23**, 1607–1616 (2012).
- Hicks, M. J., Roth, J. R., Kozinetz, C. A. & Wang, L. L. Clinicopathologic features of osteosarcoma in patients with Rothmund-Thomson syndrome. *J. Clin. Oncol.* **25**, 370–375 (2007).
- Wise, J. Genome sequencing of children promises a new era in oncology. *BMJ* **364**, 1105 (2019).

### ACKNOWLEDGEMENTS

We are indebted to the SL family for their confidence and their agreement to participate in this research. This research was funded by DIANA project (GEMA call) and “Proyectos de Biomedicina 2018” (Ref. 54/2018) from Departamento de Salud Gobierno de Navarra.

### AUTHOR CONTRIBUTIONS

Conceptualization, P.-G.A. and G.-J.M.; methodology, T.I. and S.J.M.; formal analysis, all authors; investigation, all authors; data curation, T.I., G.-J.M., P.-M.E., and C.-L.A.; writing—original draft preparation, G.-J.M. and P.-G.A., writing—review and editing, all authors; supervision, P.-G.A. and M.M.A.; funding acquisition, P.-G.A. and M.M.A. All authors have read and agreed to the published version of the manuscript.

### COMPETING INTERESTS

The authors declare no competing interests.

### ADDITIONAL INFORMATION

**Supplementary information** is available for this paper at <https://doi.org/10.1038/s41525-020-00160-x>.

**Correspondence** and requests for materials should be addressed to A.P.-G.

**Reprints and permission information** is available at <http://www.nature.com/reprints>

**Publisher's note** Springer Nature remains neutral with regard to jurisdictional claims in published maps and institutional affiliations.



**Open Access** This article is licensed under a Creative Commons Attribution 4.0 International License, which permits use, sharing, adaptation, distribution and reproduction in any medium or format, as long as you give appropriate credit to the original author(s) and the source, provide a link to the Creative Commons license, and indicate if changes were made. The images or other third party material in this article are included in the article's Creative Commons license, unless indicated otherwise in a credit line to the material. If material is not included in the article's Creative Commons license and your intended use is not permitted by statutory regulation or exceeds the permitted use, you will need to obtain permission directly from the copyright holder. To view a copy of this license, visit <http://creativecommons.org/licenses/by/4.0/>.

© The Author(s) 2020