



OPEN ACCESS

Macular abnormalities in Italian patients with retinitis pigmentosa

Francesco Testa,¹ Settimio Rossi,¹ Raffaella Colucci,¹ Beatrice Gallo,¹ Valentina Di Iorio,¹ Michele della Corte,¹ Claudio Azzolini,² Paolo Melillo,¹ Francesca Simonelli¹

► Additional material is published online only. To view please visit the journal online (<http://dx.doi.org/10.1136/bjophthalmol-2013-304082>)

¹Multidisciplinary Department of Medical, Surgical and Dental Sciences, Eye Clinic, Second University of Naples, Naples, Italy

²Department of Surgical and Morphological Sciences, University of Insubria, Varese, Italy

Correspondence to

Dr Francesca Simonelli, Eye Clinic, Multidisciplinary Department of Medical, Surgical and Dental Sciences, Second University of Naples, Via S. Pansini, 5, Naples 80131, Italy; francesca.simonelli@unina2.it

FT and SR contributed equally.

Received 28 July 2013

Revised 19 December 2013

Accepted 18 January 2014

Published Online First

14 February 2014

ABSTRACT

Aim To investigate the prevalence of macular abnormalities in a large Caucasian cohort of patients affected by retinitis pigmentosa (RP).

Methods A retrospective study was performed by reviewing the medical records and optical coherence tomography (OCT) scans in a cohort of 581 RP patients in order to assess the presence of macular abnormalities—that is, cystoid macular oedema (CMO), epiretinal membrane (ERM), vitreo-macular traction syndrome, and macular hole.

Results Macular abnormalities were observed in 524 (45.1%) out of the 1161 examined eyes. The most frequent abnormality was CMO, observed in 237 eyes (20.4%) from 133 patients (22.9%), followed by ERM, assessed in 181 eyes (15.6%) from 115 patients (19.8%). Moreover, vitreo-retinal abnormalities were significantly ($p < 0.05$) associated with older age, cataract surgery, or cataract. CMO appeared to be significantly ($p < 0.05$) associated with female gender, autosomic dominant inheritance pattern, and cataract.

Conclusions Macular abnormalities are more frequent in RP compared to the general population. For that reason, screening RP patients with OCT is highly recommended to follow-up the patients, evaluate the natural history of disease, and identify those patients who could benefit from current or innovative therapeutic strategies.

INTRODUCTION

Retinitis pigmentosa (RP) comprises a group of inherited retinal diseases that cause photoreceptor and retinal pigment epithelium (RPE) degeneration. The disease is characterised by night blindness, visual field constriction, and reduced electroretinographic waves. The retinal lesions are characterised by pigment deposit mainly in the peripheral retina. The macular area is usually spared from photoreceptor degeneration until late stages of the disease. However, during the course of disease some macular changes have been observed in association with RP. The most frequently observed macular abnormalities in RP are cystoid macular oedema (CMO) and macular hole (MH).^{1 2} Moreover, other vitreo-retinal interface alterations, such as vitreous traction and epiretinal membranes (ERMs), have been reported.^{1 2} In the past, the macular abnormalities complicating the natural history of disease in RP patients were observed by funduscopy examination, fluorescein angiography, or both.^{2 3} Today, these abnormalities can be observed more thoroughly thanks to optical

coherence tomography (OCT) that is far more sensitive than funduscopy examination or fluorescein angiography.¹ With the introduction of OCT in clinical practice, most RP cohort studies focused on the observation of CMO while only one study in a Japanese cohort of 323 RP patients investigated all the macular abnormalities observed by OCT.¹ To the best of the authors' knowledge, no previous studies on macular abnormalities assessed by OCT in a large European cohort of RP patients have been reported in the literature.

The aim of this study is to investigate the prevalence of macular abnormalities in a Caucasian population with RP and their relationship with the disease. To this end, a cohort of 581 RP patients previously examined at the Eye Clinic of the Second University of Naples has been retrospectively reviewed.

PATIENTS AND METHODS

The medical records of all patients, who had previously been examined at the Eye Clinic of the Second University of Naples from January 2011 to April 2013 and diagnosed with RP, were reviewed retrospectively by the authors to confirm the accuracy of the diagnosis and ocular findings. A total of 793 patients were initially identified for possible inclusion in the study. These patients underwent a complete ophthalmological examination including: best corrected visual acuity (BCVA) measured using the Snellen chart, slit lamp anterior segment examination, fundus examination, Goldmann visual field examination, standard electroretinogram (ERG), and OCT. ERG was recorded according to the International Guidelines of the International Society of Clinical Electrophysiology of Vision (ISCEV). OCT was performed with the spectral domain OCT (SD-OCT) (Cirrus HD-OCT; Carl Zeiss, Dublin, California, USA) by one experienced examiner. The acquisition protocol comprised both a five-line raster scan and a macular cube scan pattern (512×128 pixels) in which a 6×6 mm region of the retina was scanned within a scan time of 2.4 s.

The diagnosis of RP was based on a history of night blindness, variable degrees of peripheral visual field restriction, and notably reduced or non-recordable ERG a- and b-wave amplitudes, in addition to ophthalmic findings, including characteristic fundus changes of bone spicule-like pigment clumping and attenuation of the retinal vessels. Patients without pigment deposit were excluded.

Patients with systemic syndromes including RP (eg, Usher syndrome, Bardet-Biedl syndrome) were excluded. Patients with pseudophakia, aphakia, and



Open Access
Scan to access more
free content



CrossMark

To cite: Testa F, Rossi S, Colucci R, et al. *Br J Ophthalmol* 2014;**98**: 946–950.

lens opacities were included in the study, while those with cataracts or vitreous opacities which could affect OCT examinations (ie, signal strength <8)⁴ were excluded.

The final cohort consisted of 1161 eyes from 581 patients (319 men and 262 women). The number of studied eyes is odd because one of the patients underwent surgical eye removal due to persistent hyperplastic primary vitreous. As described by Fishman,⁵ the RP patients were classified into the following genetic subtypes: autosomic dominant (AD), autosomic recessive (AR), X-linked (XL). The patients with no affected relatives were considered as sporadic (SP) cases.

Patient records were initially reviewed by three of the authors (RC, BG, and FT) to document the following: patient demographics, BCVA, presence and extent of any ocular media opacification, and appearance of the macula. BCVA and macular findings were obtained from clinical notes made by one of the authors (FT). OCT scans were independently reviewed by two of the authors (FT and SR), and in case of disagreement a third author (FS) was consulted in order to assess the presence of CMO or one of the following vitreo-retinal alterations:

- ▶ vitreo-macular traction syndrome (VMT)
- ▶ epiretinal membrane (ERM)
- ▶ full-thickness macular hole (FTMH)
- ▶ lamellar macular hole (LMH)
- ▶ tractional macular oedema (TMO).

CMO was defined as the presence of cystoid spaces, small hyporeflexive lacunae with well-defined boundaries, on at least two views of the radial scans in the macular area.⁶

VMT was defined as a vitreo-macular adhesion that involved the foveal region from the posterior hyaloid face causing traction and distortion of the central macula.⁷

ERM was defined as a membrane adherent to the inner retina, which presented as being globally or focally adherent. The diagnosis of ERM by SD-OCT is based on the presence of a green line, with reddish tinges, that runs over the retinal surface, often together with underlying waves in the retinal surface layer due to tractional forces.⁸

LMH was defined as partial macular thickness defects with an irregular foveal contour and a schisis between inner and outer retinal layers, but without any photoreceptor layer defects.⁹ By definition, LMH is a macular lesion with loss of foveal tissue.⁹

FTMH was defined as a vertical split in the neurosensory foveal layers and it was revealed in OCT scans as an increase in signal from the RPE near the hole, most likely due to the absence of scattering and absorption from the inner retina.¹⁰

TMO is a subtle variant of the VMT, which shows partial vitreous detachment with persistent vitreous adhesion at the

foveola, causing tractional foveolar thickening with cyst-like spaces in OCT scans.¹¹

All the macular abnormalities were assessed by OCT scans performed at the baseline visit, without considering any subsequent remissions (ie, due to treatment with acetazolamide for CMO).

The current study was performed in compliance with the Declaration of Helsinki and international guidelines.

Continuous variables (eg, age) were expressed as means±SD and were compared using Student's unpaired t test. Categorical variables (eg, sex, cataract) were presented as counts and percentages and were compared using Fisher's exact test. Finally, a multinomial logistic regression was performed to investigate multivariate differences between patients with vitreo-retinal alterations, CMO, or no macular alterations. For each factor or covariate, the coefficient of the estimated regression model (β), the corresponding statistical significance (p), the OR and the CI for OR at 95% were presented. A value of $p < 0.05$ was considered statistically significant.

RESULTS

The demographic and clinical characteristics of the 581 patients are described in tables 1 and 2, respectively. No patients had diabetes mellitus, ocular inflammatory diseases, or primary retinal vascular diseases. Since aphakia was observed only in three patients, for the purpose of the current study, the two clinical conditions (aphakia and pseudophakia) were analysed in a unique group of eyes which underwent cataract surgery. We observed a lower rate of pseudophakia or aphakia among females ($p = 0.012$).

Figure 1 shows the frequency of macular abnormalities assessed by OCT in the whole patient sample. Macular abnormalities were observed by OCT in 508 (43.8%) out of the 1161 examined eyes. The most frequent abnormality was CMO, observed in 237 eyes (20.4%) from 133 patients (22.9%), followed by ERM, observed in 181 eyes (15.6%) from 115 patients (19.8%).

The multivariate statistical analysis, reported in extenso in online supplementary table S1, showed that vitreo-retinal abnormalities were significantly associated with older age ($p < 0.01$), cataract surgery ($p = 0.01$), or cataract ($p < 0.01$). CMO appeared to be significantly associated with female gender ($p = 0.02$), AD pattern ($p = 0.01$), and cataract ($p < 0.01$).

Figure 2 shows the frequency of macular abnormalities by stratifying patients according to gender, inheritance pattern and lens clinical condition, and the related statistical comparisons are reported in online supplementary tables S2–S4, respectively.

Table 1 Demographic characteristics of the patient sample and stratification by gender

	Overall sample (581 patients)	Males (319 patients)	Females (262 patients)
Age (years; mean±SD)	37.7±16.0	36.7±15.7	38.9±16.3
Inheritance pattern			
Autosomal dominant	91 (15.7%)	48 (15.0%)	43 (16.4%)
Autosomal recessive	180 (31.0%)	101 (31.7%)	79 (30.2%)
X linked	28 (4.8%)	28 (8.8%)	0 (0%)
Sporadic	282 (48.5%)	142 (44.5%)	140 (53.4%)

Table 2 Clinical characteristics of the patient sample and stratification by gender

	Overall sample (1161 eyes)	Male (637 eyes)	Female (524 eyes)
Best corrected visual acuity	0.419±0.389	0.405±0.377	0.436±0.379
Clear lens	555 (47.8%)	293 (46.0%)	262 (50%)
Cataract	427 (36.8%)	228 (35.8%)	199 (38.0%)
Pseudophakia or aphakia	179 (15.4%)	116 (18.2%)	63 (12.0%)

A lower rate of pseudophakia or aphakia was observed in females compared to males (Fisher exact test—Bonferroni correction $p = 0.012$).

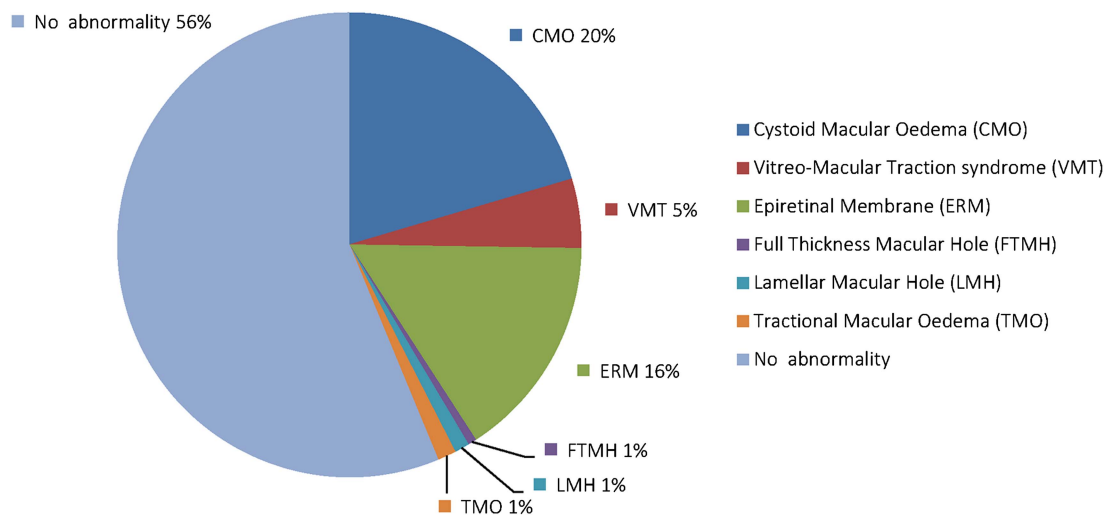


Figure 1 Distribution of macular abnormalities in the study cohort of patients with retinitis pigmentosa.

CMO was significantly more frequent in females (27.5%) than in males (19.1%) and in the AD inherited pattern (34.1%) compared to the AR (13.9%) and XL (7.1%) groups. We observed that the vitreo-retinal alterations (eg, VMT, ERM, FTMH, LMH) were more frequent in pseudophakic or aphakic eyes compared to clear lens eyes, while CMO was more frequent in clear lens eyes (19.6%) compared to those who underwent cataract surgery (15.1%).

DISCUSSION

This is the first study that investigates macular abnormalities assessed by spectral domain OCT in a large Caucasian cohort of patients affected by RP.

To the best of our knowledge, there are limited references in the literature regarding the clinical features of RP in European cohorts, such as the proportion of various inheritance patterns, cataract, or gender differences. This study revealed that the most common subtype was SP (48.5%), while the most frequent Mendelian inheritance pattern was AR (31.0%), followed by AD (15.7%) or XL (4.8%) in Italian RP patients. Other documented proportions of AD, AR, XL, and SP RP in European populations are 7–27%, 21–50%, 2–11%, and 40–48%, respectively.^{12–15} Compared to these reports, the overall distribution of the 581 RP patients from the present study was similar.

In a cohort of 473 German patients the rate of cataract in RP has been reported to range from 41% in XL to 46% in SP subtype.¹⁶ In a recent report in Korean patients, cataract was observed in 47.9% of the studied eyes.¹⁷ Our findings are comparable with these previous reports (about 52% of the analysed eyes with cataract or pseudophakia or aphakia).

The prevalence of CMO among patients with RP has been reported to be 10–20% by some studies performed before the introduction of OCT.^{2–3} Data from more recent studies have shown a great difference in the prevalence of CMO among the various cohorts of RP patients, ranging from 8% observed by Hagiwara *et al*¹ in a cohort of 323 Japanese patients, to 38% observed by Hajali *et al*⁶ in a cohort of 124 patients of different ethnic origin (77% Caucasian). Our findings regarding CMO prevalence (about 20%) falls midway between these previous results. In our sample, we observed that pseudophakic patients had a lower prevalence of CMO; this could be attributed to the fact that in our clinical practice, patients with CMO are unlikely

to undergo cataract surgery, since CMO has been reported as a complication of cataract surgery¹⁸ and it might therefore be expected that cataract surgery would precipitate or exacerbate CMO in patients with RP.¹⁹ Our results suggest that CMO is more frequent in the AD group compared to the AR and XL groups. This result is consistent with the study by Hajali *et al*,²⁰ which showed that the proportion of patients with CMO in at least one eye was maximal for the AD group (52%), followed by the AR (39%) and SP groups (39%). However, the comparison with the prevalence figures reported by Hajali *et al*²⁰ is limited by the small sample size (124 patients) of different ethnic origin. Finally, our results corroborate the findings shown by Hajali *et al*²⁰ that CMO is not age related.

To the best of our knowledge, the prevalence of vitreo-retinal interface abnormalities associated with RP has been reported only in the study by Hagiwara *et al*,¹ which reported lower frequencies of abnormalities, in particular ERM (0.6% vs 15.5%) and VMT (0.8% vs 4.82%), compared to our findings. However, this comparison is limited by several factors related to ERM: ethnic origin, environmental risk factors, and age.²¹ Moreover, Hagiwara *et al*¹ did not stratify patients according to inheritance pattern, gender and cataract, which our results suggest are related to ERM. Considering people over 45 years old, the observed prevalence of ERM in RP patients is consistent with the figures reported in studies from the general population, ranging from 6.0–20% in whites.²¹ Nevertheless, we surprisingly observed a higher prevalence of ERM in RP children (8.6%) compared to the general paediatric population (about 1 out of 21 000 children).²² However, this comparison is limited by:

- ▶ the higher variability of observed prevalence figures in the white population (5–19%)²¹
- ▶ the absence of references for the general European population
- ▶ the different method for defining ERM; in particular, all these population studies relied solely on fundus photographs to define ERM and may thus have unrecognised early stage ERM.²³

The prevalence of FTMH in our patients (0.6%) was comparable with the figure reported by Hagiwara *et al*¹ in RP patients (0.5%). In both studies, only monolateral FTMHs were observed and the estimated prevalence was higher than that observed in international studies in the general population (ranging from 0.02–0.33%).²⁴ The observed female-to-male ratio for MHs of

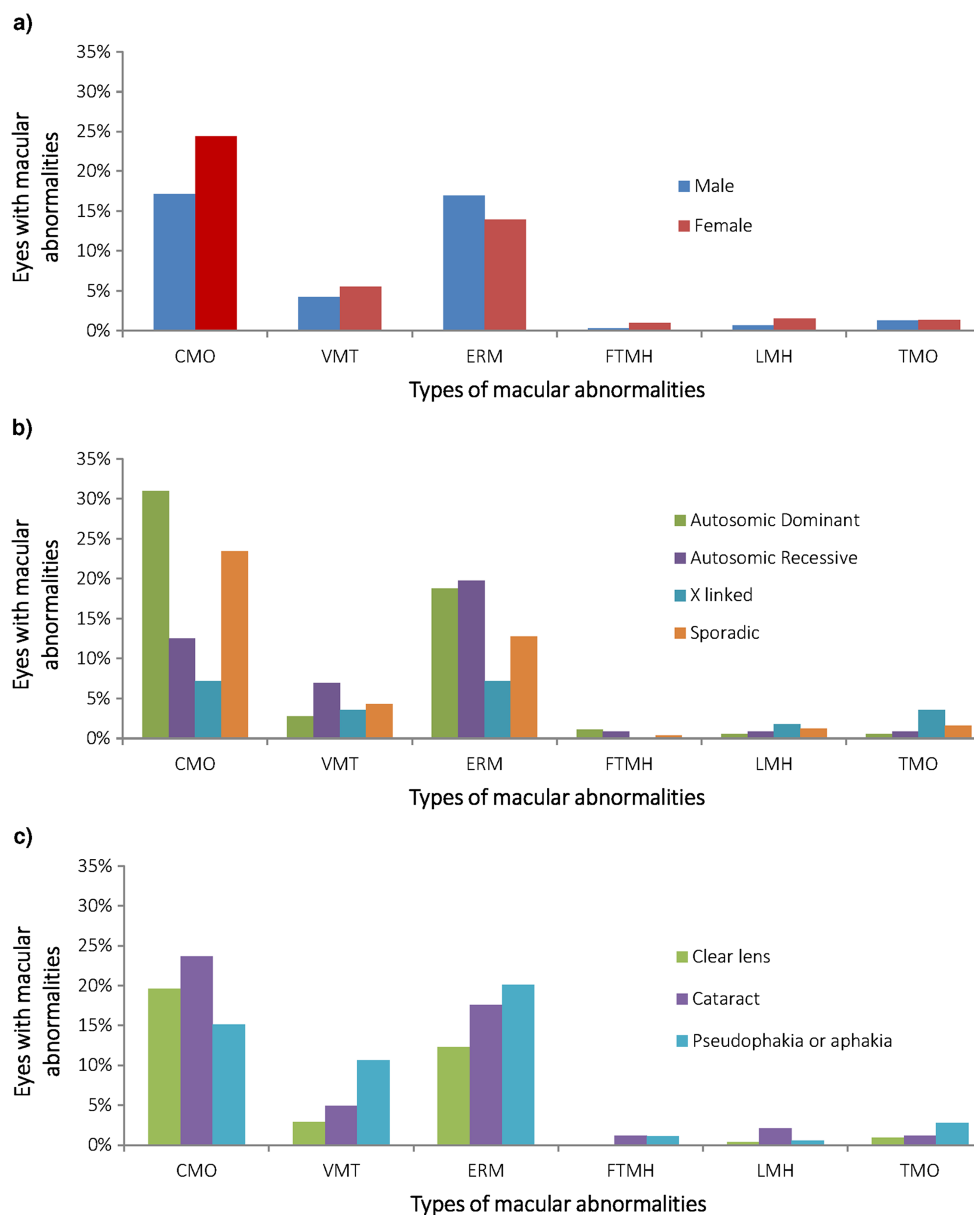


Figure 2 Distribution of macular abnormalities in the study cohort of patients with retinitis pigmentosa stratified by (A) gender; (B) inheritance pattern; and (C) lens appearance. CMO, cystoid macular oedema; ERM, epiretinal membrane; FTMH, full thickness macular hole; LMH, lamellar macular hole; TMO, tractional macular oedema; VMT, vitreomacular traction syndrome.

2:1 was similar to those reported in previous studies in the general population (ranging from 1.2:1 to 2.4:1).²⁴

The current study has some limitations relating to its retrospective design. Genotype information was not available for all patients, and we did not study the relationship between mutations and macular complications. Moreover, the patients did not undergo screening for anti-retinal antibodies, which could have enabled the diagnosis of autoimmune retinopathy (AIR).²⁵ However, none of the main features associated with AIR (pan-retinal degeneration with no or little pigment, fast progression of the disease, negative waveform in ERG response, history of autoimmune disease in the family and/or patient)²⁵ was reported in the medical records of the sporadic cases with CMO, that might be suffering from AIR. In any case, genetic and serum analyses could be an important evolution of our research, as they may enable macular prognosis based on different mutations and on the presence of an autoimmune aetiopathogenesis.

In conclusion, the current study shows that macular abnormalities are very frequent in RP patients (43.8% of the studied eyes). The most frequent macular abnormality is CMO (47% of macular abnormalities), followed by ERM. Moreover, our analysis revealed that CMO is gender related and associated with AD inheritance pattern and cataract, while the other vitreo-retinal alterations are age related and associated with cataract and cataract surgery.

Since macular abnormalities are more frequent in RP compared to the general population, our findings further support the recommendation to screen RP patients with OCT in order to define the natural history of disease and identify those patients who could benefit from current or innovative therapeutic strategies. In particular, CMO patients should undergo recommended treatments—that is, administration of carbonic anhydrase inhibitors, such as acetazolamide or methazolamide. Moreover, in the presence of large cystic spaces which suggest

an autoimmune secondary complication, CMO may respond to an immunosuppressive treatment more effectively than carbonic anhydrase inhibitors.²⁵ The patients with MH, TMO and VMT could undergo vitrectomy or innovative therapeutic strategies, such as intravitreal injection of a vitreolytic agent.²⁶

Finally, further studies are needed to investigate the aetiopathogenesis of these alterations by performing phenotype–genotype correlation analysis, and studying other ocular, systemic and environmental features that could be considered risk factors for the development of macular alterations.

Acknowledgements The authors thanks Dr Carmela Acerra for text editing.

Contributors FT and SR conceived and designed the study; FT, RC, BG and VDI acquired the data (medical record revision); SR, FT, FS reviewed OCT scans, PM and FS analysed and interpreted the data; FT and PM drafted the article; MDC, CA, and FS revised the manuscript critically for important intellectual content. All authors approved the final version.

Competing interests None.

Patient consent Obtained.

Ethics approval The study was approved by the internal review boards at the Second University of Naples.

Provenance and peer review Not commissioned; externally peer reviewed.

Open Access This is an Open Access article distributed in accordance with the Creative Commons Attribution Non Commercial (CC BY-NC 3.0) license, which permits others to distribute, remix, adapt, build upon this work non-commercially, and license their derivative works on different terms, provided the original work is properly cited and the use is non-commercial. See: <http://creativecommons.org/licenses/by-nc/3.0/>

REFERENCES

- Hagiwara A, Yamamoto S, Ogata K, *et al.* Macular abnormalities in patients with retinitis pigmentosa: prevalence on OCT examination and outcomes of vitreoretinal surgery. *Acta Ophthalmol* 2011;89:122–5.
- Fishman GA, Fishman M, Maggiano J. Macular lesions associated with retinitis pigmentosa. *Arch Ophthalmol* 1977;95:798–803.
- Giusti C, Forte R, Vingolo EM. Clinical pathogenesis of macular holes in patients affected by retinitis pigmentosa. *Eur Rev Med Pharmacol Sci* 2002;6:45–8.
- Testa F, Rossi S, Sodi A, *et al.* Correlation between photoreceptor layer integrity and visual function in patients with Stargardt disease: implications for gene therapy. *Invest Ophthalmol Vis Sci* 2012;53:4409–15.
- Fishman GA. Retinitis pigmentosa. Genetic percentages. *Arch Ophthalmol* 1978;96:822–6.
- Hajali M, Fishman GA. The prevalence of cystoid macular oedema on optical coherence tomography in retinitis pigmentosa patients without cystic changes on fundus examination. *Eye (Lond)* 2009;23:915–19.
- Koizumi H, Spaide RF, Fisher YL, *et al.* Three-dimensional evaluation of vitreomacular traction and epiretinal membrane using spectral-domain optical coherence tomography. *Am J Ophthalmol* 2008;145:509–17.
- Chen J, Lee L. Clinical applications and new developments of optical coherence tomography: an evidence-based review. *Clin Exp Optom* 2007;90:317–35.
- Bottoni F, Deiro AP, Giani A, *et al.* The natural history of lamellar macular holes: a spectral domain optical coherence tomography study. *Graefes Arch Clin Exp Ophthalmol* 2013;251:467–75.
- Srinivasan VJ, Wojtkowski M, Witkin AJ, *et al.* High-definition and 3-dimensional imaging of macular pathologies with high-speed ultrahigh-resolution optical coherence tomography. *Ophthalmology* 2006;113:2054 e1–14.
- Johnson MW. Etiology and treatment of macular edema. *Am J Ophthalmol* 2009;147:11–21.
- Ayuso C, Garcia-Sandoval B, Najera C, *et al.* Retinitis pigmentosa in Spain. The Spanish Multicentric and Multidisciplinary Group for Research into Retinitis Pigmentosa. *Clin Genet* 1995;48:120–2.
- Grondahl J. Tapeto-retinal degeneration in four Norwegian counties, II. Diagnostic evaluation of 407 relatives and genetic evaluation of 87 families. *Clin Genet* 1986;29:17–41.
- Haim M. Prevalence of retinitis pigmentosa and allied disorders in Denmark. III. Hereditary pattern. *Acta Ophthalmol (Copenh)* 1992;70:615–24.
- Peterlin B, Canki-Klain N, Morela V, *et al.* Prevalence of retinitis pigmentosa in Slovenia. *Clin Genet* 1992;42:122–3.
- Auffarth GU, Tetz MR, Krastel H, *et al.* [Complicated cataracts in various forms of retinitis pigmentosa. Type and incidence]. *Ophthalmologe* 1997;94:642–6.
- Lee SH, Yu HG, Seo JM, *et al.* Hereditary and clinical features of retinitis pigmentosa in Koreans. *J Korean Med Sci* 2010;25:918–23.
- Gass JD, Norton EW. Cystoid macular edema and papilledema following cataract extraction. A fluorescein fundoscopic and angiographic study. *Arch Ophthalmol* 1966;76:646–61.
- Jackson H, Garway-Heath D, Rosen P, *et al.* Outcome of cataract surgery in patients with retinitis pigmentosa. *Br J Ophthalmol* 2001;85:936–8.
- Hajali M, Fishman GA, Anderson RJ. The prevalence of cystoid macular oedema in retinitis pigmentosa patients determined by optical coherence tomography. *Br J Ophthalmol* 2008;92:1065–8.
- Ng CH, Cheung N, Wang JJ, *et al.* Prevalence and risk factors for epiretinal membranes in a multi-ethnic United States population. *Ophthalmology* 2011;118:694–9.
- Khaja HA, McCannel CA, Diehl NN, *et al.* Incidence and clinical characteristics of epiretinal membranes in children. *Arch Ophthalmol* 2008;126:632–6.
- Duan XR, Liang YB, Friedman DS, *et al.* Prevalence and associations of epiretinal membranes in a rural Chinese adult population: the Handan Eye Study. *Invest Ophthalmol Vis Sci* 2009;50:2018–23.
- McCannel CA, Ensminger JL, Diehl NN, *et al.* Population-based incidence of macular holes. *Ophthalmology* 2009;116:1366–9.
- Heckenlively JR, Ferreyra HA. Autoimmune retinopathy: a review and summary. *Semin Immunopathol* 2008;30:127–34.
- Stalmans P, Benz MS, Gandorfer A, *et al.* Enzymatic vitreolysis with ocriplasmin for vitreomacular traction and macular holes. *N Engl J Med* 2012;367:606–15.