Radiology Case Reports 19 (2024) 1998–2003

Available online at www.sciencedirect.com

ScienceDirect

journal homepage: www.elsevier.com/locate/radcr

Case Report

Reactive lymphoid hyperplasia of the liver: A case report featuring characteristic nodular and perinodular enhancement☆,☆☆

Hirohito Osanai, MD[a], Kazuto Kozaka, MD, PhD[a,], Norihide Yoneda, MD, PhD[a], Kotaro Yoshida, MD, PhD[a], Azusa Kitao, MD, PhD[a], Toshifumi Gabata, MD, PhD[a], Kenichi Harada, MD, PhD[b], Isamu Makino, MD, PhD[c], Satoshi Kobayashi, MD, PhD[a]*

[a] *Department of Radiology, Kanazawa University Graduate School of Medical Sciences, 13-1 Takaramachi, Kanazawa, Ishikawa, 920-8641, Japan*

[b] *Department of Pathology, Kanazawa University Graduate School of Medical Sciences, 13-1 Takaramachi, Kanazawa, Ishikawa, 920-8641, Japan*

[c] *Department of Hepato-Biliary-Pancreatic Surgery and Transplantation, Kanazawa University Graduate School of Medical Sciences, 13-1 Takaramachi, Kanazawa, Ishikawa, 920-8641, Japan*

ARTICLE INFO

Article history:
Received 15 December 2023
Revised 7 February 2024
Accepted 9 February 2024

Keywords:
Reactive lymphoid hyperplasia
Pseudolymphoma
Perinodular enhancement
Comet and comet-tail appearance

ABSTRACT

A 53-year-old female with primary biliary cholangitis was referred for the evaluation of a hepatic nodule identified during routine imaging. Ultrasonography revealed a homogeneous, hypoechoic, 18 mm nodule in segment 3 of the liver. On dynamic CT and MRI, the nodule showed mild enhancement at the hepatic artery-dominant phase. On diffusion-weighted images, the nodule exhibited pronounced hyperintensity with accompanying wedge-shaped perinodular hyperintensity (comet and comet-tail appearance). The nodule showed a portal perfusion defect on CT during arterial portography, and mild enhancement on CT during hepatic arteriography (CTHA). A nodular and wedge-shaped perinodular enhancement (comet and comet-tail appearance) in the CTHA was also clearly observed. The nodule demonstrated abnormal FDG uptake on ^{18}F-FDG-PET/CT. An excisional biopsy was performed for histopathological diagnosis, and the nodule was diagnosed as reactive lymphoid hyperplasia (RLH). Diagnosing hepatic RLH by imaging is challenging due to its imaging findings overlapping with those of various malignant tumors, especially the nodular type of lymphomas, making differentiation particularly difficult. However, radiologists should note the perinodular early enhancement and the perinodular hyperintensity on diffusion weighted images, which are thought to be key imaging findings of RLH, along with other characteristics such as a single, small, homogeneous nodule with mild early enhancement

☆ Acknowledgments: Not applicable.

☆☆ Competing Interests: The authors declare that they have no known competing financial interests or personal relationships that could have appeared to influence the work reported in this paper.

* Corresponding author.
E-mail address: k-kozaka@staff.kanazawa-u.ac.jp (K. Kozaka).

https://doi.org/10.1016/j.radcr.2024.02.029

and marked restricted diffusion. We propose to name the nodular lesion with perinodular early enhancement/hyperintensity on diffusion weighted images as 'comet and comet-tail appearances'.

Introduction

Reactive lymphoid hyperplasia (RLH), also known as hepatic pseudolymphoma, is characterized by the non-neoplastic polyclonal proliferation of lymphocytes, and its occurrence in the liver is rare [1]. Despite its benign nature, imaging findings of hepatic RLH often resemble those of malignant tumors, including hepatocellular carcinoma (HCC) and intrahepatic cholangiocarcinoma, in the context of chronic liver disease, as well as metastatic liver tumors in patients with a history of malignant disease, making differentiation challenging. Notably, malignant lymphoma has radiological features similar to those of RLH, further complicating differentiation based on clinical images [2,3]. Hepatic RLH occurs frequently in patients with primary biliary cholangitis (PBC) [2]. Therefore, hepatic RLH shows hypervascularity on dynamic contrast-enhanced CT/MRI and its differentiation from HCC is problematic in patients with PBC. Here, we describe a case of hepatic RLH presenting with characteristic imaging features, including perinodular enhancement and wedge-shaped enhancement contiguous with nodules (comet and comet-tail [CCT] appearance). Additionally, we retrospectively reviewed cases of hepatic RLH and grossly nodular hepatic malignant lymphoma, examine the utility of CCT appearance in differentiating hepatic RLH from malignant lymphoma.

Case report

A 53-year-old female with a known history of primary biliary cholangitis (PBC) presented for the evaluation of a hepatic nodule identified during routine imaging work up. Her family medical history was unremarkable, and physical examination did not reveal any notable findings. Laboratory tests revealed mild elevations in gamma-glutamyltranspeptidase and alkaline phosphatase, with levels at 82 U/L and 150 U/L, respectively. Serological tests were negative for hepatitis B surface antigen and hepatitis C virus-specific antibodies. Additionally, tumor markers, including alpha-fetoprotein, des-γ-carboxy prothrombin, carcinoembryonic antigen, carbohydrate antigen 19-9, and soluble interleukin-2 receptor, were not elevated. Ultrasonography revealed a homogenous, hypoechoic, 18 mm nodule in segment 3 of the liver (Fig. 1A). The nodule showed hypodensity on noncontrast CT, and dynamic contrast-enhanced CT revealed mild enhancement in the hepatic arterial-dominant phase and persistent enhancement in the equilibrium phase (Fig. 1B and C). On Gadoxetic acid-enhanced MRI, no evidence of fat components on the chemical shift images. Fat-suppressed T2-weighted images (Fig. 1D) and diffusion-weighted images (DWI) with b-values of 800 s/mm^2 (Fig. 1E) demonstrated homogeneous nodular hyperintensity. The apparent diffusion coefficient (ADC) value, calculated using images with b values of 0 and 800 s/mm^2, was 0.79×10^{-3} mm^2/s. Additionally, DWI revealed a wedge-shaped perinoduolar hyperintensity extending from the nodule, a characteristic seen in CCT appearance (Fig. 2, top row, arrow). This perinodular lesion appeared hypointense on the ADC map. Dynamic contrast-enhanced MRI showed a similar enhancement pattern to that of dynamic CT (Fig. 1F), but with more pronounced perinodular enhancement (Fig. 1F, arrow). On the hepatobiliary phase of the gadoxetic acid-enhanced MRI, the nodule was hypointense (Fig. 1G). Angiography-assisted CT was performed to facilitate a more precise diagnosis and to aid in staging the condition. CT during arterial portography (CTAP) revealed a portal perfusion defect (Fig. 1H), and CT during hepatic arteriography (CTHA) revealed mild enhancement (Fig. 1I and J). Additionally, a perinodular portal perfusion defect on CTAP (Fig. 1H) and perinodular enhancement on CTHA were observed (Fig. 1I), and the CCT appearance was clearly depicted (Fig. 2, bottom row). ^{18}F-FDG-PET/CT showed abnormal FDG uptake, with an SUV max of 7.9 in the early phase (Fig. 1K). The lesion was suspected to be either RLH or malignant lymphoma, and the histopathological diagnosis was considered at a multidisciplinary conference. Considering the protruding position of the nodule on the liver surface, and in alignment with the patient's wishes, an excisional biopsy through laparoscopic partial hepatectomy was performed. The nodule was greyish-white and uniform on macroscopic examination, and microscopically, it consisted of small lymphocytes and plasma cells, including lymphoid follicles with mixed tingible body macrophage, with no nuclear atypia (Fig. 3A and B). In situ hybridization demonstrated a kappa/lambda ratio of 1.6, with no abnormalities in light chain expression, and no evidence of monoclonality was observed in the increased number of lymphocytes. Consequently, the nodule was diagnosed as hepatic RLH. Additionally, some focal granulomas were observed in the background liver tissue, consistent with the patient's current history of PBC. At the 8-month follow-up, there have been no signs of hepatic RLH recurrence or HCC development.

We analyzed our pathology reports to compare 12 cases of hepatic RLH with 4 cases of grossly nodular hepatic malignant lymphoma, focusing on the utility of CCT findings. For this retrospective analysis, we used angiography-assisted CT, chosen for its superior contrast resolution and consistent image quality over a wide range of years, which are crucial factors for accurately differentiating these conditions (Table 1). We found that CCT findings had a sensitivity of 83.3% for RLH, being present in 10 of the 12 RLH cases. In contrast, it was absent in all lymphoma cases. This resulted in a specificity of 100% and overall accuracy of 87.5%.

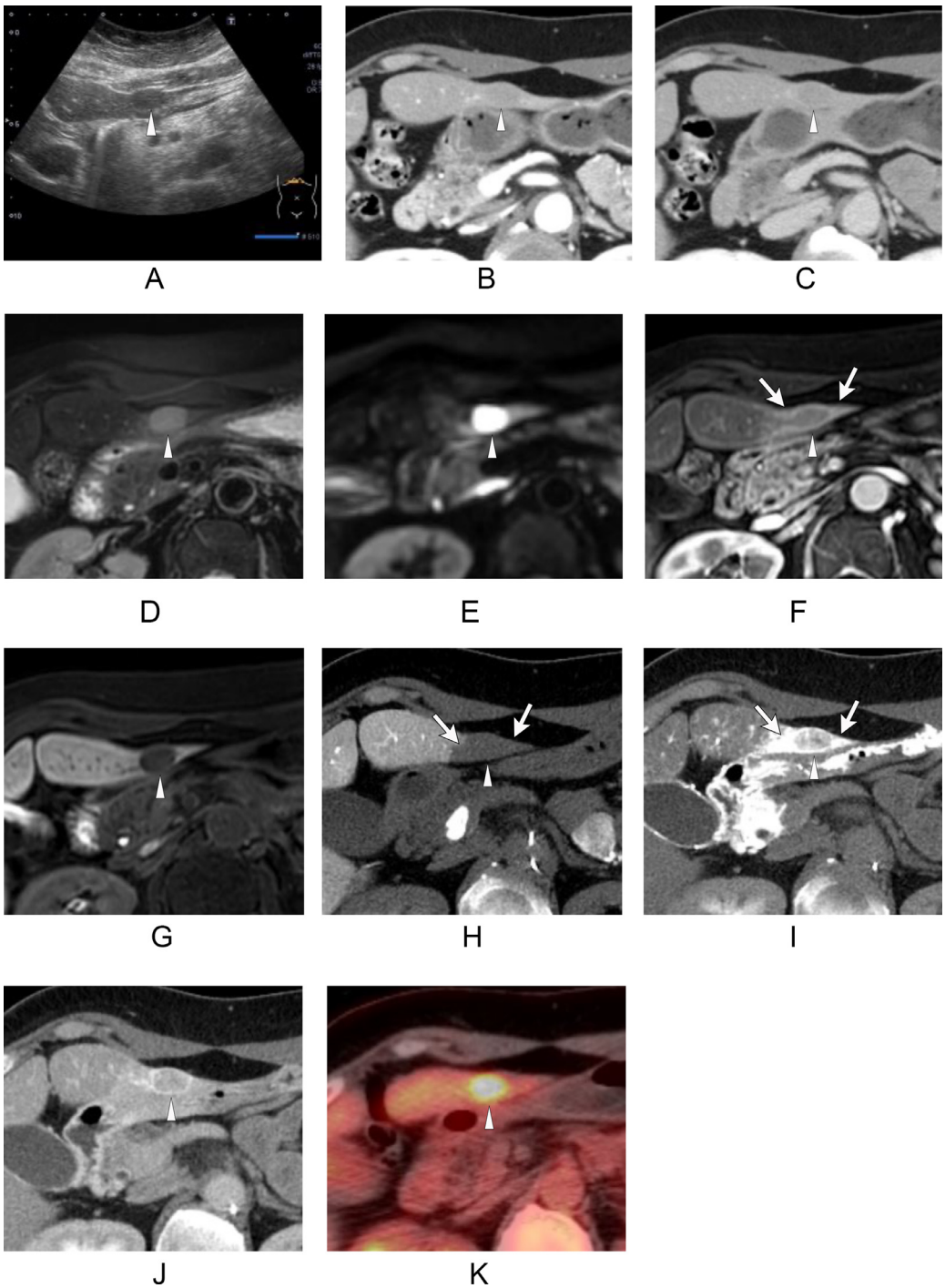

Fig. 1 – Imaging findings of the liver nodule. Ultrasound shows a homogenous hypoechoic nodule 18 mm in diameter in segment 3 (A, arrowhead). On the arterial phase of dynamic contrast-enhanced CT, the nodule shows mild enhancement (B, arrowhead). The equilibrium phase demonstrates it as a slight hypodensity nodule compared to the background liver (C, arrowhead). On MRI, fat-suppressed T2-weighted images (D) and diffusion-weighted images (E) shows it as hyperintense (arrowhead). On the arterial phase of dynamic contrast-enhanced MRI, it appears as a mild enhancement (F, arrowhead), while perinodular enhancement (F, arrow) is also observed. In the hepatobiliary phase of gadoxetic acid-enhanced MRI, it shows hypointensity (G, arrowhead). CT during arterial portography (CTAP) shows it as a portal perfusion defect (H, arrowhead), while CT during hepatic arteriography (CTHA) shows it as mild enhancement (I and J, arrowhead). Perinodular portal perfusion defect on CTAP (H, arrow) and enhancement on the early phase of CTHA (I, arrow) were also observed. FDG-PET/CT shows abnormal FDG uptake (K, arrowhead).

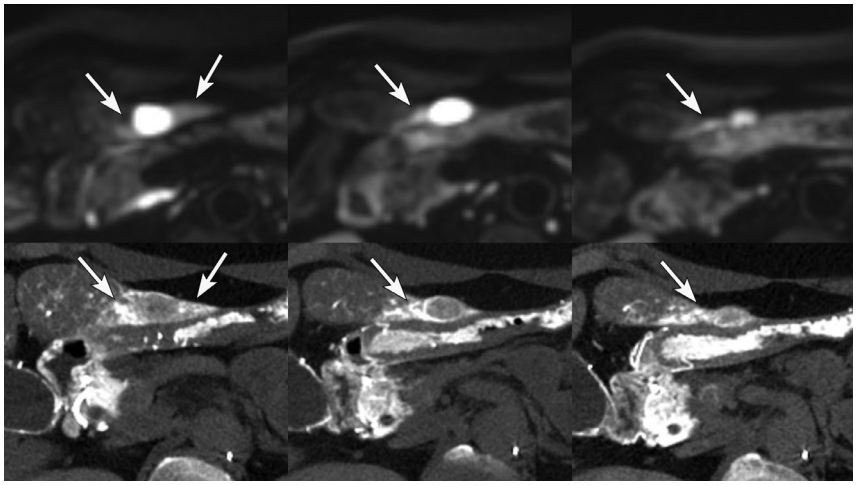

Fig. 2 – Sequential images of diffusion-weighted images (DWI) (top row) and the early phase of CT during hepatic arteriography (CTHA) (bottom row). Perinodular hyperintensity on DWI and perinodular enhancement on CTHA are observed (arrow), and these findings exhibit a wedge-shaped appearance (comet and comet-tail appearance).

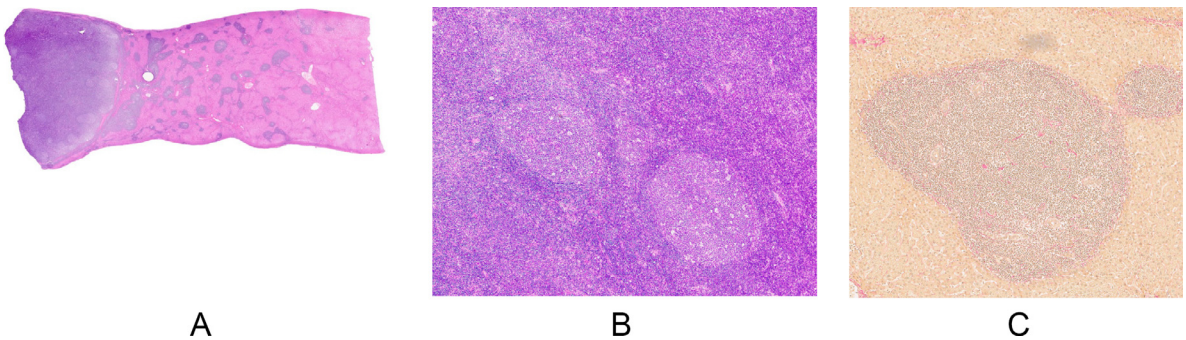

Fig. 3 – Pathologic findings. Macrograph of the resected specimen (A) shows a well-circumscribed nodule and marked lymphoid cell infiltration into portal tracts around the nodule (low-magnified view of hematoxylin and eosin staining). The nodule consists of small lymphocytes and plasma cells with lymphoid follicles without significant atypia (high-magnified view of hematoxylin and eosin staining) (B). Micrograph in the perinodular area (high-magnified view of Elastica van Gieson staining) shows dense lymphoid cell infiltration within portal tracts, obscuring the portal vein.

Discussion

RLH, also known as pseudolymphoma or nodular lymphoid hyperplasia, is a benign nodule composed of non-neoplastic polyclonal lymphocytic proliferation with lymphfollicular hyperplasia [1]. The imaging findings of hepatic RLH have been thoroughly investigated. A review of 46 previous cases focusing on clinical imaging indicated that single nodules were reported in 80.4% of cases, with the majority of these nodules being small, measuring less than 2 cm in 90.6% of cases [4]. The internal characteristics of these nodules were often homogeneous. Specifically, on CT, hepatic RLH demonstrates hypodensity compared to the background liver in noncontrast images, mild enhancement in the hepatic arterial-dominant phase of dynamic contrast-enhanced CT, and hypo- to isodensity without washout in the equilibrium phase. In MRI, it shows marked hyperintensity on DWI [3] and restricted diffusion on the ADC [5], similar to lymphoma. On FDG-PET/CT, hepatic RLH exhibits relatively intense FDG uptake [6,7]. In the present case, imaging findings were typical for hepatic RLH. In addition, hepatic RLH reportedly demonstrates both nodular and perinodular early enhancement at the hepatic arterial-dominant phase in dynamic contrast-enhanced CT/MRI. This finding was given particular attention in our analysis and propose to call those findings 'CCT appearance'. Perinodular early enhancement is believed to be linked to its histopathological hallmark of pronounced lymphocytic infiltration in the portal vein tract surrounding the nodule. Perinodular infiltration impedes microscopic portal venous blood flow by compressing the portal venules, leading to a compensatory increase in arterial blood flow. This change in blood flow dynamics likely results in the perinodular enhancement observed in imaging studies [1,3]. In the present case, the portal vein

Table 1 – Wedge-shaped perinodular enhancement in RLH and malignant lymphoma (nodular type) of the liver (retrospective evaluation of angiography-assisted CT).

Patient	Age	Sex	Comorbidity	Diagnosis	Method of diagnosis	Number of nodules	Size (mm)	Wedge-shaped perinodular enhancement (CCT finding)
1	63	Female	PBC	RLH	Biopsy	1	9	Present
2	59	Female	NA	RLH	Biopsy	2	9, 12	Present
3	67	Female	NA	RLH	Resection	1	10	Present
4	56	Female	CHC	RLH	Resection	1	10	Present
5	64	Female	NAFLD	RLH	Biopsy	7	6∼12	Present
6	81	Male	NA	RLH	Biopsy	1	54	Absent
7	73	Female	PBC	RLH	Biopsy	3	15, 33, 60	Present
8	64	Female	NA	RLH	Biopsy	1	12	Present
9	62	Female	Alcohol liver disease, thyroid cancer	RLH	Resection	1	15	Present
10	43	Female	Breast cancer	RLH	Resection	8	5∼13	Present
11	64	Female	APS, Takayasu aortitis	RLH	Biopsy	2	9, 17	Absent
12 (this case)	53	Female	PBC	RHL	Resection	1	18	Present
13	75	Female	DLBCL	DLBCL	Biopsy	14	4∼15	Absent
14	86	Female	CHC	DLBCL	Biopsy	3	11, 15, 33	Absent
15	74	Male	CHC	MALToma	Biopsy	17	5∼25	Absent
16	74	Female	PBC	MALToma	Biopsy	1	37	Absent

CCT, comet and comet-tail; PBC, primary biliary cholangitis; CHC, chronic hepatitis C; NAFLD, nonalcoholic fatty liver disease; APS, antiphospholipid antibody syndrome; NA, not applicable; RLH, reactive lymphoid hyperplasia; DLBCL, diffuse large B-cell lymphoma; MALToma, mucosa-associated lymphoid tissue lymphoma

branches within the perinodular portal tract were obscured by lymphocytic infiltration (Fig. 3C), and wedge-shaped perinodular enhancement was clearly observed in the early phase of CTHA [3]. Indeed, portal vein tumor thrombi, which are vital in managing HCC [8], typically show an increase in arterial blood flow in the affected area. However, a key differentiating feature of these thrombi in HCC is their relative hypoattenuation from the portal to the equilibrium phase, as opposed to the isoattenuation commonly observed in hepatic RLH. Recognizing that adequate spatial and contrast resolution are critical for a detailed diagnosis. Despite its invasiveness, angiography-assisted CT can be considered for thorough examination when hepatic RLH is suspected owing to its heightened sensitivity in detecting perinodular enhancement [3]. In the current case, we observed both nodular and perinodular hyperintensity on DWI as reported by Tanaka et al [9]. This finding, which is indicative of lymphocytic infiltration into the perinodular portal tract, can help differentiate lymphoproliferative diseases from other malignancies such as HCC, intrahepatic bile duct carcinoma, and metastatic liver tumors [9].

Differentiating RLH from nodular-type malignant lymphoma presents a significant challenge, as they share similar imaging characteristics. Our case review demonstrated the usefulness of CCT findings in differentiating RLH from hepatic lymphoma, with CCT showing a sensitivity of 83.3% for RLH, a specificity of 100%, and an overall accuracy of 87.5%. However, an important limitation to note is that our study had a small sample size and was solely based on the assessment of angiography-assisted CT. Therefore, the efficacy of this imaging finding should be further evaluated in the future with the accumulation of more cases.

Conclusion

The nodular lesion with perinodular early enhancement/hyperintensity on diffusion weighted images (CCT appearances) may be a characteristic radiological sign of hepatic RLH. Although these observations are preliminary, they offer valuable insights into the potential diagnostic utility of this imaging characteristic for hepatic RLH.

Patient consent

The study design was approved by the appropriate ethics review board. Written informed consent was obtained from the patient for publication of the present case and any accompanying images.

Submission declaration and verification

We declare that this manuscript has not been published before and is not currently being considered for publication elsewhere.

REFERENCES

[1] Zen Y, Fujii T, Nakanuma Y. Hepatic pseudolymphoma: a clinicopathological study of five cases and review of the

literature. Mod Pathol 2010;23:244–50. doi:10.1038/modpathol.2009.165.
[2] Jiang W, Wu D, Li Q, Liu CH, Zeng Q, Chen E, et al. Clinical features, natural history and outcomes of pseudolymphoma of liver: a case-series and systematic review. Asian J Surg 2023;46:841–9. doi:10.1016/j.asjsur.2022.08.113.
[3] Yoshida K, Kobayashi S, Matsui O, Gabata T, Sanada J, Koda W, et al. Hepatic pseudolymphoma: Imaging-pathologic correlation with special reference to hemodynamic analysis. Abdom Imaging 2013;38:1277–85. doi:10.1007/s00261-013-0016-6.
[4] Yang CT, Liu KL, Lin MC, Yuan RH. Pseudolymphoma of the liver: report of a case and review of the literature. Asian J Surg 2017;40:74–80. doi:10.1016/j.asjsur.2013.07.013.
[5] Zhou Y, Wang X, Xu C, Zhou G, Zeng M, Xu P. Hepatic pseudolymphoma: imaging features on dynamic contrast-enhanced MRI and diffusion-weighted imaging. Abdom Radiol (NY) 2018;43:2288–94. doi:10.1007/s00261-018-1468-5.
[6] Taguchi K, Kuroda S, Kobayashi T, Tashiro H, Ishiyama K, Ide K, et al. Pseudolymphoma of the liver: a case report and literature review. Surg Case Rep 2015;1:107. doi:10.1186/s40792-015-0110-9.
[7] Kwon YK, Jha RC, Etesami K, Fishbein TM, Ozdemirli M, Desai CS. Pseudolymphoma (reactive lymphoid hyperplasia) of the liver: a clinical challenge. World J Hepatol 2015;7:2696–702. doi:10.4254/wjh.v7.i26.2696.
[8] Liu PH, Huo TI, Miksad RA. Hepatocellular carcinoma with portal vein tumor involvement: best management strategies. Semin Liver Dis 2018;38:242–51. doi:10.1055/s-0038-1666805.
[9] Tanaka T, Saito K, Yunaiyama D, Matsubayashi J, Nagakawa Y, Tanigawa M, et al. Diffusion-weighted imaging might be useful for reactive lymphoid hyperplasia diagnosis of the liver: a case report. World J Clin Cases 2020;8:5313–19. doi:10.12998/wjcc.v8.i21.5313.