

# Hyaluronic Acid-Based Mesh Add-On Iliac Autograft Improves Bone Healing and Functional Outcomes in Atrophic Nonunion of Clavicular Midshaft: A 2-Year Followup

## Abstract

**Background:** Atrophic nonunion may frequently be seen after clavicular midshaft fractures. Despite a variety of surgical options, clavicular nonunion cases are associated with impaired bone healing. The aim of current study was to evaluate efficacy of perioperatively administered hyaluronic acid (HA)-based mesh in patients with atrophic midshaft clavicular nonunion managed with iliac wing autograft and plate fixation. **Materials and Methods:** This retrospective clinical study investigated 44 patients with atrophic midclavicular nonunion who underwent open reduction plate fixation with iliac wing autografts. Patients were divided into two groups as those managed with iliac wing autograft and anatomical locking plate (ALP) fixation alone and those managed with add-on perioperative HA-based mesh, i.e., Group 1 ( $n = 24$ ) and Group 2 ( $n = 20$ ), respectively. Age, duration till to surgery, fracture healing time, length of gap, and length of injured and contralateral clavicle were also investigated. The 2-year Disabilities of the Arm, Shoulder and Hand (DASH) and Constant scores were evaluated. Kolmogorov–Smirnov test, Mann–Whitney U-test, and Spearman’s correlation test were used to assess variables. **Results:** Patients’ age, followup time, and duration till surgery were similar between two groups. The study groups did not significantly differ in terms of postoperative clavicular length, as measured relative to unaffected side. Mean duration of the fracture healing was significantly shorter in Group 2 compared to that in Group 1. Mean postoperative 2-year Constant score was statistically higher in Group 2 compared to that of Group 1. In addition, Group 2 had also significantly higher DASH score than that of Group 1. **Conclusions:** HA-based mesh application added on the iliac wing autografting with ALP fixation may be an efficacious alternative for atrophic nonunion of clavicular midshaft.

**Keywords:** Atrophic nonunion, clavicular midshaft, hyaluronic acid-based mesh

## Introduction

Fractures of the clavicle are among common injuries of the shoulder girdle, 69%–82% of which were reported to occur at the midshaft portion.<sup>1,2</sup> Nonunion is seen in 5%–6% of the clavicular fractures, and if treated conservatively, this may raise up to 15% in midshaft fractures.<sup>3,4</sup> The risk factors for pseudoarthrosis include clavicular shortening >2 cm, lateral Neer type 2 and comminuted fractures, serious soft-tissue injury, advanced age, and female gender.<sup>5-7</sup> Impaired healing of the fracture may cause pain or instability and also restrict shoulder function.

Shortening and atrophic nonunion of the clavicle is often managed by osteosynthesis with plate and reconstruction of the defect

through iliac wing autograft. Despite a variety of surgical options, however, 6%–8% of clavicular nonunions are associated with impaired healing, requiring reinterventions.<sup>8</sup>

Hyaluronic acid (HA), an abundant glycosaminoglycan of extra cellular tissue in the human body, becomes relatively important in biomedical science.<sup>9</sup> HA-based mesh is a web-like absorbable coverage that is made of HA fibrils. It is used for filling the defects and stabilizing the grafts in the treatment of comminuted fractures, shortening, and nonunion.<sup>10</sup> It also influences osteoblastic activity and angiogenesis.<sup>11</sup>

Favorable effects of HA-based mesh on graft stabilization and fracture healing raise the question that it may be used as an alternative method in clavicular nonunion

This is an open access journal, and articles are distributed under the terms of the Creative Commons Attribution-NonCommercial-ShareAlike 4.0 License, which allows others to remix, tweak, and build upon the work non-commercially, as long as appropriate credit is given and the new creations are licensed under the identical terms.

For reprints contact: reprints@medknow.com

**How to cite this article:** Kir MC. Hyaluronic acid-based mesh add-on iliac autograft improves bone healing and functional outcomes in atrophic nonunion of clavicular midshaft: A 2-year followup. *Indian J Orthop* 2019;53:459-64.

## Mustafa Çağlar Kir

Department of Orthopaedics and Traumatology, Okmeydani Training and Research Hospital, Health Sciences University, Istanbul, Turkey

### Address for correspondence:

Dr. Mustafa Çağlar Kir,  
Department of Orthopaedics and Traumatology, Okmeydani Training and Research Hospital, Darulaceze Caddesi, No. 25 Sisli, 34382 Istanbul, Turkey.  
E-mail: drcaglarkir@gmail.com

### Access this article online

Website: [www.ijoonline.com](http://www.ijoonline.com)

DOI:  
10.4103/ortho.IJOrtho\_702\_17

### Quick Response Code:



cases. In our study, we investigated effects of HA-based mesh use on radiological and clinical healing in clavicular nonunion.

This study aimed to evaluate efficacy of perioperatively administered HA-based mesh in patients with atrophic clavicular midshaft nonunion managed with iliac wing autograft and anatomical locking plate (ALP) fixation.

## Materials and Methods

Up approval by an ethics committee, among 48 patients who were operated after the diagnosis of atrophic nonunion of the midshaft of the clavicle between January 2007 and January 2012, 44 cases with available medical records were included to this retrospective study. All participants had atrophic midshaft nonunion with no clinical or radiological sign of union after at least 6 months of the clavicular injury or primary surgery. Those having pathological or multiple comminuted fractures or being below 18 years old were not included in the study. Patients were divided into two groups as those managed with iliac wing autograft and ALP fixation (Acumed Ltd., Hampshire, UK) alone and those managed with add-on perioperative HA-based mesh, i.e., Group 1 ( $n = 24$ ) and Group 2 ( $n = 20$ ), respectively.

While 26 cases had been treated conservatively with eight clavicular bandage, the remaining 18 patients had been managed with open reduction and plate fixation. The criteria for atrophic nonunion were pathological mobility and pain at the fracture region or observation of pathological movement at vertical traction X-rays in conservatively treated patients, or persistence of pain in surgically treated patients, or absence of radiological sign of union in both patient groups at least 6 months after the injury.

## Operative procedure

All operations were performed by the same surgeon and nursing team. Patients were brought into beach chair position with a support to the medial of the affected scapula. A transverse incision was made along the superior aspect of clavicle under general anesthesia. If available, present implants were removed. The site of nonunion was identified and exposed circumferentially [Figure 1]. Samples were taken from nonunion area for culture tests (all samples later turned out to be negative). A single dose of cefazolin 1 g was administered. The length of gap (LG) was measured with a sterile scale after unvitalized and fibrous tissue was removed perioperatively. Sclerosing bone ends were revitalized. Clavicular length was established between revitalized bone ends, followed by osteosynthesis with ALP to superior clavicle surface. At least, three bicortical screws with six cortices were placed on each side of the fracture [Figures 2 and 3]. In 20 patients who had >2-cm LG after reduction and where the original length of the clavicle was established by ALP, strut and cancellous iliac wing autograft was wrapped with HA-based mesh, which was augmented to the defect

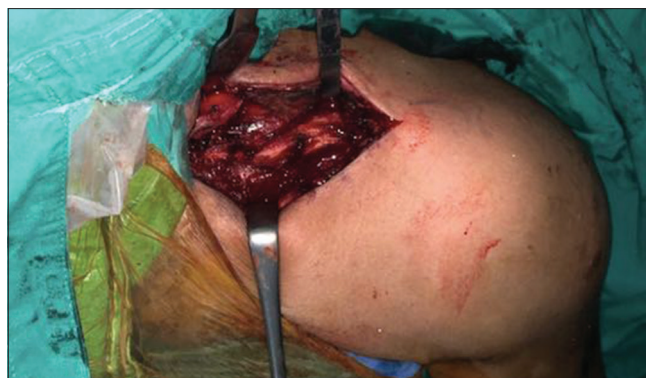

Figure 1: Perioperative clinic view of the clavicular shortening with atrophic nonunion after surgical exposure

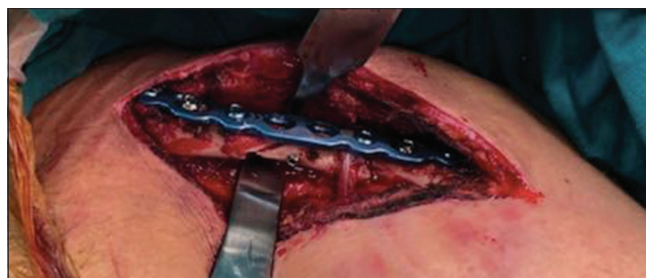

Figure 2: Clavicular shortening was reconstructed after open reduction and plate fixation

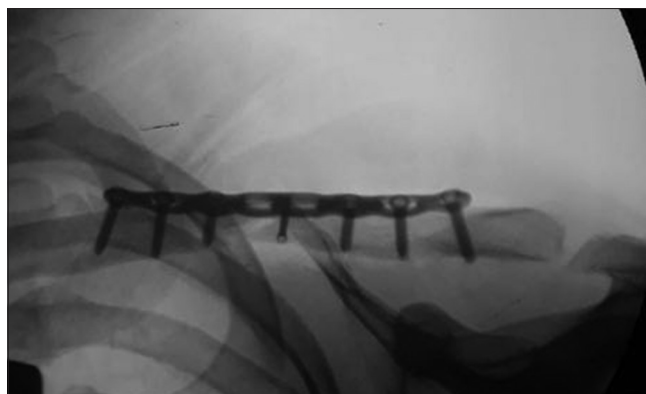


Figure 3: Perioperative fluoroscopic shoulder anteroposterior view after open reduction and anatomical locking plate fixation of the clavicle

area [Figure 4]. The other 24 patients in Group 1, whose LG was <2 cm, underwent plate fixation, followed by strut and cancellous iliac wing autografting without mesh. HA-based mesh was sutured with absorbable sutures, providing periosteal integrity [Figure 5]. The wound was closed over a drain (medium size; Hemovac) in a standard manner. A sling was used for immobilization until the removal of sutures on the 14<sup>th</sup> day postoperatively.

All clinical and radiological followups of the patients were obtained from inpatient and outpatient medical records. All preoperative and postoperative X-ray records were screened to detect the radiological sign of union. Two independent musculoskeletal system-specific radiologists evaluated the clavicular union. In patients with no shoulder

pain or pathological movement clinically, observation of stable implant position and the bone bridging remodeling which indicated filling of the fracture gap on shoulder anteroposterior (AP) and oblique X-ray was regarded as the consolidation of the fracture.<sup>12</sup> Shortening of the clavicle was evaluated by measuring the distance between the centers of acromioclavicular joint and sternoclavicular joint at a thorax AP X-ray image which encompassed visualization of both clavicles. The length of the shortening was acquired by subtracting injured site from the unaffected site [Figures 6 and 7].<sup>13</sup> Shoulder pain and functions were assessed with postoperative 2-year Disabilities of the Arm, Shoulder and Hand (DASH) and Constant scores.

### Statistical analysis

IBM SPSS Statistics 21 program (SPSS 21.0, SPSS Inc, Chicago, IL, USA) was used for statistical analysis. Descriptive statistical methods (mean, standard deviation, minimum, and maximum) were utilized to analyze data. Kolmogorov–Smirnov test was used to evaluate the normality of data distribution. The age, duration till the

surgery, fracture healing time, and clinical scores were compared by independent samples *t*-test. Spearman’s correlation was used to compare the length of the injured clavicle to that of the contralateral clavicle and to evaluate the association between fracture healing time and clinical scores. An overall 5% Type I error level was used to infer statistical significance.

### Results

Mean age of the patients was  $42.4 \pm 13.8$  years [Table 1]. Twenty six patients (59%) were male. Mean followup time was  $34.2 \pm 7.4$  months. Mean duration between the index injury and the revision surgery was  $11.8 \pm 2.6$  months. Complete fracture healing was detected in all patients who were administered HA-based mesh (Group 2), which was seen in 20 patients (83.3%) in Group 1. Mean duration of the fracture healing was significantly shorter in Group 2 ( $14.7 \pm 1.2$  months) compared with Group 1 ( $19.6 \pm 3.2$  months;  $P = 0.001$ ). The mean LG in Group 2 was significantly higher than the Group 1 ( $2.10 \pm 0.4$  vs.  $0.90 \pm 0.23$ ;  $P = 0.0001$ ). The study groups did not significantly differ in terms of postoperative clavicular length, as measured relative to unaffected side




Figure 4: The photograph of hyaluronic acid-based mesh

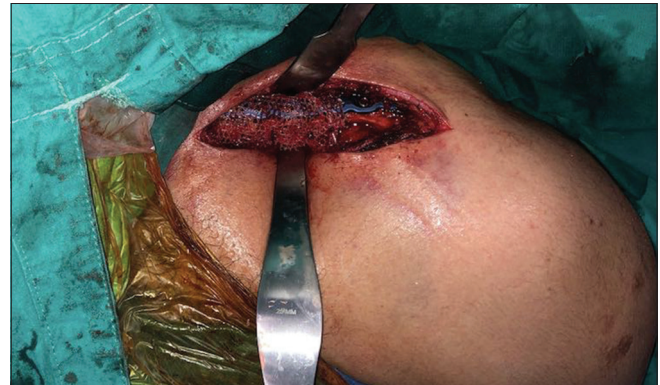

Figure 5: Perioperative photographs showing the hyaluronic acid-based mesh applied circumferentially around the clavicle

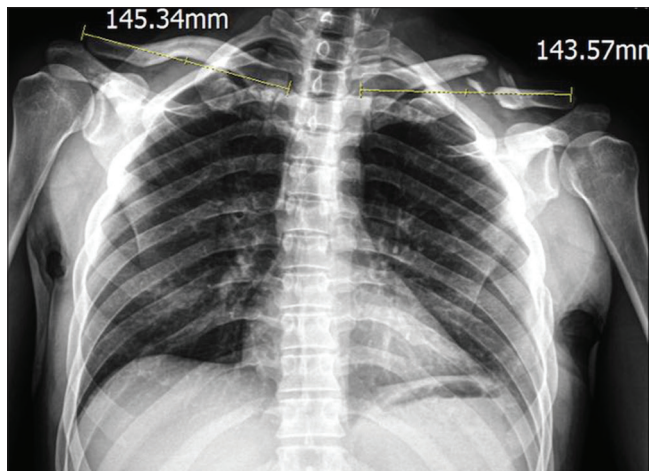


Figure 6: Preoperative thorax anteroposterior view. Clavicular shortening after nonunion compared with contralateral side

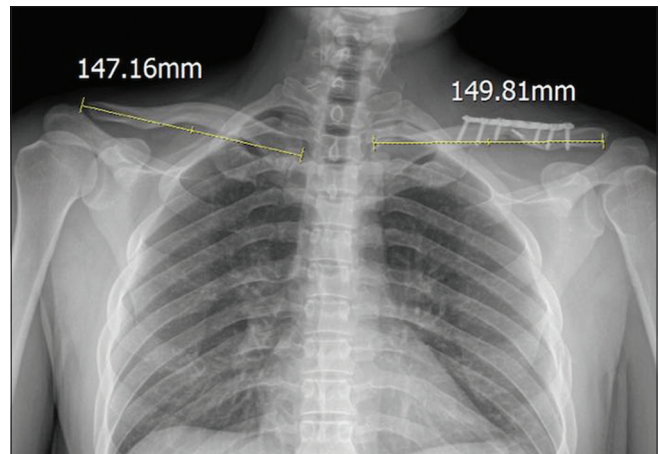


Figure 7: Postoperative thorax anteroposterior view. Clavicular shortening was reconstructed after open reduction and plate fixation

(rho = 0.989) [Table 2]. The four patients who had no union underwent revision surgery after 6 and 7.5 months, where tricortical iliac wing autograft was used with add-on HA-based mesh administration. Complete union was also achieved in these four cases after the second revision.

Mean postoperative 2-year Constant score was statistically higher in Group 2 compared with that of Group 1 (90.2 ± 1.0 vs. 81.5 ± 9.5; P = 0.009). Group 2 had also significantly higher DASH score (14.1 ± 4.7) than that of Group 1 (7.3 ± 4.4; P = 0.002). In addition, duration of the fracture healing was negatively affected to the DASH (r<sup>2</sup> linear = 0.334) and Constant scores (r<sup>2</sup> linear = 0.370) [Figures 8 and 9]. A patient in Group 2 had superficial wound site infection that began on postoperative day 3 lasting for 10 days and was managed conservatively. One patient in each group had temporary upper extremity paresthesia that lasted for 4 weeks.

### Discussion

Midshaft fractures of the clavicle are one of the most frequent fractures of the upper extremity.<sup>1</sup> Impaired healing the clavicle fractures that may rather develop secondary conservative management approaches might lead to several complications such as shortening, instability, impaired shoulder functions, thoracic outlet syndrome, subclavian vessel compression, and brachial plexus injury.<sup>14</sup> The condition is usually managed by osteosynthesis with plate and with or without grafting.<sup>8</sup> Addition of iliac wing bone graft is especially recommended in nonunion cases with atrophic-type defect.<sup>15</sup> In this study, the patients who underwent iliac wing autograft plus plate fixation due to atrophic midshaft nonunion were retrospectively evaluated. We detected that perioperative HA-based mesh application surrounding the iliac wing autograft accelerated the fracture healing, reduced the time required for union, and had favorable effects on shoulder function scores. To our knowledge, this is the first study that compared

bone healing rates and shoulder function with or without HA-based mesh application in patients with clavicular midshaft atrophic nonunion. Consistent with our findings, Tekin *et al.* used HA-based mesh in addition to long bone allograft in upper and lower extremity nonunion cases which had prior surgery and reported that complete union

**Table 1: Age, time to operation, follow time, length of gap, union time, and the Disabilities of the Arm, Shoulder and Hand and Constant scores of the patients**

Descriptive variables	Mean±SD		P
	HA-based mesh + (n=20)	HA-based mesh - (n=24)	
Age	40.7±16.81	43.83±11.26	0.608
Time to operation (months)	12.00±2.66	11.67±2.64	0.772
Follow time (months)	32.40±7.02	35.75±7.67	0.301
Union time (week)	14.70±1.15	19.58±3.52	0.001
Dash score	7.34±4.38	17.5±8.04	0.002
Constant score	90.20±1.13	81.5±9.46	0.009
LG (cm)	2.10±0.40	0.90±0.23	0.0001

Independent samples *t*-test was used for descriptive data of all patients. n=Number of patients, HA=Hyaluronic acid, LG=Length of gap, SD=Standard deviation

**Table 2: Correlation of the clavicular length of injured and contralateral side after fixation with or without hyaluronic acid-based mesh application**

Comparison of clavicular length	Mean±SD		ρ
	Length of the injured clavicle (mm)	Length of the contralateral clavicle (mm)	
HA-based mesh + (n=20)	165±19.40	166.3±16.94	0.989
HA-based mesh - (n=24)	156.16±16.85	158.08±16.33	

Spearman's correlation test. n=Number of patients, SD=Standard deviation, HA=Hyaluronic acid

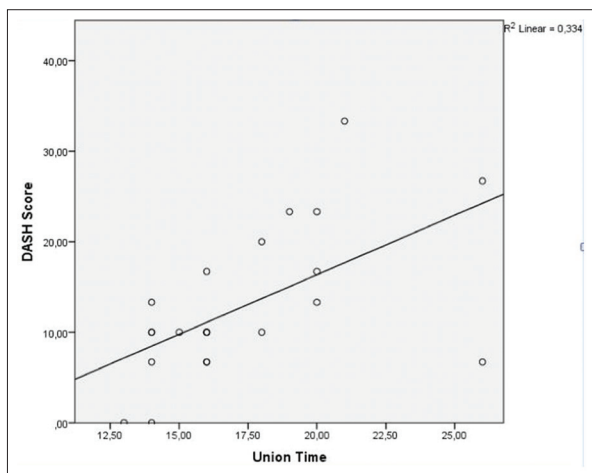


Figure 8: Analysis with Spearman's correlation test for the Disabilities of the Arm, Shoulder and Hand score and union time of the patients

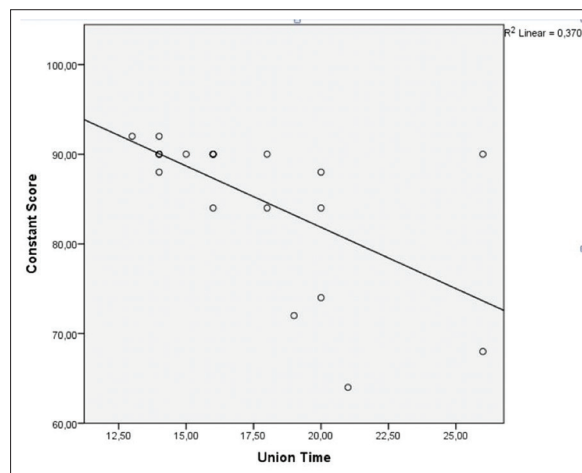


Figure 9: Correlation analysis for Constant score and union time of the patients after clavicular plate fixation

was achieved in all patients with no infection, malunion, or implant deficiency.<sup>10</sup>

HA is an extra cellular glycosaminoglycan found in tissues such as synovial joint fluid, vertebra, and eyes.<sup>9</sup> It is widely used in hydrogel and scaffold forms in biomaterial science.<sup>9</sup> HA-based scaffold is used in several conditions such as filling of defective areas, soft-tissue healing, repair and regeneration of bone and cartilage tissue, repair of nervous and brain tissue, and repair of smooth muscle.<sup>9</sup> It was reported to regulate angiogenesis and contribute to establishment of suitable conditions for tissue healing by preventing graft or graft-like materials from being lost or scattered into the neighboring tissues.<sup>16</sup> In an experimental animal study where bone synthesis was evaluated by scintigraphy, HA-based mesh was detected to stimulate osteoblastic activity and restore disrupted periosteal tissue integrity.<sup>11</sup> In our study, it was remarkable that complete fracture healing was achieved in all nonunion patients who were initially administered HA-based mesh in addition to iliac autograft and in the remaining two patients in Group 1, who further received revised intervention with HA-based mesh. This might be explained by its ability to prevent loss of autograft from the area of union and to provide better periosteal integrity or by its osteogenic and angiogenetic effects, which need to be further investigations by biochemical and histological studies.

Owing to its osteoconductive, osteoinductive, and osteogenic properties, iliac wing autografting is described as the gold standard grafting method in the management of nonunion defects.<sup>17</sup> Iliac autografting plus osteosynthesis with plate has a widespread usage in the treatment of atrophic shortened clavicular nonunion in order to restore the length of the clavicle and accelerate the healing of the fracture. In a retrospective long term study with 58 cases who were treated with plate fixation, those patients who underwent additional autografting were reported to have better bone healing and shoulder function scores with shorter union time and 4.7-fold lesser revision rate compared with those patients who did not receive autograft intervention.<sup>8</sup> On the other hand, there are also studies advocating that bone grafts might not be required in clavicular nonunion. For instance, Huang *et al.*, in their study of 60 cases with clavicular midshaft nonunion where they performed open reduction and plate fixation, reported that those patients with and without iliac autograft did not differ in terms of union time and function scores.<sup>18</sup> In this study, we found complete fracture healing in 20 of 24 patients (83.3%) in locking plate fixation plus iliac autograft group, which is consistent with the literature.

The clavicle increases shoulder joint mobility and strength by stabilizing glenohumeral joint, especially during abduction.<sup>19</sup> Shortening of the clavicle may alter normal shoulder kinematics.<sup>13</sup> The experimental cadaver study by Andermahr *et al.* reported that clavicular shortening

and caudal displacement may lead to shoulder abduction shortening particularly in overhead movements due to ventrocaudomedial shift at the glenohumeral joint.<sup>19</sup> In another cadaver study, Matsumura *et al.* reported that shortening of the clavicle above 10% may limit scapular external rotation and posterior tilt during elevation of the arm.<sup>20</sup> Lazarides and Zafiropoulos assessed  $\geq 1$ -year functional outcomes of 132 patients with clavicular midshaft fracture by modified Constant scores and reported that shortening of the clavicle that was above 14 mm in women and 18 mm in men was associated with unsatisfactory outcomes.<sup>21</sup> Schnetzke *et al.* reported iliac wing autograft that was added to plate fixation in the management of clavicular nonunion to better compensate the original length of the clavicle and to offer better functional outcomes compared to those patients managed with osteosynthesis alone.<sup>8</sup> In this study, fibrous atrophic tissues were debrided initially, which were followed by reconstruction of the consequent defect by iliac wing autograft and rigid osteosynthesis with ALP. Radiological followup of patients revealed that original length of the clavicle could be restored as shown by comparison with the unaffected side in each patient.

The healing time of the fracture in cases where iliac wing graft and plate fixation were performed was reported to be 9–16 weeks.<sup>18-22</sup> In the current study, union time was  $19.58 \pm 3.52$  weeks in the iliac graft alone group that was longer than the literature. The difference may probably be related the lack of environmental blood circulation in atrophic type nonunion.<sup>6</sup> On the other hand, HA-based mesh add-on group had significantly shorter union time than iliac wing autograft alone one ( $14.70 \pm 1.15$  weeks,  $P < 0.001$ ). In addition, shorter union time was related with better shoulder functional results. Owing to its better periosteal integrity, positive effects on angiogenesis and osteogenesis, and ability to reduce loss of iliac wing graft, HA-based mesh might have accelerated fracture healing, which in turn might have improved shoulder function scores by reducing pain and facilitate early ambulation and effective rehabilitation. Clarification of these potential mechanisms warrants designation of prospective, large, and randomized studies with long term outcomes.

Our study has several limitations, including the single-center retrospective design, relatively small size of the population, and absence of the histological assessment.

## Conclusions

HA-based mesh application that is added on the iliac wing autograft appears to be an efficacious alternative in patients who have disrupted periosteal integrity, bone defect, and atrophic and markedly shortened clavicular nonunion after plate fixation.

## Declaration of patient consent

The authors certify that they have obtained all appropriate patient consent forms. In the form, the patients have given

their consent for their images and other clinical information to be reported in the journal. The patients understand that their names and initials will not be published and due efforts will be made to conceal their identity, but anonymity cannot be guaranteed.

### Financial support and sponsorship

Nil.

### Conflicts of interest

There are no conflicts of interest.

### References

1. Postacchini F, Gumina S, De Santis P, Albo F. Epidemiology of clavicle fractures. *J Shoulder Elbow Surg* 2002;11:452-6.
2. Robinson CM. Fractures of the clavicle in the adult. Epidemiology and classification. *J Bone Joint Surg Br* 1998;80:476-84.
3. Postacchini R, Gumina S, Farsetti P, Postacchini F. Long term results of conservative management of midshaft clavicle fracture. *Int Orthop* 2010;34:731-6.
4. Zlowodzki M, Zelle BA, Cole PA, Jeray K, McKee MD; Evidence-Based Orthopaedic Trauma Working Group. Treatment of acute midshaft clavicle fractures: Systematic review of 2144 fractures: On behalf of the evidence-based orthopaedic trauma working group. *J Orthop Trauma* 2005;19:504-7.
5. Kang HJ, Kim HS, Kim SJ, Yoo JH. Osteosynthesis of symptomatic nonunions of type II fractures of the distal clavicle using modified locking T-plate and bone grafting. *J Trauma Acute Care Surg* 2012;72:E14-9.
6. Martetschläger F, Gaskill TR, Millett PJ. Management of clavicle nonunion and malunion. *J Shoulder Elbow Surg* 2013;22:862-8.
7. Nowak J, Holgersson M, Larsson S. Can we predict long term sequelae after fractures of the clavicle based on initial findings? A prospective study with nine to ten years of followup. *J Shoulder Elbow Surg* 2004;13:479-86.
8. Schnetzke M, Morbitzer C, Aytac S, Erhardt M, Frank C, Muenzberg M, *et al.* Additional bone graft accelerates healing of clavicle nonunions and improves long term results after 8.9 years: A retrospective study. *J Orthop Surg Res* 2015;10:2.
9. Collins MN, Birkinshaw C. Hyaluronic acid based scaffolds for tissue engineering – A review. *Carbohydr Polym* 2013;92:1262-79.
10. Tekin AC, Esenyel CZ, Cakar M, Esenyel M, Ozcan Y, Saygili MS, *et al.* Hyalonect in the treatment of pseudarthrosis. *Acta Orthop Traumatol Turc* 2013;47:379-86.
11. Gürbüz B, Pikköken L, Urhan M, Süer BT, Narin Y. Scintigraphic evaluation of early osteoblastic activity in extraction sockets treated with platelet-rich plasma. *J Oral Maxillofac Surg* 2008;66:2454-60.
12. Endrizzi DP, White RR, Babikian GM, Old AB. Nonunion of the clavicle treated with plate fixation: A review of forty-seven consecutive cases. *J Shoulder Elbow Surg* 2008;17:951-3.
13. Rasmussen JV, Jensen SL, Petersen JB, Falstie-Jensen T, Lausten G, Olsen BS, *et al.* A retrospective study of the association between shortening of the clavicle after fracture and the clinical outcome in 136 patients. *Injury* 2011;42:414-7.
14. Hernández-Cortés P, Elizondo-Espósito D, Peña-Rodríguez C, Pajares-López M. Acromial vascularized graft pedicled on the acromial branch of the thoracoacromial trunk for treatment of clavicular pseudoarthrosis. *J Shoulder Elbow Surg* 2012;21:e9-13.
15. Collinge C, Devinney S, Herscovici D, DiPasquale T, Sanders R. Anterior-inferior plate fixation of middle-third fractures and nonunions of the clavicle. *J Orthop Trauma* 2006;20:680-6.
16. Rhodes NP, Hunt JA, Longinotti C, Pavesio A. *In vivo* characterization of hyalonect, a novel biodegradable surgical mesh. *J Surg Res* 2011;168:e31-8.
17. Szpalski M, Gunzburg R. Recombinant human bone morphogenetic protein-2: A novel osteoinductive alternative to autogenous bone graft? *Acta Orthop Belg* 2005;71:133-48.
18. Huang HK, Chiang CC, Su YP, Feng CK, Chiu FY, Liu CL, *et al.* Role of autologous bone graft in the surgical treatment of atrophic nonunion of midshaft clavicular fractures. *Orthopedics* 2012;35:e197-201.
19. Andermahr J, Jubel A, Elsner A, Prokop A, Tsikaras P, Jupiter J, *et al.* Malunion of the clavicle causes significant glenoid malposition: A quantitative anatomic investigation. *Surg Radiol Anat* 2006;28:447-56.
20. Matsumura N, Nakamichi N, Ikegami H, Nagura T, Imanishi N, Aiso S, *et al.* The function of the clavicle on scapular motion: A cadaveric study. *J Shoulder Elbow Surg* 2013;22:333-9.
21. Lazarides S, Zafropoulos G. Conservative treatment of fractures at the middle third of the clavicle: The relevance of shortening and clinical outcome. *J Shoulder Elbow Surg* 2006;15:191-4.
22. Villa JC, van der List JP, Gausden EB, Lorich DG, Helfet DL, Kloen P, *et al.* Plate fixation and bone grafting of distal clavicle nonunions: Radiologic and functional outcomes. *Arch Orthop Trauma Surg* 2016;136:1521-9.