

Trends in Surgical Treatment of Proximal Humeral Fractures and Analysis of Postoperative Complications Over a Decade in 384,158 Patients

Rami G. Alrabaa, MD, Gabrielle Ma, BS, Nicole M. Truong, BS, Drew A. Lansdown, MD, Brian T. Feeley, MD, Alan L. Zhang, MD, and C. Benjamin Ma, MD

Investigation performed at the University of California San Francisco, San Francisco, California

Background: Surgical treatment options for proximal humeral fractures include hemiarthroplasty (HA), reverse shoulder arthroplasty (RSA), and open reduction and internal fixation (ORIF). The objectives of this study were to analyze the trends in surgical treatment of proximal humeral fractures across a decade and to compare complications, reoperation rates, and readmission rates between ORIF and RSA.

Methods: The PearlDiver MUEXtr Database was used to identify patients with proximal humeral fractures who were treated with ORIF, HA, or RSA between 2010 and 2019 and analyze yearly trends. Complications, revision procedures, demographic characteristics, comorbidities, and emergency room visits and hospital readmissions within 90 days of the surgical procedure were compared between ORIF and RSA cohorts for patients who had at least 2-year follow-up data.

Results: In this study, 384,158 patients with proximal humeral fractures were identified in the 10-year period between 2010 and 2019. There was a significant increase in the frequency of RSA and a decrease in the frequency of ORIF and HA over time ($p < 0.0001$). Compared with patients who underwent ORIF or HA, patients who underwent RSA were more likely to be older ($p < 0.0001$), to be female, and to have a higher Charlson Comorbidity Index. Patients who underwent ORIF had higher complication rates (23.03% compared with 18.62%; $p < 0.0001$) and higher reoperation rates (20.3% compared with 10.3%; $p < 0.0001$) than patients who underwent RSA. Patients who underwent RSA had higher emergency room visit rates (20.0% compared with 16.7%; $p < 0.001$) and hospital readmission rates (12.9% compared with 7.3%; $p < 0.0001$) within 90 days of the surgical procedure compared with patients who underwent ORIF.

Conclusions: There has been an increasing trend in RSA utilization for the surgical treatment of proximal humeral fractures, along with a decreasing trend in HA and ORIF, over time. Patients who underwent ORIF for a proximal humeral fracture had higher complication and reoperation rates compared with patients who underwent RSA. Patients who underwent RSA had higher emergency room visit and hospital readmission rates within 90 days of the surgical procedure compared with patients who underwent ORIF, which may be attributable to the RSA cohort being older and having more comorbidities.

Level of Evidence: Therapeutic Level III. See Instructions for Authors for a complete description of levels of evidence.

Proximal humeral fractures are common fragility fractures accounting for up to 6% of all fractures, have a peak incidence in the 60 to 90-year-old age group, and have an economic impact on all health-care systems^{1,2}. An epidemiologic study showed that, in 2008, proximal humeral fractures accounted for approximately 185,000 emergency room visits in the United States alone, as well as an increasing incidence of these fractures over time^{3,4}. The treatment of proximal humeral frac-

tures depends on patient age, activity level, demands, fracture pattern, bone quality, and expectations, among other factors.

When surgical treatment is pursued, the decision to treat with open reduction and internal fixation (ORIF) or reverse shoulder arthroplasty (RSA) can be dictated by the fracture pattern, patient functional status, baseline rotator cuff status, and surgeon preference. In some scenarios, one operation is clearly more favored and indicated than the other. For example,

Disclosure: The **Disclosure of Potential Conflicts of Interest** forms are provided with the online version of the article (<http://links.lww.com/JBJSOA/A431>).

Copyright © 2022 The Authors. Published by The Journal of Bone and Joint Surgery, Incorporated. All rights reserved. This is an open access article distributed under the terms of the [Creative Commons Attribution-Non Commercial-No Derivatives License 4.0](https://creativecommons.org/licenses/by-nc-nd/4.0/) (CCBY-NC-ND), where it is permissible to download and share the work provided it is properly cited. The work cannot be changed in any way or used commercially without permission from the journal.

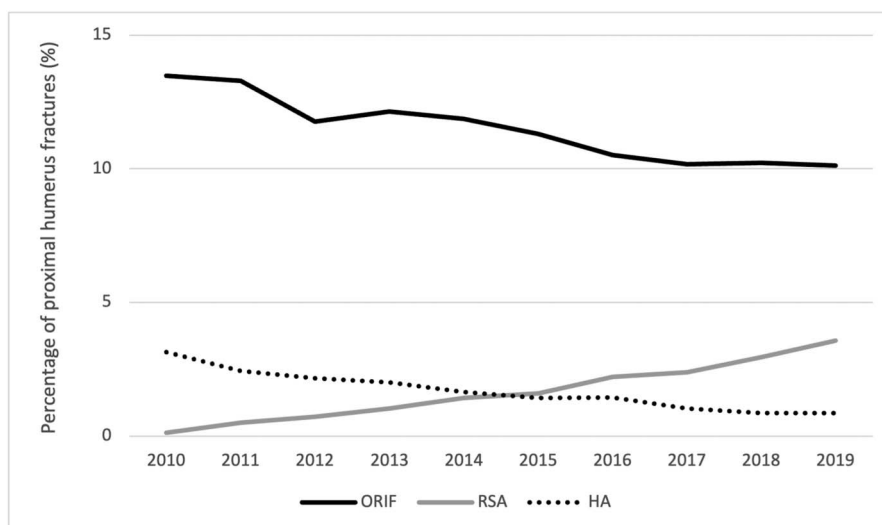


Fig. 1 Frequency of ORIF, HA, and RSA used for treatment of proximal humerus fractures in all patients between 2010 and 2019. There was a significant increasing trend in RSA rates and decreasing trends in HA and ORIF rates ($p < 0.0001$).

in a geriatric patient who has a severely comminuted proximal humeral fracture that is not amenable to fixation and has baseline rotator cuff weakness and low functional demand, surgical treatment in the form of RSA may be preferred, whereas a younger patient with a less comminuted fracture and a high level of function at baseline may be better served with ORIF.

In other cases, either surgical treatment option (RSA or ORIF) may be reasonable and up to patient and surgeon discretion.

For select proximal humeral fractures, ORIF can be an appropriate surgical treatment option as it preserves bone and restores anatomy better compared with RSA, theoretically leading to more favorable patient outcomes⁵. Potential complications of ORIF include osteonecrosis, nonunion, malunion, implant failure, periprosthetic fracture, infection, and rotator cuff tear, among others⁶. Complications of RSA for proximal humeral fractures include periprosthetic fracture, instability, component loosening, and infection⁷. In a recent study, Klug et al. reviewed 60 matched elderly patients who underwent either ORIF or RSA for proximal humeral fractures and found that ORIF resulted in numerically although not significantly greater shoulder range of motion, but with a higher complication rate (30% compared with 10%) and a higher revision rate (20% compared with 3%)⁵. There has been an

increase in shoulder arthroplasties performed in the United States, largely because of increases in RSA, with projections continuing to rise over the next decade⁸. RSA has traditionally been a surgical treatment option for cuff tear arthropathy, massive irreparable cuff tears, and certain proximal humeral fractures. As shoulder arthroplasties, specifically RSA, are becoming more popular, these procedures are performed on younger patients with expanded surgical indications^{9,10}.

The objective of this study was to investigate the trends in treatment selection and compare complication, reoperation, and readmission rates for proximal humeral fractures treated with either ORIF or RSA using an up-to-date nationwide cross-sectional population. Our hypothesis was that RSA increased in popularity compared with ORIF for the treatment of proximal humeral fractures and that patients treated with RSA had lower complication rates and reoperation rates than those who were treated with ORIF.

Materials and Methods

The PearlDiver database includes 144 million patient records from 2010 to the first quarter of 2020 derived from provider networks and insurance claims. Subsets of the database were created that included patients meeting certain

TABLE I Demographic Information of All Patients with Proximal Humeral Fractures Who Underwent RSA, ORIF, or HA Between 2010 and 2019

	RSA Group	ORIF Group	HA Group	P Value
Age* (yr)	71.1 ± 7.6	62.0 ± 14.4	66.2 ± 10.1	<0.0001
Female sex	81.9%	73.5%	74.8%	<0.0001
Charlson Comorbidity Index*	3.08 ± 2.83	1.94 ± 2.59	2.26 ± 2.65	<0.0001

*The values are given as the mean and the standard deviation.

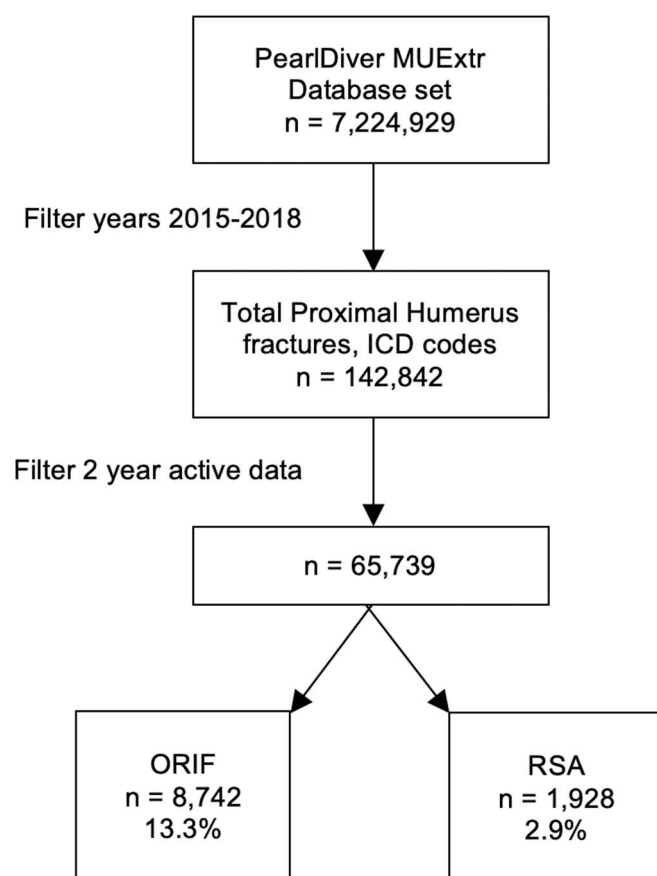


Fig. 2
Flow diagram of patients identified between 2015 and 2018 who sustained a proximal humeral fracture treated with ORIF or RSA and had 2-year follow-up data available.

criteria. The PearlDiver MUEXtr subset was used for the present study, as this subset includes all patients who had undergone a procedure on the upper extremities. Trends in treatment were analyzed by gathering the data of patients with a proximal humeral fracture from the PearlDiver MUEXtr subset from 2010 to 2019 and using procedure codes from the Current Procedural Terminology (CPT), International Classification of Diseases, Ninth Revision (ICD-9), and ICD, Tenth Revision (ICD-10) to identify patients who underwent ORIF, RSA, or hemiarthroplasty (HA) during that time period (see Appendix Tables 1 and 2). The year 2020 was excluded, as there were incomplete data for that year at the time of database query. Trends in management over those 10 years were then analyzed.

Using ICD-10 diagnosis codes, the database was then used to retrospectively search for all patients over the age of 20 years with proximal humeral fractures between 2015 and 2018 (see Appendix Table 1). Only the first instance of a patient's diagnosis of a proximal humeral fracture was included for analysis. Patients diagnosed with concomitant isolated greater tuberosity, humeral shaft, or distal humeral fractures were excluded. This time period was used because ICD-10 coding was introduced in 2015 and laterality could then be tracked

with unique codes for left and right shoulders. Given that the database was active until 2020, only patients with at least 2 years of active data or follow-up were identified and were selected in order to track complications. Patients identified from 2015 to 2018 were used for analysis of complications.

Patients who had a proximal humeral fracture were divided into cohorts with ORIF or RSA treatment on the involved side. The ORIF and RSA procedures were identified using ICD-10 procedure and CPT codes (see Appendix Table 2).

Complications in patients with 2-year follow-up were gathered using ICD-10 diagnostic codes (see Appendix Table 3). Complications for the ORIF cohort included (but were not limited to) osteonecrosis, nonunion, malunion, mechanical implant failure, instability, periprosthetic fracture, infection, and rotator cuff tear. Complications for the RSA cohort included periprosthetic fracture, instability, component loosening, and infection. Reoperations in patients with 2-year follow-up were also gathered using ICD-10 procedural codes (see Appendix Table 4). Reoperations for the ORIF cohort included manipulation under anesthesia, arthroscopic debridement, revision ORIF, removal of the implant, rotator cuff repair, revision to arthroplasty, and irrigation and debridement. Reoperations for the RSA cohort included explantation and insertion of a spacer, manipulation under anesthesia, arthroscopic debridement, reduction of a dislocated implant, revision arthroplasty, and irrigation and debridement. Hospital readmissions and emergency room visits within 90 days of the surgical procedure were also obtained for each ORIF and RSA cohort.

Demographic data including age, gender, and comorbidities were collected for the RSA and ORIF cohorts. Comorbidities were identified using ICD-9 and ICD-10 diagnosis codes and included obesity, diabetes, hypertension, tobacco use, alcohol use, congestive, ischemic heart disease, pulmonary heart disease, and coronary artery disease. The Charlson Comorbidity Index was calculated, as this index has been shown to be a marker of patients' general health¹¹.

The R software program (version 4.1.0; The R Foundation for Statistical Computing) integrated into PearlDiver was used for statistical analysis. Chi-square analysis was used for the comparison of complications, reoperations, and readmissions between ORIF and RSA. Logistic regression analysis was used to generate odd ratios (ORs) to compare the relative frequencies of

TABLE II Demographic Information of Patients with Proximal Humeral Fractures Who Underwent ORIF or RSA with 2-Year Follow-up Data Available

	RSA Group	ORIF Group	P Value
Age* (yr)	70.5 ± 7.6	62.3 ± 14.0	<0.0001
Female sex	83.2%	75.2%	<0.0001
Charlson Comorbidity Index*	3.51 ± 3.14	2.3 ± 2.84	<0.0001

*The values are given as the mean and the standard deviation.

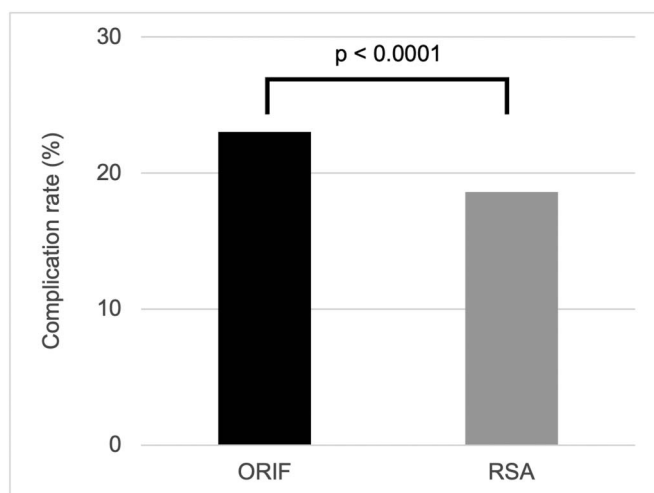


Fig. 3
The complication rate was higher for patients with a proximal humeral fracture who underwent ORIF compared with those who underwent RSA (23.03% compared with 18.62%; $p < 0.0001$). Patients included in these cohorts had at least 2 years of active data.

procedures being performed. The Mann-Kendall trend test was used to analyze management trends. Significance was defined as $p < 0.05$.

Source of Funding

There was no funding source for this study.

Results

Trends in Management

Between 2010 and 2019, 384,158 patients with proximal humeral fractures were identified, most of whom were treated nonoperatively. The trends in surgical management of proximal humeral fractures over the 10 years showed decreasing frequency of ORIF and HA and increasing frequency of RSA (Fig. 1). In the 10 years studied, the rates of ORIF decreased from 13.5% to 10.1%, the rates of HA decreased from 3.1% to 0.9%, and the rates of RSA increased from 0.1% to 3.6%.

The Mann-Kendall trend test confirmed a significant increasing trend of RSA rates and decreasing trends in HA and ORIF rates over the time period ($p < 0.0001$). When comparing patients with proximal humeral fractures between 2010 and 2019, patients in 2019 were more likely to undergo RSA (OR, 29.57 [95% confidence interval (CI), 21.81 to 40.08]) and less likely to undergo ORIF (OR, 0.72 [95% CI, 0.69 to 0.76]) or HA (OR, 0.27 [95% CI, 0.24 to 0.31]).

Compared with patients undergoing ORIF or HA, patients undergoing RSA were more likely to be older, to be female, and to have a higher Charlson Comorbidity Index ($p < 0.0001$ for all) (Table I).

Complications and Reoperations

Between 2015 and 2018, a total of 142,842 patients with proximal humeral fractures were identified by ICD-10 codes. Only patients with 2 years of active data were selected, yielding a total

of 65,739 patients. A majority of the patients were treated nonoperatively, and 8,742 patients (13.3%) underwent ORIF and 1,928 patients (2.9%) underwent RSA (Fig. 2). Patients who underwent RSA in that cohort were more likely to be female, older, and have a higher Charlson Comorbidity Index compared with those undergoing ORIF ($p < 0.0001$ for all) (Table II).

Complications were recorded for the ORIF and RSA cohorts. The complication rate in patients with at least 2 years of active data was 23.03% (2,013 patients) for the ORIF cohort, compared with 18.62% (359 patients) for the RSA cohort ($p < 0.0001$) (Fig. 3). The most common complication after ORIF was stiffness, followed by nonunion and rotator cuff tear. The most common complication after RSA was stiffness, followed by dislocation (Table III).

The reoperation rate for patients who underwent ORIF was higher (20.3%) than for patients who underwent RSA (10.3%) ($p < 0.0001$) (Fig. 4). Reoperations for patients who underwent ORIF included the removal of the implant, revision ORIF, revision to arthroplasty, manipulation under anesthesia, arthroscopic debridement, explantation and insertion of a spacer, irrigation and debridement, rotator cuff repair, and reduction of a dislocation. Reoperations for patients who underwent RSA included explantation and insertion of a spacer, revision arthroplasty, irrigation and debridement, manipulation under anesthesia, and reduction of a dislocation. The most common reoperation after ORIF was the removal of the implant, followed by revision ORIF. The most common reoperation after RSA was explantation and insertion of a spacer, followed by revision arthroplasty (Table IV).

Patients who underwent RSA, compared with patients who underwent ORIF, for proximal humeral fractures had higher rates

TABLE III Complications in Patients Who Underwent Initial ORIF or RSA for Proximal Humeral Fracture Between 2015 and 2018 with 2-Year Follow-up Data Available*

Complication	ORIF Group (N = 8,742)	RSA Group (N = 1,928)
Stiffness	1,161 (13.3%)	275 (14.3%)
Nonunion	399 (4.6%)	—
Rotator cuff tear	389 (4.5%)	—
Implant failure	121 (1.4%)	<11
Infection	95 (1.1%)	12 (0.62%)
Osteonecrosis	51 (0.58%)	—
Fracture	47 (0.54%)	30 (1.6%)
Instability	44 (0.50%)	18 (0.93%)
Malunion	26 (0.30%)	—
Nerve injury	<11	—
Hematoma	<11	<11
Dislocation	—	47 (2.4%)

*The values are given as the number of patients, with or without the percentage in parentheses. If the number of patients in a certain cohort of patients in the database is <11 but not 0, the database does not provide discrete numbers.

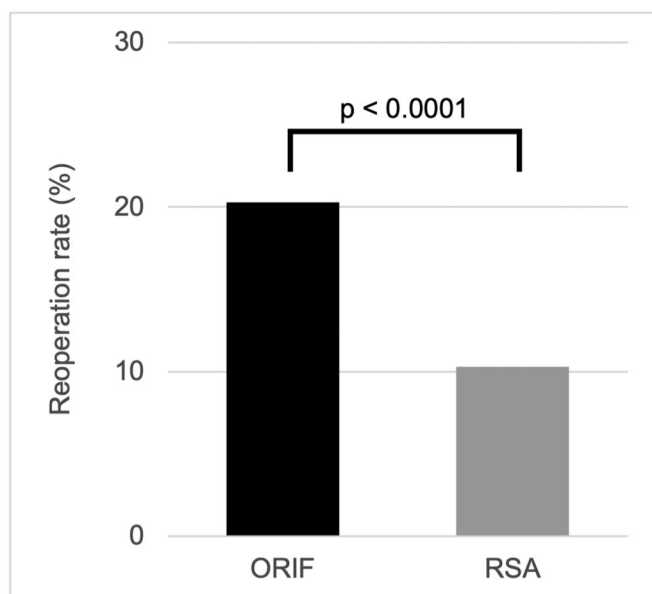


Fig. 4
The reoperation rate was higher for patients with a proximal humeral fracture who underwent ORIF compared with those who underwent RSA (20.3% compared with 10.3%; $p < 0.0001$). Patients included in these cohorts had at least 2 years of active data.

of emergency room visits (20.0% compared with 16.7%; $p < 0.001$) and hospital readmission (12.9% compared with 7.3%; $p < 0.0001$) within 90 days of the surgical procedure (Fig. 5).

Discussion

In the present study, analysis of trends among almost 400,000 patients with proximal humeral fractures over a decade (2010 to 2019) using a national database showed decreasing rates of ORIF and HA and increasing rates of RSA. This finding is consistent with several previous studies showing that RSA has become increasingly popular in the United States following its Food and Drug Administration (FDA) approval in 2003¹². RSA was initially introduced as a treatment option for pseudoparalytic shoulders with cuff tear arthropathy, and indications have expanded over the years to include treatment for massive irreparable rotator cuff tears, glenoid bone loss, failed anatomic arthroplasty, proximal humeral tumors, and proximal humeral fractures¹³. As RSA has grown in popularity, HA has become a less popular arthroplasty choice for the treatment of proximal humeral fractures. A similar study evaluating patients between 2011 and 2013 from the National Inpatient Sample database showed that the rates of RSA almost doubled and rates of ORIF and HA decreased during that time period for the treatment of proximal humeral fractures¹⁴. The present study found similar trends but over a longer time period and in a larger patient sample. Trends of increased RSA utilization have also been reported in international data samples from Germany, South Korea, Sweden, and Finland¹⁵⁻¹⁸.

Although the overall number of patients undergoing ORIF is still higher than that of patients undergoing RSA for fracture management, we believe that, as the trends continue in

this manner, RSA will become the most popular procedure for the treatment of proximal humeral fractures, especially in the elderly population. In the elective setting for the treatment of shoulder arthritis, RSA has recently become more popular than anatomic total shoulder arthroplasty and is being performed on younger patients with expanded surgical indications^{9,10,19}. One of the challenges of ORIF and HA is achieving reliable tuberosity healing, which is not as much of a concern in RSA as the implant alters shoulder biomechanics to achieve active shoulder motion independent of rotator cuff function^{20,21}.

Another aim of this study was to evaluate complications and reoperations between RSA and ORIF. Patients who underwent ORIF had higher complication rates and double the reoperation rate compared with patients who underwent RSA. It is important to note that the majority of the reoperations in the ORIF cohort were the removal of the implant, and explantation and insertion of a spacer was the most common reoperation in the RSA cohort; this suggests that although the reoperation rate may be higher in the ORIF cohort, the severity of reoperation may be greater in the RSA cohort. In a retrospective review of 60 matched patients with proximal humeral fractures, Klug et al.⁵ compared outcomes between ORIF and RSA and found results that were similar to those in the present study, with higher complication rates (30% compared with 10%) and revision rates (20% compared with 3%) in the ORIF cohort. Those authors did note that ORIF resulted in numerically but not significantly greater range of motion compared with patients who underwent RSA, with mixed results when comparing patient-reported outcomes; the ORIF cohort had better patient-reported outcome scores with regard to the Oxford Shoulder Score and Disabilities of the Arm, Shoulder and Hand (DASH) Questionnaire score but no difference in the American Shoulder and Elbow Surgeons

TABLE IV Reoperations in Patients Who Underwent Initial ORIF or RSA for Proximal Humeral Fracture Between 2015 and 2018 with 2-Year Follow-up Data Available*

Reoperation	ORIF Group (N = 8,742)	RSA Group (N = 1,928)
Removal of implant	913 (10.4%)	—
Revision ORIF	223 (2.6%)	—
Revision arthroplasty	183 (2.1%)	75 (3.9%)
Manipulation under anesthesia	158 (1.8%)	13 (0.67%)
Arthroscopic debridement	117 (1.3%)	<11
Explantation and insertion of spacer	65 (0.74%)	82 (4.3%)
Irrigation and debridement	56 (0.64%)	17 (0.88%)
Rotator cuff repair	36 (0.41%)	—
Reduction of dislocation	22 (0.25%)	12 (0.62%)
ORIF	—	<11

*The values are given as the number of patients, with the percentage in parentheses. If the number of patients in a certain cohort of patients in the database is <11 but not 0, the database does not provide discrete numbers.

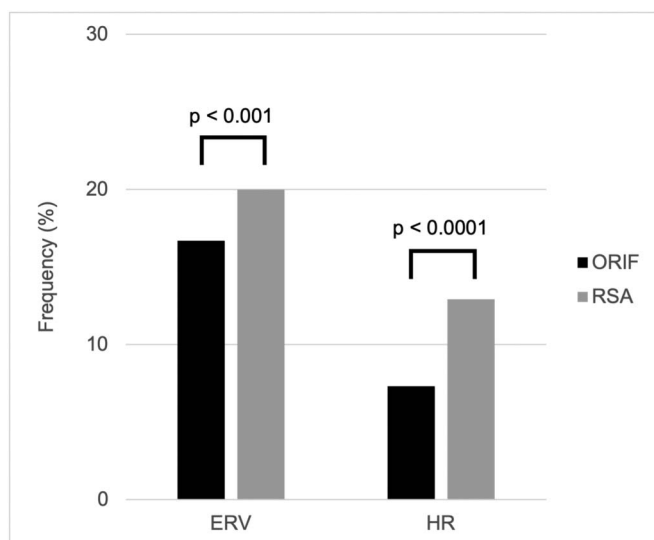


Fig. 5
Patients who underwent RSA for a proximal humeral fracture had higher rates of emergency room visits (ERV) and higher rates of hospital readmissions (HR), compared with patients who underwent ORIF, within 90 days of the surgical procedure.

(ASES) shoulder score or the Constant-Murley shoulder score. Another recent retrospective series of 125 patients with proximal humeral fractures also showed higher complication rates (37.8% compared with 22.0%) and higher reoperation rates (12.1% compared with 5.1%) in the ORIF cohort compared with RSA cohort²². A recent systematic review and meta-analysis including 51 studies and around 3,000 patients with proximal humeral fractures showed that patients who underwent RSA had a lower risk of complications (relative risk, 0.41), lower reoperation rates (relative risk, 0.28), higher Constant scores, and improved active forward elevation compared with patients who underwent HA, but, because of the studies included, no comparison could be made between patients who underwent RSA and those who underwent ORIF²³. In general, a review of the current literature seems to favor RSA over ORIF for the treatment of proximal humeral fractures, especially in the elderly population, and RSA may also be associated with higher quality of life and increased cost-effectiveness²⁴. Moreover, a retrospective study of 1,624 patients indicated that there is a higher reoperation rate following arthroplasty for failed ORIF (19.4%) compared with primary arthroplasty (4.4%) for the treatment of proximal humeral fractures²⁵.


Although this study showed lower complication and reoperation rates for patients with proximal humeral fractures who underwent RSA, those patients also had higher emergency room

visit and hospital readmission rates within 90 days after the surgical procedure compared with patients who underwent ORIF. This may be attributable to patients who underwent RSA being older and having more comorbidities (Table II) and may not necessarily be attributable to the shoulder pathology itself. In a retrospective review of approximately 27,000 patients with proximal humeral fractures treated with either ORIF or RSA, Zhang et al. demonstrated that the majority of unplanned hospital readmissions were associated with medical diagnoses and not surgical complications²⁶.

This study was not without limitations, most of which were inherent to large, retrospective database studies. Given that practitioners and coders are submitting diagnostic and procedural codes, there is a potential for human error involving coding and billing. This study showed trends in the choice among different treatments and differences in complication rates, but, because it was a retrospective database study, it was inclusive of all proximal humeral fractures and thus all fracture types were analyzed together; different fracture patterns may be best suited by certain treatments. Furthermore, this database includes data only from the United States and may not be reflective of global or other international trends and outcomes.

In conclusion, from 2010 to 2019, there was a trend of increasing RSA and decreasing HA and ORIF for the surgical treatment of proximal humeral fractures. Patients who underwent RSA had lower complication and reoperation rates within 2 years after the surgical procedure compared with patients who underwent ORIF. Patients who underwent RSA did have a higher hospital readmission rate after the surgical procedure, which may be attributable to patients who underwent RSA being relatively older and having more comorbidities.

Appendix

 Supporting material provided by the authors is posted with the online version of this article as a data supplement at [jbjs.org \(http://links.lww.com/JBJSOA/A432\)](http://links.lww.com/JBJSOA/A432). ■

Rami G. Alrabaa, MD¹
Gabrielle Ma, BS¹
Nicole M. Truong, BS¹
Drew A. Lansdown, MD¹
Brian T. Feeley, MD¹
Alan L. Zhang, MD¹
C. Benjamin Ma, MD¹

¹University of California San Francisco, San Francisco, California

Email for corresponding author: raminjms@gmail.com

References

1. Court-Brown CM, Caesar B. Epidemiology of adult fractures: a review. *Injury*. 2006 Aug;37(8):691-7.
2. Slobogean GP, Johal H, Lefavre KA, MacIntyre NJ, Sprague S, Scott T, Guy P, Crompton PA, McKee M, Bhandari M. A scoping review of the proximal humerus fracture literature. *BMC Musculoskelet Disord*. 2015 May 10;16:112.
3. Kim SH, Szabo RM, Marder RA. Epidemiology of humerus fractures in the United States: nationwide emergency department sample, 2008. *Arthritis Care Res (Hoboken)*. 2012 Mar;64(3):407-14.
4. Palvanen M, Kannus P, Niemi S, Parkkari J. Update in the epidemiology of proximal humeral fractures. *Clin Orthop Relat Res*. 2006 Jan;442(442):87-92.

5. Klug A, Harth J, Hoffmann R, Gramlich Y. Surgical treatment of complex proximal humeral fractures in elderly patients: a matched-pair analysis of angular-stable plating vs. reverse shoulder arthroplasty. *J Shoulder Elbow Surg.* 2020 Sep;29(9):1796-803.
6. Südkamp N, Bayer J, Hepp P, Voigt C, Oestern H, Kääh M, Luo C, Plecko M, Wendt K, Köstler W, Konrad G. Open reduction and internal fixation of proximal humeral fractures with use of the locking proximal humerus plate. Results of a prospective, multicenter, observational study. *J Bone Joint Surg Am.* 2009 Jun;91(6):1320-8.
7. Boileau P. Complications and revision of reverse total shoulder arthroplasty. *Orthop Traumatol Surg Res.* 2016 Feb;102(1)(Suppl):S33-43.
8. Wagner ER, Farley KX, Higgins I, Wilson JM, Daly CA, Gottschalk MB. The incidence of shoulder arthroplasty: rise and future projections compared with hip and knee arthroplasty. *J Shoulder Elbow Surg.* 2020 Dec;29(12):2601-9.
9. Westermann RW, Pugely AJ, Martin CT, Gao Y, Wolf BR, Hettrich CM. Reverse shoulder arthroplasty in the United States: a comparison of national volume, patient demographics, complications, and surgical indications. *Iowa Orthop J.* 2015;35:1-7.
10. Chalmers PN, Salazar DH, Romeo AA, Keener JD, Yamaguchi K, Chamberlain AM. Comparative utilization of reverse and anatomic total shoulder arthroplasty: a comprehensive analysis of a high-volume center. *J Am Acad Orthop Surg.* 2018 Dec 15;26(24):e504-10.
11. Charlson ME, Pompei P, Ales KL, MacKenzie CR. A new method of classifying prognostic comorbidity in longitudinal studies: development and validation. *J Chronic Dis.* 1987;40(5):373-83.
12. Han RJ, Sing DC, Feeley BT, Ma CB, Zhang AL. Proximal humerus fragility fractures: recent trends in nonoperative and operative treatment in the Medicare population. *J Shoulder Elbow Surg.* 2016 Feb;25(2):256-61.
13. Rugg CM, Coughlan MJ, Lansdown DA. Reverse total shoulder arthroplasty: biomechanics and indications. *Curr Rev Musculoskelet Med.* 2019 Dec;12(4):542-53.
14. Rajae SS, Yalamanchili D, Noori N, Debbi E, Mirocha J, Lin CA, Moon CN. Increasing use of reverse total shoulder arthroplasty for proximal humerus fractures in elderly patients. *Orthopedics.* 2017 Nov 1;40(6):e982-9.
15. Klug A, Gramlich Y, Wincheringer D, Schmidt-Horlohé K, Hoffmann R. Trends in surgical management of proximal humeral fractures in adults: a nationwide study of records in Germany from 2007 to 2016. *Arch Orthop Trauma Surg.* 2019 Dec; 139(12):1713-21.
16. Jo YH, Lee KH, Lee BG. Surgical trends in elderly patients with proximal humeral fractures in South Korea: a population-based study. *BMC Musculoskelet Disord.* 2019 Mar 30;20(1):136.
17. Sumrein BO, Huttunen TT, Launonen AP, Berg HE, Felländer-Tsai L, Mattila VM. Proximal humeral fractures in Sweden-a registry-based study. *Osteoporos Int.* 2017 Mar;28(3):901-7.
18. Huttunen TT, Launonen AP, Pihlajamäki H, Kannus P, Mattila VM. Trends in the surgical treatment of proximal humeral fractures - a nationwide 23-year study in Finland. *BMC Musculoskelet Disord.* 2012 Dec 29;13:261.
19. Ma GC, Bradley KE, Jansson H, Feeley BT, Zhang AL, Ma CB. Surgical complications after reverse total shoulder arthroplasty and total shoulder arthroplasty in the United States. *J Am Acad Orthop Surg Glob Res Rev.* 2021 Jul 20;5(7).
20. Berliner JL, Regalado-Magdos A, Ma CB, Feeley BT. Biomechanics of reverse total shoulder arthroplasty. *J Shoulder Elbow Surg.* 2015 Jan;24(1):150-60.
21. Mata-Fink A, Meinke M, Jones C, Kim B, Bell JE. Reverse shoulder arthroplasty for treatment of proximal humeral fractures in older adults: a systematic review. *J Shoulder Elbow Surg.* 2013 Dec;22(12):1737-48.
22. Klug A, Wincheringer D, Harth J, Schmidt-Horlohé K, Hoffmann R, Gramlich Y. Complications after surgical treatment of proximal humerus fractures in the elderly: an analysis of complication patterns and risk factors for reverse shoulder arthroplasty and angular-stable plating. *J Shoulder Elbow Surg.* 2019 Sep;28(9):1674-84.
23. Pizzo RA, Gianakos AL, Haring RS, Gage MJ, Stevens NM, Liporace FA, Yoon RS. Are arthroplasty procedures really better in the treatment of complex proximal humerus fractures? A comprehensive meta-analysis and systematic review. *J Orthop Trauma.* 2021 Mar 1;35(3):111-9.
24. Austin DC, Torchia MT, Tosteson ANA, Gitajn IL, Tapp SJ, Bell JE. The cost-effectiveness of reverse total shoulder arthroplasty versus open reduction internal fixation for proximal humerus fractures in the elderly. *Iowa Orthop J.* 2020;40(2):20-9.
25. Nowak LL, Hall J, McKee MD, Schemitsch EH. A higher reoperation rate following arthroplasty for failed fixation versus primary arthroplasty for the treatment of proximal humeral fractures: a retrospective population-based study. *Bone Joint J.* 2019 Oct;101-B(10):1272-9.
26. Zhang AL, Schairer WW, Feeley BT. Hospital readmissions after surgical treatment of proximal humerus fractures: is arthroplasty safer than open reduction internal fixation? *Clin Orthop Relat Res.* 2014 Aug;472(8):2317-24.