

# Efficacy of endoscopic ligation with O-ring closure for prevention of bleeding after gastric endoscopic submucosal dissection under antithrombotic therapy: a prospective observational study




## Authors

Noriko Nishiyama<sup>1</sup> , Hideki Kobara<sup>1</sup> , Nobuya Kobayashi<sup>1</sup> , Taiga Chiyo<sup>1</sup>, Naoya Tada<sup>1</sup>, Kazuhiro Kozuka<sup>1</sup>, Takanori Matsui<sup>1</sup>, Tatsuo Yachida<sup>1</sup>, Shintaro Fujihara<sup>1</sup>, Tingting Shi<sup>1</sup>, Tsutomu Masaki<sup>1</sup>

## Institution

1 Department of Gastroenterology and Neurology,  
Faculty of Medicine, Kagawa University, Kagawa, Japan

submitted 28.10.2021

accepted after revision 7.3.2022

published online 25.2.2022

## Bibliography

Endoscopy 2022; 54: 1078–1084

DOI 10.1055/a-1782-3448

ISSN 0013-726X

© 2022. The Author(s).

This is an open access article published by Thieme under the terms of the Creative Commons Attribution-NonDerivative-NonCommercial License, permitting copying and reproduction so long as the original work is given appropriate credit. Contents may not be used for commercial purposes, or adapted, remixed, transformed or built upon. (<https://creativecommons.org/licenses/by-nc-nd/4.0/>)

Georg Thieme Verlag KG, Rüdigerstraße 14,  
70469 Stuttgart, Germany

 Supplementary material

Supplementary material is available under

<https://doi.org/10.1055/a-1782-3448>

 Scan this QR-Code for the author commentary.



## Corresponding author

Noriko Nishiyama, MD, PhD, Department of Gastroenterology and Neurology, Faculty of Medicine, Kagawa University, 1750-1 Ikenobe, Miki, Kita, Kagawa 761-0793, Japan  
[n.nori.ocean@gmail.com](mailto:n.nori.ocean@gmail.com)

## ABSTRACT

**Background** We examined the efficacy of a novel endoscopic ligation technique with O-ring closure (E-LOC) to prevent bleeding after gastric endoscopic submucosal dissection (ESD) under antithrombotic therapy.

**Methods** This single-center prospective study involved consecutive patients who were taking antithrombotic agents and underwent gastric ESD. E-LOC was performed by anchoring the nylon loop with hemoclips on both defect edges and/or the exposed muscle layer, and using O-ring band ligation around these deployed clips. The primary outcome was post-ESD bleeding rate. Secondary outcomes were complete closure rate, procedure time, sustained closure rate, and complications.

**Results** 48 patients were finally analyzed. The post-ESD bleeding rate was 0%, the complete closure rate was 97.9%, and the mean closure time was 29.9 minutes. The sustained closure rate was 95.8% at postoperative day 2–3 and 33.3% at postoperative day 10–11. No complications occurred.

**Conclusion** E-LOC may be an effective option for closing mucosal defects after gastric ESD under antithrombotic therapy. However, the preventive effect on post-ESD bleeding should be further investigated in high risk groups.

## Introduction

Gastric bleeding is the most common adverse event after gastric endoscopic submucosal dissection (ESD) [1]. Notably, a meta-analysis indicated that antithrombotic therapy increased the risk of gastric post-ESD bleeding, with extremely high rates of 11.1%–45.4% in patients taking multiple antithrombotic drugs [2]. Prophylactic endoscopic closure of the mucosal defect is considered an effective measure [3]; however, there is

still no convenient and reliable closure technique for the stomach because of its thick wall. Importantly, even successful mucosal closure results in the formation of a submucosal pocket, leading to early mucosal dehiscence [4]. We developed a novel closure method using an O-ring band for use with the endoscopic variceal ligation (EVL) device, referred to as endoscopic ligation with O-ring closure (E-LOC) [5]. E-LOC using a single-channel scope prevents submucosal pocket formation by anchoring the muscle layer.

In this study, we evaluated the effectiveness of E-LOC for the prevention of gastric post-ESD bleeding in patients on antithrombotic therapy.

## Methods

### Study design and patients

This single-center prospective observational study was conducted between December 2019 and October 2020. Consecutive patients taking antithrombotic agents who underwent gastric ESD were enrolled. The study was approved by the Clinical Ethics Committee of Kagawa University Hospital (Registration No. 2019-185, approval date: 11 December 2019) in accordance with the Helsinki Declaration. All patients provided written informed consent to undergo the procedures and participate in the study.

The inclusion criteria were: treatment by ESD for early gastric carcinoma or adenoma that could not be preoperatively distinguished from early gastric carcinoma based on the Japanese Gastroenterological Endoscopy Society (JGES) criteria; current therapy with at least one antithrombotic drug; age  $\geq$  20 years; Eastern Cooperative Oncology Group performance status 0 or 1; and no metastasis on preoperative computed tomography. Antithrombotic therapy was managed during the perioperative period according to the JGES guidelines [6]. The exclusion criteria were: neoplasms located in or extending into the narrow lumen of the pyloric ring or cardia; neoplasms involving more than half the circumference of the stomach regardless of lesion size (which could lead to stenosis following E-LOC); and patient refusal to undergo follow-up endoscopy.

### E-LOC technique

E-LOC was performed to close the mucosal defect after ESD (► **Video 1**). The technical steps are summarized in ► **Fig. 1**. Images from two representative cases with lesions located at the angle of the stomach are shown in ► **Fig. 2**. Both the ESD and E-LOC procedures were performed by one of six endoscopists (N.N., H.K., N.K., T.C., N.T., K.K.), who had received a lecture related to E-LOC and had performed the procedure at least once under the guidance of an experienced endoscopist (N.N., H.K.).

### Post-ESD follow-up

The patients took oral esomeprazole magnesium (20 mg/day) or potassium-competitive acid blocker (20 mg/day) for 2 months after ESD. Laboratory data were checked on postoperative days (PODs) 1 and 4, and vital signs and physical findings were checked every day during hospitalization. If no physical symptoms appeared, patients were allowed to drink water on POD 1 and a liquid diet was started on POD 2, after evaluation of blood test results. Second-look endoscopy was scheduled for POD 2–3 and third-look endoscopy for POD 10–11 to check for wound dehiscence and post-ESD complications. In the absence of complications, the patients were discharged on POD 12–13.

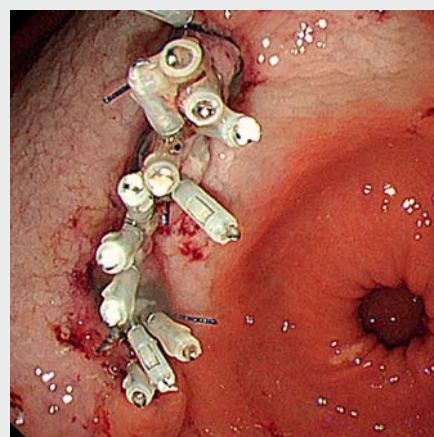
## Study outcomes

The primary outcome was the rate of post-ESD bleeding, defined as clinical evidence of bleeding (hematemesis or melena, or  $a > 2$  g/dL decrease in serum hemoglobin) requiring endoscopic hemostasis. Secondary outcomes were complete closure rate, procedure time, sustained closure rates at POD 2–3 and 10–11, and procedure-associated complication rate. Complete defect closure was defined as successful closure covering  $> 90\%$  of the maximum wound length without submucosal pocket creation. The procedure time was defined as the duration between placement of the first and final clip anchors on the defect. Sustained, partial, and unsustained closure were defined as maintenance of the wound length at  $> 80\%$ , 50% to  $< 80\%$ , and  $< 50\%$ , respectively.

We also compared the clinical efficiency of closure using E-LOC with that in a historical control cohort. This control group comprised 50 consecutive patients on antithrombotic therapy who underwent gastric ESD between December 2018 and November 2019 but who did not achieve mucosal defect closure. We also compared post-ESD bleeding rates between the E-LOC group and the control group.

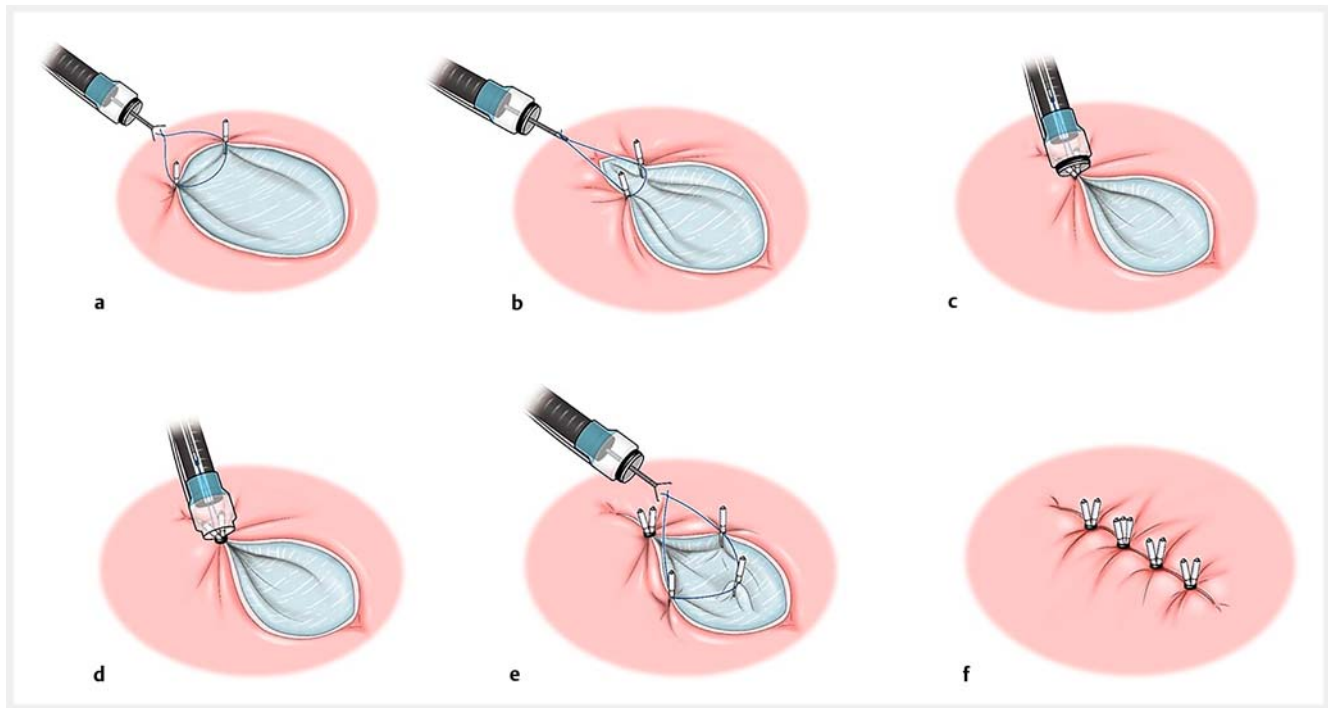
## Statistical analysis

Simple descriptive statistics were used to present proportions and characteristics of the outcomes. Categorical variables were expressed as absolute and relative frequencies. Differences in categorical variables between E-LOC and no-closure groups were examined by Fisher's exact test when required. Continuous variables were compared using Wilcoxon rank sum test.  $P < 0.05$  was considered statistically significant. All statistical analyses were conducted using JMP 15.1.0 (SAS Institute Inc., Cary, North Carolina, USA).



► **Video 1** Use of endoscopic ligation with O-ring closure technique to close a 45-mm-diameter mucosal defect at the angle of the stomach in a 71-year-old man with early gastric cancer who was taking antithrombotics.

Online content viewable at:  
<https://doi.org/10.1055/a-1782-3448>



► **Fig. 1** Schematic illustration of endoscopic ligation with O-ring closure (E-LOC) procedure. **a** A 2-cm-diameter 3-0 surgical nylon loop was positioned around the defect and two hemoclips were used to anchor the loop on both edges of the defect. **b** Grasping forceps were used to grasp the loop and pull it into the cap of the endoscopic variceal-ligation device. **c** Two or three deployed hemoclips were pulled into the cap. **d** An O-ring was fired around these hemoclips to close the proximal side of the defect. **e** Additional muscle-layer clipping was performed at the center of the defect. One O-ring was used for every 1-cm length of defect. **f** If the mucosal defect was exposed in a gap between deployed O-rings, additional closure using hemoclips was performed. Finally, the whole defect was completely closed. Source: Yoshihiko Tsuda, Davinchi Medical Illustration Office.

### Sample size calculation

At our institution, the incidence of post-ESD bleeding among patients receiving antithrombotic agents between December 2018 and October 2019 was 16.7% (7/42, 95%CI 8.3%–30.6%). Assuming that the incidence after E-LOC was 1, the post-ESD bleeding rate after E-LOC was calculated as 2% (1/50, 95%CI 0.4%–10.5%). The lower CI for the incidence of post-ESD bleeding after E-LOC was set as the historical control. The sample size calculation was based on the parameters  $\alpha=0.05$  (2-sided), power  $(1-\beta)=0.8$ , event rate in the experimental E-LOC group = 0.004, and event rate in the control group = 0.167. The resulting total sample size was 84, requiring 42 cases in each group. Considering some excluded cases, 50 cases were set as the target sample size at the beginning of the study.

## Results

### Patients and ESD procedures

Of 231 patients who underwent gastric ESD between December 2019 and October 2020, 55 consecutive patients who were on antithrombotic therapy were eligible for E-LOC and were initially included. However, seven patients refused third-look endoscopy on POD 10–11 and were subsequently excluded, and therefore 48 patients were included in the final analysis. **Fig. 1s** in the online-only Supplementary Material shows the

flow chart of patient enrollment, and ► **Table 1** shows the baseline patient and lesion characteristics, and ESD outcomes.

Antithrombotic therapy consisted of single antiplatelet therapy (72.9%; aspirin/thienopyridine/cilostazol in 52.1%/16.7%/4.2%, respectively), dual antiplatelet therapy (2.1%), and anticoagulation agent (18.8%; warfarin/direct oral anticoagulants in 4.2%/14.6%, respectively). The rate of continuous antithrombotic use was 25.0%, and there was no heparin replacement.

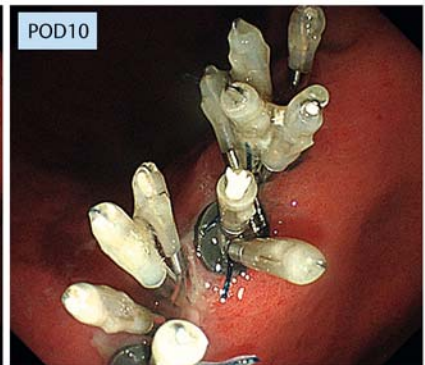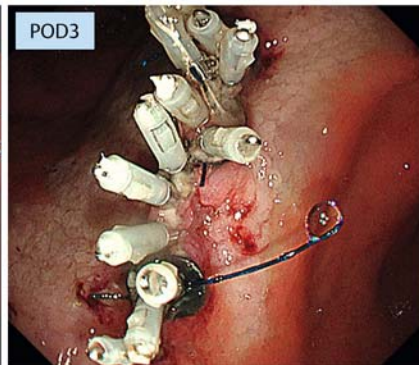
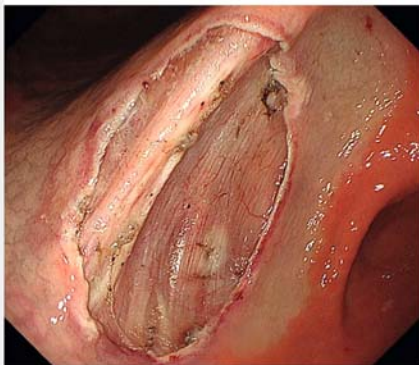
### Outcomes of E-LOC

► **Table 2** shows the outcomes of E-LOC. The post-ESD bleeding rate was 0% and the complete closure rate was 97.9% (47/48). The mean procedure time was 29.9 (SD 12.5) minutes. The sustained closure rates were 95.8% at POD 2–3 and 33.3% at POD 10–11. Detailed data relating to the location and circumference of successful sustained closure at POD 10–11 are shown in ► **Table 2**. No procedure-associated complications occurred.

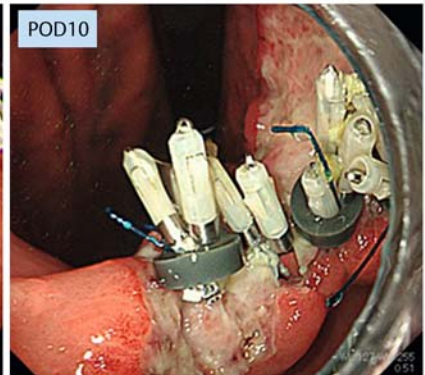
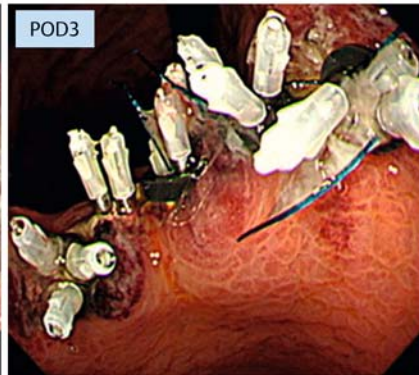
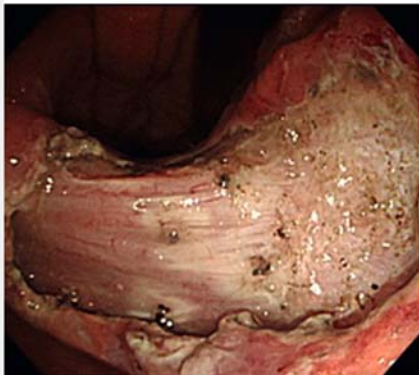In the comparative analysis with the historical cohort, no significant differences were found in patient and lesion characteristics between the two groups. Post-ESD bleeding rate was significantly lower in the E-LOC group (0/48) than in the control group (10/50 [20%];  $P=0.001$ ) (**Table 1s**).



Case 1



Case 2



► **Fig. 2** Endoscopic ligation with O-ring closure: representative cases for lesions located at the angle of the stomach. Case 1 had complete closure and sustained closure on postoperative days (PODs) 3 and 10, respectively. Case 2 had complete closure, sustained closure on POD 3, but unsustained closure on POD 10; the hemoclips appeared to be repelled from the anchored edges of the ulcer, although the O-ring band itself remained in situ on POD 10.

## Discussion

In the present study, there was no post-ESD bleeding in any patient treated with E-LOC. More than half of the current cohort received single low-dose aspirin; however, recent European Society of Gastrointestinal Endoscopy guidelines on antithrombotics state that single low-dose aspirin as an antithrombotic does not significantly increase post-procedural bleeding rates [7]. However, we found two cases of post-ESD bleeding in patients taking single low-dose aspirin (11.8%; 2/17) in the historical cohort. Furthermore, this study aimed to examine the preventive effect of E-LOC for post-ESD bleeding and the successful closure rate of E-LOC. We therefore included patients on single antiplatelet therapy. In additional analysis, we compared the E-LOC group with the no-closure group using historical data. While there were no significant differences in patient and lesion characteristics, including type of antithrombotic, between the two groups, the post-ESD bleeding rate was significantly lower in the E-LOC group (0%) than in the no-closure group (20.0%;  $P = 0.001$ ).

Several endoscopic closure methods have been developed in recent years to close gastric mucosal defects, such as metal clips [8], endoloop with hemoclips [9, 10], over-the-scope clips

[11], endoscopic hand suturing [12], and an endoscopic suturing system [13]. Most reports described prevention of post-ESD bleeding [8, 11–13]; however, E-LOC showed a higher sustained closure rate (95.8%) at POD 2–3 compared with other methods [10, 12]. A recent systematic review and meta-analysis showed that 68.2% of post-ESD bleeding occurred within 48 hours [1], suggesting that sustained closure at POD 2–3 is a meaningful indicator of suppression of post-ESD bleeding.

Dual antiplatelet therapy and direct oral anticoagulants often cause bleeding after POD 7 [14]. We therefore evaluated the sustained closure rate at POD 10–11, which has not been performed in previous studies. Unfortunately, the small number of patients receiving these medications meant that we were unable to gather sufficient evidence to reveal the long-term efficacy of E-LOC.

We considered that the low sustained closure rate at POD 10–11 may have been attributable to the limited grasping power of the hemoclips themselves and/or the different sustainability at each circumference and location. Hemoclips may not be able to anchor the gastric mucosa deeply due to the thick wall, and the hemoclips may tend to drop off because the tissues around the defect can become indurated by POD 10–11. In fact, in most unsustained cases at POD 10–11, the hemoclips

**▶ Table 1** Baseline characteristics and outcomes of endoscopic submucosal dissection.

Characteristics	n = 48
<b>Patients</b>	
Age, mean (SD), years	77.2 (8.0)
<b>Sex, n (%)</b>	
▪ Male	39 (81.3)
▪ Female	9 (18.8)
<b>History</b>	
▪ Renal dialysis	4 (8.3)
Antithrombotic therapy	
▪ Single antiplatelet	35 (72.9)
▪ Aspirin	25 (52.1)
▪ Thienopyridine	8 (16.7)
▪ Cilostazol	2 (4.2)
▪ Dual antiplatelet	1 (2.1)
▪ Anticoagulation agent	9 (18.8)
▪ Warfarin	2 (4.2)
▪ Direct oral anticoagulants	7 (14.6)
▪ Antiplatelet and anticoagulation agent	3 (6.3)
▪ Continuous antithrombotic use	12 (25.0)
▪ Heparin replacement	0 (0.0)
<b>Lesions</b>	
Location, n (%)	
▪ Fornix	2 (4.2)
▪ Upper	5 (10.4)
▪ Middle	9 (18.8)
▪ Lower	9 (18.8)
▪ Angle	8 (16.7)
▪ Antrum	15 (31.3)
Circumference, n (%)	
▪ Greater curvature	16 (33.3)
▪ Lesser curvature	15 (31.3)
▪ Anterior wall	9 (18.8)
▪ Posterior wall	8 (16.7)
Macroscopic type, n (%) <sup>1</sup>	
▪ 0-IIa	18 (41.9)
▪ 0-IIb	4 (9.3)
▪ 0-IIc	21 (48.8)
ESD outcomes	
▪ En bloc resection, n (%)	48 (100)
▪ Curative resection, n (%)	46 (95.8)

**▶ Table 1** (Continuation)

Characteristics	n = 48
▪ Size of resected specimen, mean (SD), mm	31.6 (13.5)
▪ Size of the tumor, mean (SD), mm	16.3 (10.5)
▪ Procedure time, mean (SD), min	60.1 (54.4)
▪ Intraoperative perforation, n (%)	0 (0.0)
Histology, n (%)	
▪ Diagnosis	
▪ Adenoma	5 (10.4)
▪ Adenocarcinoma	43 (89.6)
▪ Tumor depth, n (%) <sup>1,2</sup>	
▪ Mucosa	40 (93.0)
▪ SM1 <sup>2</sup>	2 (4.7)
▪ SM2 <sup>2</sup>	1 (2.3)
Differentiation <sup>1</sup>	
▪ Differentiated	41 (95.3)
▪ Undifferentiated	1 (2.3)
▪ Mixed	1 (2.3)
Ulceration <sup>1</sup>	
▪ Present	7 (16.3)
▪ Absent	36 (83.7)
Lymphovascular infiltration <sup>1</sup>	
▪ Present	1 (2.3)
▪ Absent	42 (97.7)
ESD, endoscopic submucosal dissection; SM, submucosa.	
<sup>1</sup> Excluding 5 adenomas.	
<sup>2</sup> SM1 ≤ 500 μm; SM2 > 500 μm.	

dropped off from the anchored edges of the ulcer, although the O-ring band itself remained in situ (▶ Fig. 2). Additionally, a lower sustained closure rate in the angle and antrum may be explained by stronger gastrointestinal peristalsis in these locations. The study included only one patient with dual antiplatelet therapy and no patients with heparin bridge therapy. Thus, the finding of no post-ESD bleeding at POD 10–11 does not provide robust evidence of E-LOC efficacy. A further study including larger samples with these antithrombotics should be conducted. Histological analysis previously clarified that defect closure using endoscopic hand suturing can promote healing of post-ESD mucosal defects [15]. Thus, even in the event of lower long-lasting closure rates, defect closure itself may decrease the delayed bleeding rate because the ulcer area is diminished by the closure.

The mean procedure time of E-LOC (29.9 [SD 12.5] minutes) tended to be longer than that reported for endoloops, over-the-scope clips, and the endoscopic suturing system. This might have been influenced by the fact that more than half

► **Table 2** Outcomes of endoscopic ligation with O-ring closure.

Variables	n = 48
Post-ESD bleeding, n (%)	0 (0)
E-LOC procedure	
▪ Complete closure rate, n (%)	47 (97.9)
▪ Procedure time for closure, mean (SD), minutes	29.9 (12.5)
▪ Number of O-rings, mean (SD)	3.5 (1.0)
▪ Number of Additional clips, mean (SD)	0.9 (0.9)
▪ Adverse events related to E-LOC, n (%)	0 (0)
Defect closure on POD 2–3, n (%)	
▪ Sustained	46 (95.8)
▪ Partially sustained	2 (4.2)
▪ Unsustained	0 (0)
Defect closure on POD 10–11, n (%)	
▪ Sustained	16 (33.3)
▪ Partially sustained	5 (10.4)
▪ Unsustained	27 (56.3)
Sustained closure rate on POD 10–11, %	
Location	
▪ Fornix	50.0
▪ Upper	60.0
▪ Middle	22.2
▪ Lower	100
▪ Angle	0
▪ Antrum	6.7
Circumference	
▪ Greater curvature	62.5
▪ Lesser curvature	20.0
▪ Anterior wall	33.3
▪ Posterior wall	0
ESD, endoscopic submucosal dissection; E-LOC, endoscopic ligation with O-ring closure; POD, postoperative day.	

(66.7%; 4/6) of the endoscopists performing the procedure had limited experience of the E-LOC technique.

The strengths of E-LOC include its acceptable maneuverability for operators of any experience level, prevention of mucosal closure-associated submucosal pockets, and convenient availability using an inexpensive EVL device and nylon loop. Its limitations include the need for scope reinsertion for each O-ring used and the narrow endoscopic view due to the EVL hood.

This study has several limitations. First, it was a single-center, single-arm case series. Second, gastric neoplasms in the cardia or pyloric ring and those extending into more than half the circumference of the lumen were excluded because of con-

cerns of intraluminal stenosis after complete closure. A further trial with a larger number of patients is necessary to clarify the most suitable defect size, location, and circumference for E-LOC. Third, the study included a significant number of patients on single antiplatelet therapy.

In conclusion, E-LOC may be an effective method of closing mucosal defects after gastric ESD. However, the preventive effect of E-LOC on post-ESD bleeding should be further investigated in a prospective comparative study targeting patients at high risk of bleeding.

## Acknowledgments

We thank Angela Morben, DVM, ELS, and Susan Furness, PhD, from Edanz (<https://jp.edanz.com/ac>) for editing drafts of this manuscript.

## Competing interests

The authors declare that they have no conflict of interest.

## Clinical trial

Japan Medical Association Clinical Trial Registry (<http://www.jmacct.med.or.jp/>) | Registration number (trial ID): 000045906 | Type of study: prospective

## References

- [1] Suzuki H, Takizawa K, Hirasawa T et al. Short-term outcomes of multicenter prospective cohort study of gastric endoscopic resection: 'real-world evidence' in Japan. *Dig Endosc* 2019; 31: 30–39
- [2] Yamamoto Y, Kikuchi D, Nagami Y et al. Management of adverse events related to endoscopic resection of upper gastrointestinal neoplasms: review of the literature and recommendations from experts. *Dig Endosc* 2019; 31: (Suppl. 01): 4–20
- [3] Kantsevov SV, Bitner M, Mitrov AA et al. Endoscopic suturing closure of large mucosal defects after endoscopic submucosal dissection is technically feasible, fast, and eliminates the need for hospitalization (with videos). *Gastrointest Endosc* 2014; 79: 503–507
- [4] Akimoto T, Goto O, Sasaki M et al. Endoscopic hand suturing for mucosal defect closure after gastric endoscopic submucosal dissection may reduce the risk of postoperative bleeding in patients receiving antithrombotic therapy. *Dig Endosc* 2022; 34: 123–132
- [5] Nishiyama N, Kobara H, Kobayashi N et al. Novel endoscopic ligation with O-ring closure involving muscle layer of a gastric artificial defect. *Endoscopy* 2020; 52: E413–E414
- [6] Fujimoto K, Fujishiro M, Kato M et al. Guidelines for gastroenterological endoscopy in patients undergoing antithrombotic treatment. *Dig Endosc* 2014; 26: 1–14
- [7] Veitch AM, Vanbiervliet G, Gershlick AH et al. Endoscopy in patients on antiplatelet or anticoagulant therapy, including direct oral anticoagulants: British Society of Gastroenterology (BSG) and European Society of Gastrointestinal Endoscopy (ESGE) guidelines. *Endoscopy* 2016; 48: 385–402
- [8] Choi KD, Jung HY, Lee GH et al. Application of metal hemoclips for closure of endoscopic mucosal resection-induced ulcers of the stomach to prevent delayed bleeding. *Surg Endosc* 2008; 22: 1882–1886

- [9] Lee BI, Kim BW, Kim HK et al. Routine mucosal closure with a detachable snare and clips after endoscopic submucosal dissection for gastric epithelial neoplasms: a randomized controlled trial. *Gut Liver* 2011; 5: 454–459
- [10] Ego M, Abe S, Nonaka S et al. Endoscopic closure utilizing endoloop and endoclips after gastric endoscopic submucosal dissection for patients on antithrombotic therapy. *Dig Dis Sci* 2021; 66: 2336–2344
- [11] Maekagwa S, Nomura R, Murase T et al. Complete closure of artificial gastric ulcer after endoscopic submucosal dissection by combined use of a single over-the-scope clip and through-the-scope clips (with videos). *Surg Endosc* 2015; 29: 500–504
- [12] Goto O, Oyama T, Ono H et al. Endoscopic hand-suturing is feasible, safe, and may reduce bleeding risk after gastric endoscopic submucosal dissection: a multicenter pilot study (with video). *Gastrointest Endosc* 2020; 91: 1195–1202
- [13] Han S, Wani S, Edmundowicz SA et al. Feasibility of endoscopic suturing to prevent adverse events and hospitalization after endoscopic submucosal dissection. *Endosc Int Open* 2020; 8: E1212–E1217
- [14] Shiroma S, Hatta W, Tsuji Y et al. Timing of bleeding and thromboembolism associated with endoscopic submucosal dissection for gastric cancer in Japan. *J Gastroenterol Hepatol* 2021; 36: 2769–2777
- [15] Akimoto T, Goto O, Sasaki M et al. Endoscopic suturing promotes healing of mucosal defects after gastric endoscopic submucosal dissection: endoscopic and histologic analyses in in vivo porcine models (with video). *Gastrointest Endosc* 2020; 91: 1172–1182