

## Case Report

**Buschke-Ollendorff syndrome presenting with asymptomatic yellowish papules and leg length discrepancy: A case report****Wei-Kai Hung<sup>1,2</sup>, Meng-Han Shen<sup>2,3</sup>, Kuan-Yu Chen<sup>1,2</sup>, Wen-Hung Chung<sup>1,2,4</sup>, I-Hsin Shih<sup>1</sup>, Chia-Hsieh Chang<sup>5</sup>, Chin-Yi Yang<sup>1,2,6</sup>**<sup>1</sup>Department of Dermatology, Chang Gung Memorial Hospital, Linkou, Taoyuan, Taiwan;<sup>2</sup>College of Medicine, Chang Gung University, Taiwan;<sup>3</sup>Department of Dermatology, Chang Gung Memorial Hospital, Keelung, Taiwan;<sup>4</sup>Drug Hypersensitivity Clinical and Research Center, Chang Gung Memorial Hospital, Taiwan;<sup>5</sup>Department of Pediatric Orthopedics, Chang Gung Memorial Hospital, Linkou, Taiwan;<sup>6</sup>Department of Dermatology, New Taipei Municipal TuCheng Hospital, New Taipei City, Taiwan**Abstract**

Buschke-Ollendorff syndrome (BOS) is a rare, usually benign, autosomal dominant genetic disease affecting about 0.005% globally. BOS commonly manifests with asymptomatic connective tissue nevi, sometimes with sclerotic bone lesions like osteopoikilosis or melorheostosis. However, BOS may develop severe, symptomatic complications that require surgical intervention. Here we report a 9-year-8-month girl presenting with multiple nonpruritic, nonpainful skin plaques scattered around the trunk, buttocks, and bilateral legs. She had a history of right varus foot with inadequate plantar flexion. Upon visiting, obvious leg length discrepancy (LLD) was noted. Lesional biopsy revealed increased fibroblasts within dermal collagen bundles. Verhoeff-van Gieson stain revealed scattered foci of thickened elastic fibers between collagen fibers, especially in the mid-dermis. Radiographic examination of the lower extremities showed multiple small, round-to-oval shaped, radiopaque spots on the pelvic bones, femurs, tibiae, and both feet. Hyperostosis along the long axis with “dripping candle wax” appearance was characteristic of osteopoikilosis and melorheostosis. Genetic analysis showed heterozygous point mutation in exon 1 of LEMD3 gene (c.1323C>A, p.Y441X), confirming diagnosis of BOS. Sequential and epiphyseodesis were performed to correct LLD with a favorable outcome at 2-year follow-up. BOS associated with severe bone abnormalities is rare, but orthopedic surgical intervention can provide satisfactory outcome.

**Keywords:** Buschke-Ollendorff Syndrome, LEMD3, Melorheostosis, Connective Tissue Nevi, Osteopoikilosis**Introduction**

Buschke-Ollendorff syndrome (BOS) is a rare, usually benign disease, transmitted by autosomal dominant mode and manifested by variable cutaneous lesions (connective tissue nevi) and/or bony abnormalities (mostly osteopoikilosis) with an estimated incidence of 1 in 20,000<sup>1</sup>. In 2004, loss

of function mutations at the LEMD3 had been identified and associated with BOS<sup>2</sup>. Here, we report a case of BOS presenting with multiple asymptomatic yellowish papules on skin and bony abnormalities of lower limbs that required subsequent surgical intervention.

**Case presentation**

A 9-year-8-month girl with a body weight of 24 kg (3<sup>rd</sup> to 15<sup>th</sup> percentile) and a body height of 125 cm (3<sup>rd</sup> to 15<sup>th</sup> percentile) was brought to our dermatology department due to multiple nonpruritic, nonpainful, skin-colored to yellowish papules coalescing into plaques with symmetric distribution on the trunk, buttocks, and bilateral legs (Figure 1a-1c). She had been suffering from right varus foot with inadequate plantar flexion since toddlerhood. On examination, obvious

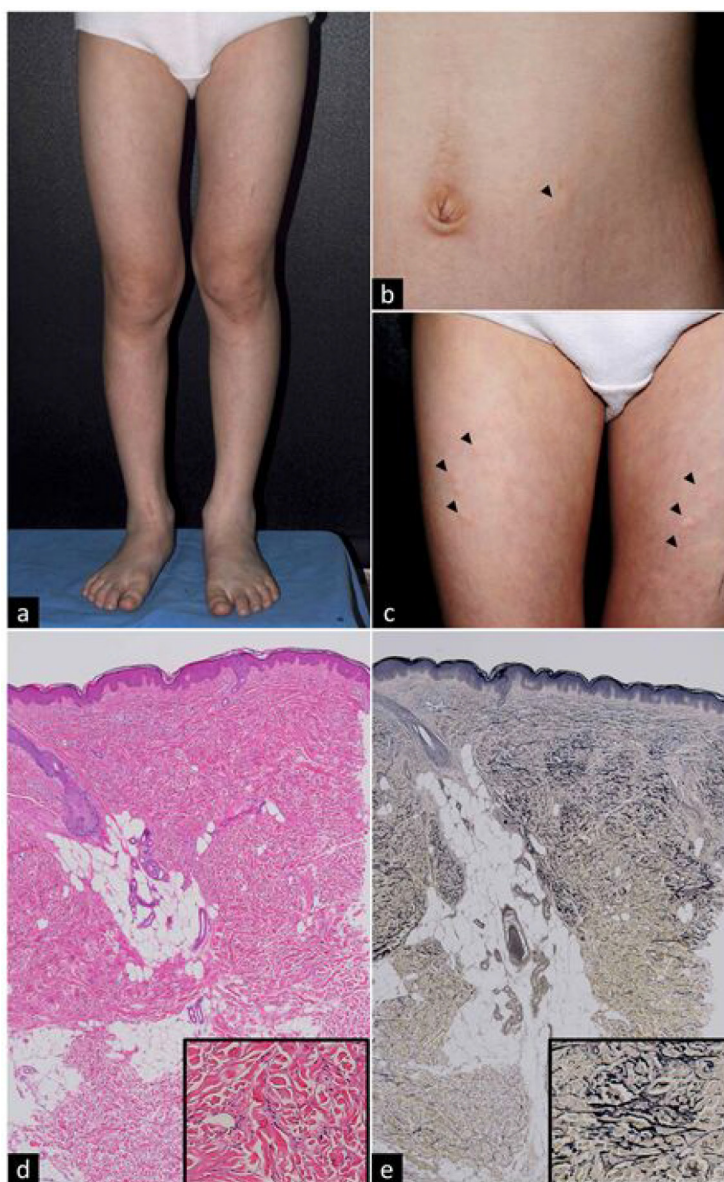The authors have no conflict of interest.

Corresponding author: Chin-Yi Yang, MD, Department of Dermatology, New Taipei Municipal TuCheng Hospital, No. 6, Sec. 2, Jincheng Rd., Tucheng Dist., New Taipei City 236, Taiwan  
E-mail: sophiachinyi@gmail.com

Edited by: G. Lyrakis

Accepted 2 January 2022





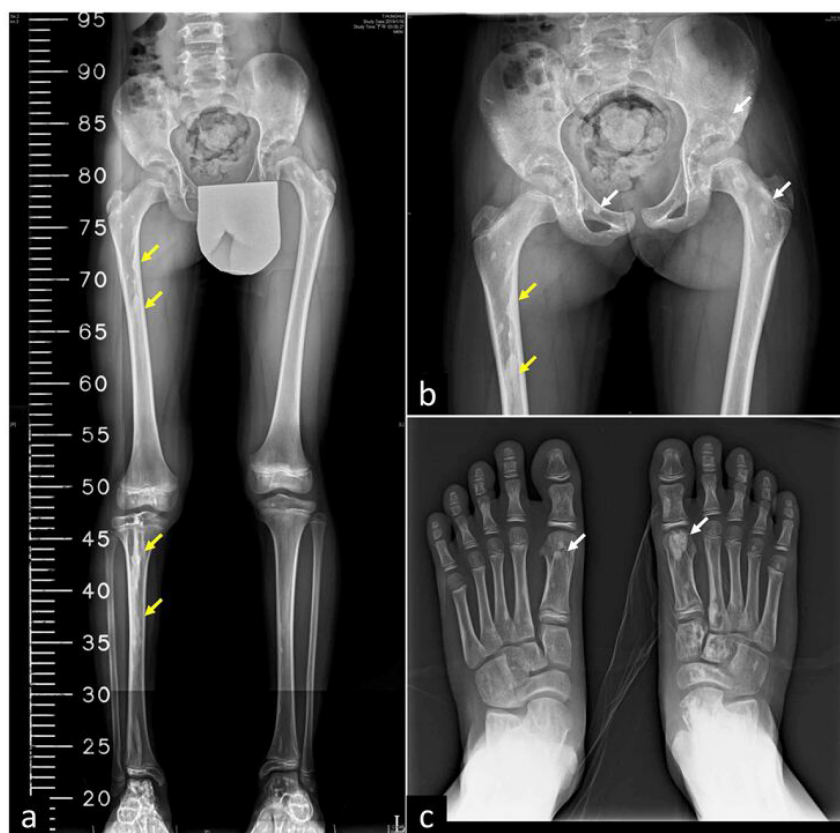
**Figure 1.** Clinical presentation and histopathologic examination. (a) Obvious leg length discrepancy with shorter right leg. (b) Skin-colored papules and plaques on the left abdomen. (c) Multiple skin-colored to yellowish papules coalescing to plaques symmetrically on the bilateral thighs. (d) Increased fibroblasts within dermal collagen bundles (hematoxylin and eosin staining, original magnification x100) (e) Foci of increased and thickened elastic fibers in the mid-dermis (Verhoeff-van Gieson stain, original magnification x100).

leg length discrepancy (LLD) (Figure 1a) was noticed. Lesional biopsy of the left thigh showed an increase in fibroblasts within dermal collagen bundles (Figure 1d). The Verhoeff-van Gieson stain revealed scattered foci of increased density of thickened elastic fibers between the collagen fibers, especially in the mid-dermis (Figure 1e).

Radiographic imaging of the lower extremities demonstrated multiple small, round-to-oval shaped, radiopaque lesions on the pelvic bones, femurs, tibiae, and bilateral feet (Figure 2a-2c). Hyperostosis along the long axis

of the right femur and tibia resembling “dripping candle wax” appearance was also found (Figure 2a, 2b). Those conditions were consistent with osteopoikilosis and melorheostosis. A bone biopsy of the right distal tibia metaphysis showed no malignancy.

Given the constellation of clinicopathologic and radiographic features, a diagnosis of BOS was highly suspected. Subsequent gene analysis confirmed the heterozygous point mutation in exon 1 of the LEMD3 gene on chromosome 12q14.3 (c.1323C>A, p.Y441X), which resulted



**Figure 2.** Radiographic examination. (a) Leg length discrepancy with shorter right tibia and classic “dripping candle wax” appearance consistent with melorheostosis at right femur and tibia (yellow arrow). (b) Multiple oval-shaped hyperdense opacities consistent with osteopoikilosis at the pelvis and bilateral femurs (white arrow) and melorheostosis (yellow arrow). (c) Osteopoikilosis at bilateral feet (white arrow).

in a premature stop codon. However, gene analysis was not conducted for her family members because no associated presentations were found among them. The patient received sequential epiphysiodesis at left proximal tibia and distal femur physes with hinged plates and subsequent rehabilitation programs for LLD and limited motion of the right ankle. Symptoms improved with no residual LLD at two-year follow-up.

The present study was approved by the Institutional Review Board (IRB number: 202101206B0). Written informed consent was exempted because individual information was de-identified.

## Discussion

BOS is a rare genetic disease. A thorough evaluation, including clinical manifestations, radiographic findings, histopathology, and most importantly, genetic analysis, is crucial to making the correct diagnosis. Though BOS generally follows a benign course, patients with melorheostosis may be symptomatic and develop severe complications. To the

best of our knowledge, the present study is the first case describing an association between BOS and LLD that needed subsequent surgical intervention.

The association between cutaneous lesions and bony abnormalities in BOS was first described by Buschke and Ollendorff in 1928 under the name of *dermatofibrosis lenticularis disseminata* and *osteopathia condensans disseminata*, respectively<sup>3</sup>. In the largest case series including 164 cases<sup>1</sup>, the mean age of disease presentation is 5.97 years, and the mean age of diagnosis is 23.94 years with a generally benign prognosis. The cutaneous lesions consist of different types of connective tissue nevi, which typically present as multiple asymptomatic, skin-colored to yellowish papules or nodules with or without coalescing into large plaques. The lesions usually appear in childhood and may increase in size and number during growth<sup>1</sup>. Histologically, dermal hamartomas characterized by imbalanced amount and distribution of normal components of the extracellular matrix such as collagen and elastin are found<sup>4</sup>. In our case, the skin specimen showed a connective tissue nevus with increased density of thickened elastic fibers.

Among the bony abnormalities in BOS, osteopoikilosis is the most common<sup>1</sup>. It is typically characterized by asymptomatic sclerotic “bony islands”, which appear as radiopaque spots on radiographs that occur in the epiphyses and metaphyses of long bones, wrist, foot, ankle, pelvis, and scapula. Melorheostosis is another rarely associated condition with a classic “dripping candle wax” appearance and caused by hyperostosis of the cortical bones<sup>5</sup>. Unlike osteopoikilosis, patients with melorheostosis may have pain, limb deformity, and limitation of movement<sup>5</sup>. Early fusion of the affected epiphyses causing significant LLD may occur, which is a severe complication that may require surgical intervention<sup>5</sup>. In our case, diffuse osteopoikilosis and melorheostosis with LLD and movement limitation were noted. Painful sensation on the right knee also developed later. Sequential temporary epiphysiodesis were performed, and the patient’s symptoms improved a lot without residual LLD.

However, none of the presentations, including connective tissue nevi, osteopoikilosis, and melorheostosis are the pathognomonic manifestations of BOS. To confirm the diagnosis of BOS, genetic analysis was conducted and a loss-of-function point mutation in the LEMD3 gene was detected. The same point mutation (c.1323C>A, p.Y441X) had been reported in an 8-year-old boy with BOS presenting only skin manifestations<sup>6</sup>. The LEMD3 gene encodes LEM domain-containing protein<sup>3</sup>, which is an integral protein of the inner nuclear membrane. The protein can antagonize both the bone morphogenic protein and the transforming growth factor-beta signaling pathway<sup>2</sup>. Loss-of-function mutation of the LEMD3 gene reduces the amount of this functional protein, leading to excessive extracellular products and abnormal bone morphogenesis<sup>5</sup>.

In conclusion, BOS associated with severe, symptomatic

melorheostosis is rare. Nevertheless, for patients with BOS complicated with symptomatic bone lesion like LLD, surgical intervention provides good outcomes.

## References

1. Pope V, Dupuis L, Kannu P, Mendoza-Londono R, Sajic D, So J, Yoon G, Lara-Corrales I. Buschke-Ollendorff syndrome: a novel case series and systematic review. *Br J Dermatol* 2016;174(4):723-9.
2. Hellemans J, Preobrazhenska O, Willaert A, Debeer P, Verdonk PC, Costa T, Janssens K, Menten B, Van Roy N, Vermeulen SJ, Savarirayan R, Van Hul W, Vanhoenacker F, Huylebroeck D, De Paepe A, Naeyaert JM, Vandesompele J, Speleman F, Verschueren K, Coucke PJ, Mortier GR. Loss-of-function mutations in LEMD3 result in osteopoikilosis, Buschke-Ollendorff syndrome and melorheostosis. *Nat Genet* 2004;36(11):1213-8.
3. Buschke A, Ollendorff H. Ein Fall von Dermatofibrosis lenticularis disseminata und Osteopathia condensans disseminata. *Dermatol Wochenschr* 1928;86:257.
4. McCuaig CC, Vera C, Kokta V, Marcoux D, Hatami A, Thuraisingam T, Marton D, Fortier-Riberdy G, Powell J. Connective tissue nevi in children: institutional experience and review. *J Am Acad Dermatol* 2012; 67(5):890-7.
5. Wordsworth P, Chan M. Melorheostosis and Osteopoikilosis: A Review of Clinical Features and Pathogenesis. *Calcif Tissue Int* 2019;104(5):530-543.
6. Mumm S, Wenkert D, Zhang X, McAlister WH, Mier RJ, Whyte MP. Deactivating germline mutations in LEMD3 cause osteopoikilosis and Buschke-Ollendorff syndrome, but not sporadic melorheostosis. *J Bone Miner Res* 2007;22(2):243-50.