

## Papillary thyroid carcinoma formation in a thyroglossal cyst. A case report

Ali MA<sup>1</sup>, Abussa A<sup>2</sup> and Hashmi H<sup>3</sup>

(1) Department of ENT, head and neck surgery, Tripoli medical centre, Tripoli, Libya.

(2) Department of medicine, African oncology institute, Sabratha, Libya

(3) Department General surgery, African oncology institute, Sabratha, Libya.

**Abstract:** Thyroglossal cyst rarely presents with carcinoma formation in the remnants of the thyroid gland. We report a 40 year old male with papillary thyroid carcinoma formation in a thyroglossal cyst. The patient underwent surgical intervention for the cyst. His pathology was positive for thyroid carcinoma and he underwent complete thyroidectomy with postoperative radioactive iodine treatment. His follow up revealed no evidence of recurrence.

**Key Words:** *Thyroglossal cyst, Papillary thyroid carcinoma, Radioactive iodine.*

### Introduction

The thyroglossal duct descends from the base of the tongue into the neck by the seventh week of the intrauterine life.

Thyroglossal duct cyst is the most common congenital anomaly that arises from the remnants of the thyroglossal duct and occurs in 7% of the adult population [1].

Most of reported cases (90%) of ectopic thyroid are found in the base of the tongue, and the rest are located in the anterior aspect of the neck superficial to the hyoid bone.

The incidence of papillary carcinoma arising in the thyroglossal duct cyst is < 1%, and most of these tumors arise from the ectopic thyroid tissue within the cyst.

Brentano was first to describe this condition in 1911, and since then about 215 cases have been reported in the literature [2].

Papillary carcinoma is the most common type being reported. The prognosis of papillary carcinoma arising in a thyroglossal cyst is similar to that of papillary carcinoma of the thyroid gland having cure rates in excess of 95% [2].

Preoperative evaluation of thyroglossal duct cyst includes a thorough head and neck examination, palpation of thyroid gland and thyroid function tests.

Thyroid scan should be done if there is a suspicion of an ectopic thyroid gland, it is also indicated if a mass is palpable within the cyst, thyroid gland or in the neck.

An ultrasound examination may aid in the diagnosis of malignancy by demonstrating a mural nodule, calcification or lymph node metastases [2]. The diagnosis is usually based on pathological examination of the cyst.

### Case Report

A 40 year old patient presented with multilocular central neck cyst of one year duration. Computed tomography showed multiloculated cystic lesion in the anterior neck that measured 8X6 cm with extension to the retrohyoid area and the thyroid cartilage (Figure 1). Fine needle aspiration showed blood and inflammatory cells. Neck ultrasound

showed the cyst, normal thyroid gland & no other abnormalities.

Patient underwent excision of the thyroglossal cyst (Sistrunk operation) with the central part of the hyoid bone. Intraoperative diagnosis of thyroglossal cyst was made. The patient had an uneventful postoperative course with no complications.

The Pathological Specimen showed Cystic lesion, fibrotic wall with intact Squamous epithelium. Examination of the intraluminal tissue showed some papillary formations and Psammoma bodies with the same cytomorphological changes consistent with papillary carcinoma.

Following the initial procedure and based on the histopathological picture, the patient underwent total thyroidectomy and has received two doses of radioactive iodine (100 mci and 128 mci.). The patient is doing well and stable on thyroid replacement therapy (Figure 2). The histopathological examination of the excised thyroid gland revealed normal thyroid tissue with no evidence of cancer formation.

### Discussion

The incidence of papillary carcinoma arising in the thyroglossal duct cyst is

< 1% and most of these tumors arise from the ectopic thyroid tissue within the cyst. Carcinoma arising in the thyroglossal duct cyst was first described by Brentano in 1911, and since then about 215 cases have been reported in the literature [2].

Papillary carcinoma is the most common type being reported. The prognosis of papillary carcinoma arising in a thyroglossal cyst is similar to that of papillary carcinoma of the thyroid gland having cure rates in excess of 95% [2].

Preoperative evaluation of thyroglossal duct cyst includes a thorough head and neck examination, palpation of thyroid gland and thyroid function tests. Thyroid scan is very helpful especially with the suspicion of an ectopic thyroid gland. It is also indicated if a mass is palpable within the cyst, thyroid gland or in the neck. An ultrasound

examination may aid in the diagnosis of malignancy by demonstrating a mural nodule, calcification or lymph node metastases [2].

The diagnosis is usually based on pathological examination of the cyst.

In most of the cases reviewed in the literature, the malignancy was not suspected before operation. The carcinoma was diagnosed only on pathological examination [3].

Management of this condition remains controversial; there is lack of consensus in the literature regarding its optimal management. It is due to lack of pre-operative diagnosis, rarity of the condition and possibility of associated thyroid malignancy [4].

Sistrunk procedure [5] is adequate if histology does not reveal extracystic extension, and thyroid suppression is recommended for all patients regardless the thyroid management [6 & 7].

Recurrence rates are lowest when total ablation of thyroid tissue is achieved therefore thyroidectomy followed by radioactive iodine ablation should be considered especially if tumor recurrence or metastases occur [8].

### Conclusion

Formation of thyroid carcinoma in a thyroglossal cyst is a rare entity, with controversial management options. Its behavior and prognosis are usually similar to that of the papillary thyroid cancer. Our case was no exception and his carcinoma was not discovered until the histological examination of the excised cyst.

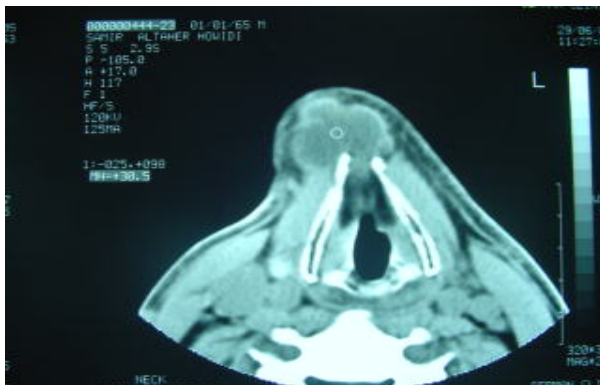


Figure1: Patient preoperative CT scan

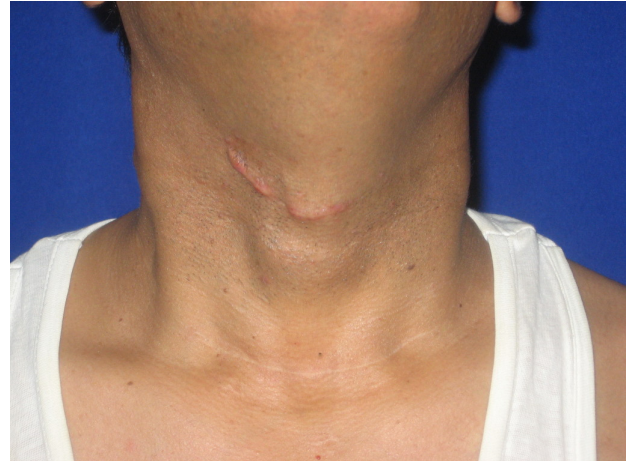

Figure 2: Patient Photo 6 months postoperative

### References

- 1- Ellis P, Van Nostrand AW. The applied anatomy of thyroglossal tract remnants. *Laryngoscope*. 1977; 87:765-70.
- 2- Devinder K. et al. Primary Papillary Carcinoma Arising in a Thyroglossal Duct Cyst. *Indian journal of medical & PAEDIATRIC ONCOLOGY* Vol. 27 No 2, 2006.
- 3- Mohammad G Al-Ajmi, Mohammad Azfar, Shahzad Avais. Metastatic Papillary Carcinoma in Thyroglossal Duct Remnant: A Case Report *Kuwait Medical Journal* 2003, 35 (4): 288-289
- 4- Nuttal FQ. Cystic metastases from papillary adenocarcinoma of the thyroid with comments concerning carcinoma associated with thyroglossal remnants. *Am J Surg* 1965;109:500-5.
- 5- Sistrunk, W. E.: Technique of Removal of Cysts and Sinuses of the Thyroglossal Duct. *Surg. Gynecol. Obstet.*, 46:109, 1928.
- 6- Kamal Kant, Girish Rajpal. Papillary carcinoma arising in a thyroglossal duct remnant. *Indian Journal of Surgery*, Vol. 65, No. 3, May-June, 2003, pp. 282-284.
- 7- Sistrunk WE : The surgical management of cysts of the thyroglossal tract. *Ann Surg*, 71:121-122, 1920.
- 8- McNicoll MP, Hawkins DB, England K, Penny R, Maceri DR. Papillary carcinoma arising in a thyroglossal duct cyst. *Otolaryngol Head Neck Surg* 1989;99:50-4.