

# First Iranian Experience of the Minimally Invasive Nuss Procedure for Pectus Excavatum Repair: A Case Series and Literature Review

Hamidreza Davari<sup>1</sup>, MD;  
Mohammad Bagher Rahim<sup>1</sup>, MD;  
Reza Ershadi<sup>1</sup>, MD;  
Shahab Rafieian<sup>1</sup>, MD;  
Parviz Mardani<sup>2</sup>, MD;  
Mohammad Rahim Vakili<sup>1</sup>, MD;  
Ahmad Shirinzadeh<sup>1</sup>, MD

<sup>1</sup>General Thoracic Surgeon, General Thoracic Surgery Ward, Tehran University of Medical Sciences, Tehran Iran;

<sup>2</sup>General Thoracic Surgeon, General Surgery Ward, Shiraz University of Medical Sciences, Shiraz, Iran

## Correspondence:

Hamidreza Davari MD;  
Department of General Thoracic Surgery, Valiasr Hospital, Imam Khomeini Hospital Complex, Keshavarz Blvd.,  
Post code 14197-33141, Tehran, Iran  
**Fax:** +98 21 66581604  
**Tel:** +98 21 61192368-68  
**Email:** h1h2hamid@yahoo.co.uk  
Received: 17 July 2017  
Revised: 26 August 2017  
Accepted: 27 August 2017

## What's Known

- Pectus excavatum (PE) is the most frequent congenital anomaly of the chest wall.
- The most frequently used techniques include Ravitch (costochondral resection) and Nuss (minimally invasive pectus repair of pectus excavatum [MIRPE]). Modified MIRPE can be learned easily and performed safely with few complications.
- There are only a few studies on the Ravitch technique in Iran and it is not clear whether the Nuss technique can be performed safely in our country.

## What's New

- The first experience of performing the modified Nuss procedure on 5 Iranian patients is reported.
- No mortality and few postoperative complications indicate that an experienced thoracoscopic surgeon can safely do the Nuss repair in Iranian patients with PE.

## Abstract

Pectus excavatum is the most common congenital deformity of the chest wall. The most frequently used techniques include Ravitch (costochondral resection) and Nuss (minimally invasive pectus repair of pectus excavatum [MIRPE]). The Nuss technique includes using temporary metallic bars without costochondral resection to correct the chest wall deformity. Modified MIRPE can be learned easily and performed safely with few complications. There are no reports of successful MIRPE in Iran, although the Ravitch technique is well known. In the present study, we report the first Iranian experience with the modified Nuss procedure in 5 patients with pectus excavatum (age range=13–48 y). All the patients suffered from low self-esteem, and one of them complained of low exercise capacity and occasional chest pain. With single-lung ventilation and sternal elevation, an introducer was entered into the right thoracic cavity and retrosternal tunneling was performed under thoracoscopic vision. The introducer was passed to the left thoracic cavity and exited on the left thoracic wall. A titanium plate bar was implanted and fixed with stabilizers. There were no cases of mortality, and all the patients were discharged in good conditions within 2 weeks. Postoperative complications consisted of 1 case of pneumothorax and 2 cases of fixed bar protrusion. The present case series indicated that a skilled thoracoscopic surgeon is able to do the Nuss procedure in Iranian patients with symmetrical pectus excavatum with few complications. However, mixed or redo cases require more expertise.

Please cite this article as: Davari H, Rahim MB, Ershadi R, Rafieian S, Mardani P, Vakili MR, Shirinzadeh A. First Iranian Experience of the Minimally Invasive Nuss Procedure for Pectus Excavatum Repair: A Case Series and Literature Review. *Iran J Med Sci*. 2018;43(5):554-559.

**Keywords** • Funnel chest • Minimally invasive surgical procedures

## Introduction

Pectus excavatum, the most frequent congenital deformity of the anterior chest wall, has an incidence of 1 in 300 to 400 births and is 4 to 6 times more frequent in men than in women.<sup>1-3</sup> Family history may be positive in up to 40% of the patients, although a direct genetic link has not been identified.<sup>4</sup> Pectus excavatum may be associated with scoliosis and connective tissue disorders such as Marfan syndrome, Ehlers–Danlos syndrome, and Noonan syndrome.<sup>4</sup>

The initial attempt to treat patients with pectus excavatum was unsuccessful until the mid-20th century.<sup>1</sup> The new era in pectus repair began in 1949, when Ravitch reported details of costochondral resection and sternal osteotomy in the annals of surgery.<sup>1</sup> In 1998, Nuss introduced minimally invasive repair for pectus excavatum (MIRPE).<sup>1</sup> This technique, which includes the temporary implantation of retrosternal bars without costochondral resection, has gained popularity throughout the last 2 decades.<sup>1,2,4,5</sup> Modified MIRPE can be learned easily and performed safely with few complications. Nevertheless, thus far there has been no report of MIRPE in Iran. In this case series, we report the first Iranian experience with the modified Nuss procedure to suggest its feasibility in Iranian patients.

**Case Presentation**

Between September 2016 and September 2017, five patients (4 men and 1 woman) at an age range of 13 to 46 years underwent pectus deformity repair via the modified Nuss procedure in our center (table 1). All the patients were informed about the Nuss technique and the complications and gave written informed consent for the use of their data in the present study.

The major indications for pectus repair comprised moderate-to-severe deformity, poor body image, and psychosocial maladjustment (figures 1a, b, and c) (table 1). Preoperative investigations were comprised of physical examination, chest X-ray (posteroanterior and lateral), pulmonary function test, and chest computed tomography scan (figures 2a and b). All the patients underwent transthoracic echocardiography and the pulmonary function test. Two patients underwent the cardiopulmonary exercise test. One patient had kyphoscoliosis and had undergone spinal surgery 2 years earlier.

For surgery, after the induction of anesthesia and use of single-lung ventilation, the patient was positioned supine with both arms abducted approximately 70°. The deepest depression

point and hinge points (the entry and exit points of the bar) were marked after palpating the chest wall.<sup>1,5</sup> The right and left lateral incision sites were between the anterior and mid-axillary lines on the same horizontal plane as the deepest depression point, exactly in accordance with Nuss' instructions.<sup>1</sup> The chest was measured from the right to the left mid-axillary line, and a pectus bar was selected based on this measurement minus 2.5 cm.<sup>1</sup>

A 10-mm port trocar was used at the mid-axillary line, approximately 2 interspaces below the right lateral skin incision. A 30° scope was utilized with forced sternal elevation as described by Chong et al. and others (figure 3a).<sup>1,4-6</sup> Before the insertion of the introducer, sub-pectoral tunnels were prepared for entrance at the hinge point in the right pleural cavity and the exit point on the left pleural cavity using the Brazilian technique and others.<sup>1,2,4-7</sup> Retrosternal tunneling was made under thoracoscopic vision. The

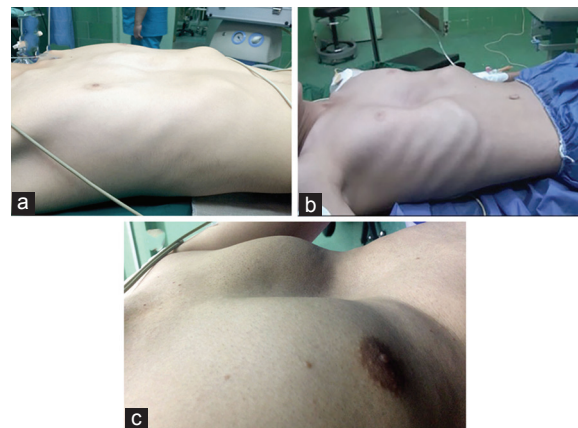


Figure 1: Shows preoperative pictures of a) Case 1, b) Case 2, and c) Case 4.

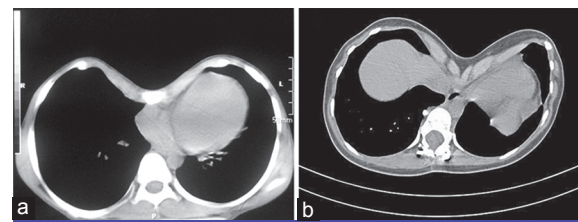
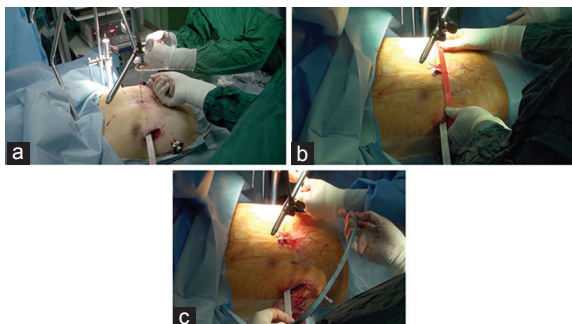


Figure 2: Shows preoperative axial computed tomography scan of a) Case 2, and b) Case 5.

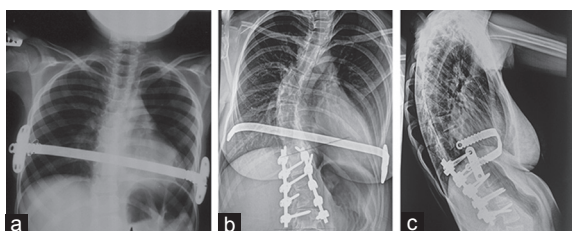
Case	Age (y)	Chief complaint	Haller index	Hospital stay (d)	Follow-up duration (Mon)	Complications
1	15	Poor body image	4	14	12	Fixed bar protrusion
2	13	low exercise capacity and chest pain	5.2	14	10	Pneumothorax
3	46	Poor body image	3.38	10	9	
4	25	Poor body image	4.2	10	9	Fixed bar protrusion
5	14	Poor body image	6.46	10	8	

surgeon inserted his finger through the left hinge point into the left pleural cavity and guided the tip of the introducer to exit on the left thoracic wall.<sup>7</sup> A titanium plate bar was implanted after pre-adjustment bending by using template molding (figures 3b and c). It was fixed with wire on both lateral sides with 1 or 2 stabilizers and also with nonabsorbable suture in 2 points as near as possible to the hinge points (multiple-point fixation) (figures 4a, b, c, and d).<sup>1-4</sup> At the end of the procedure, a 28-F chest tube was inserted through the 10-mm trocar incision on the right side and connected to an underwater seal for 2 days. Pain was managed with morphine and paracetamol using a PCA pump, followed by oral analgesic and anti-inflammatory pills. The patients were discharged within 10 days to 2 weeks after the operation with oral analgesics continuing for 2 subsequent weeks.

The Haller index was 3.38 to 6.46 in the patients (table 1). Echocardiography and the cardiopulmonary exercise test were reported normal in all the cases. The pulmonary function test was normal, except in Case 1, who exhibited an obstructive pattern. The duration of hospital stay was between 10 and 14 days. There was no case of mortality. One of the patients, who was thin, developed pneumothorax and needed reinsertion of the chest tube for 3 more days. There was no serious complication during the follow-up (figure 1c). There was no evidence of bar rotation, skin ulceration, or allergic reaction.



**Figure 3:** Shows modified Nuss technique of a) Forced sternal elevation of Case 3, b) Template molding of Case 4, and c) Bended titanium bar of Case 4.



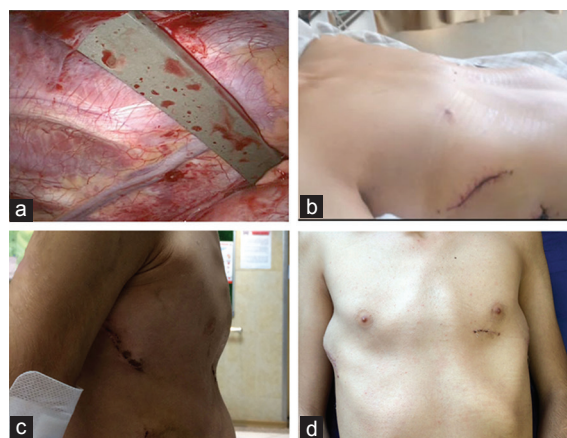
**Figure 4:** Shows postoperative imaging of a) Chest X-ray of Case 2: sternal bar with 2 stabilizers, b) Chest X-ray of Case 5: sternal bar with 1 stabilizer and previous spine surgery, and c) Lateral chest X-ray of Case 5.

Pain was completely subsided within 1 month after discharge. All 5 patients were satisfied, although fixed bar protrusion was observed in 2 patients (figures 5a, b, c, and d) (table 1).

## Discussion

Pectus excavatum may be present at birth, but it is most frequently recognized during early childhood.<sup>4</sup> The severity of the deformity varies among patients, with a marked increase in depression during adolescence.<sup>4</sup> The majority of patients with this deformity complain of poor cosmetic appearance, unsatisfactory body image, and low self-esteem.<sup>1,2</sup> Some patients complain of exercise intolerance, shortness of breath, and weakness because of restriction in the chest wall and impaired cardiorespiratory function.<sup>1,4</sup>

There was no surgical treatment for such patients until the 20th century, when surgeons started to develop techniques to repair pectus excavatum.<sup>1</sup> Before World War II, several attempts were made, including partial cartilage resection, sternal osteotomy, and external traction. The results were, however, unsatisfactory. The modern era of pectus repair began when Ravitch published his first paper in 1949.<sup>1</sup> Welch popularized the Ravitch technique in 1958.<sup>1</sup> They both recommended complete resection of the abnormal costal cartilages and complete mobilization of the sternum without external traction. The issue of a substernal bar for sternal support was described by Adkins and Blades in 1961.<sup>1</sup> Robicsek made different modifications to the open procedure in the 1960s, including the use of sternal turnover, stabilizing the mesh without a substernal bar, and less partial cartilage resection.<sup>8</sup> There were



**Figure 5:** Shows thoracoscopic view of the bar and the postoperative picture. a) Thoracoscopic view of the titanium retrosternal bar of Case 1, b) Postoperative picture of Case 1, c) Postoperative picture of Case 2, and d) Bilateral axillary protrusion of the fixed bar with the stabilizers of Case 1.



also synthetic implants, and cosmetic surgery became available for asymptomatic pectus deformity in the 1960s.<sup>9</sup>

Ravitch advised surgery in infants and preschool children.<sup>10</sup> He performed wide resection of the abnormal costal cartilage and sternal isolation, which resulted in a very rigid anterior chest wall. In 1990, Martinez et al.<sup>11</sup> published an experimental paper in rabbits and showed that the costal cartilage had a major role in chest-wall growth. In 1996, Haller et al.<sup>12</sup> published another paper and criticized pectus repair for being too extensive and too early. Extensive resection of the cartilage leads to poor compliance of the chest, and permanent cartilage loss is associated with restrictive lung disease, chest fixation at the resected sites, calcification, osteophytic growth and in some, acquired asphyxiating chondroplasty.<sup>1,3,10,13</sup> Other complications of the Ravitch repair include anterior scar, and if the healing process is not resumed, there will be disastrous instability complications such as osteonecrosis, pseudarthrosis, nonunion, and sternal floating.<sup>3,13</sup>

In the mid-1980s, Donald Nuss, a pediatric surgeon, was dissatisfied with the Ravitch technique and innovated a new technique in 1987. He performed the first MIRPE on a 4-year-old boy.<sup>10</sup> An alternative technique in pectus surgery was introduced when he presented his 10 years of experience in 1997 at the American Pediatric Surgery Association Congress and published his work in 1998.<sup>10</sup> As other centers started to perform the MIRPE procedure, several key innovations developed such as addition of thoracoscopy, forced sternal elevation, improved bar stabilization by pericostal suturing or using stabilizers, nonallergic titanium bars, preoperative antibiotic therapy, and better postoperative pain management.<sup>1-4,10,13,14</sup>

Nowadays, the modified Ravitch procedure is still a common pectus excavatum treatment after 6 decades.<sup>9</sup> The Robicsek technique is still used, and silicone and polyethylene implants are applied cosmetically to fix the deformity.<sup>9,15</sup> The Nuss procedure has gained popularity during the past 2 decades.<sup>1,2,4,5</sup> Considering the literature and propaganda, selecting the most appropriate treatment may be a challenge for patients and physicians.<sup>9</sup>

A small number of studies have compared the Ravitch and Nuss procedures. Johnson et al.<sup>9</sup> published a systematic review in 2014 and reported that the outcome ratings between the Nuss and Ravitch procedures were similar. Kanagaratnam et al.<sup>16</sup> published a systematic review and meta-analysis to compare the procedures in 2016 and reported no significant

difference in overall complications between the groups in pediatric populations. In the adult subgroup, the Ravitch group had significantly fewer complications. The debate on the outcome difference in adults was related to the current policy of pectus repair centers. Kanagaratnam and colleagues<sup>16</sup> showed that most centers did pectus repair by using only one of the techniques and some others reported their experiences with the Nuss procedure for the first time while their main policy was pectus repair using the Ravitch technique. Early satisfaction was reported in both procedures, although long-term satisfaction was not clear. For specific complications, there was no difference between the 2 groups in terms of pneumothorax, hemothorax, wound infection, reoperation, or pneumonia. Their review largely correlated with the only previous meta-analysis performed by Nasr and colleagues.<sup>17</sup> In our experience, after having performed the Ravitch technique for many years, we switched to the Nuss procedure as the first treatment of choice, although we still consider the Ravitch procedure in patients with calcified fixed cartilage or sternum, overlapping redundant cartilage, or mixed carinatum and pectus deformity as well as in cases of failed Ravitch revision or hybrid operations as recommended by Jaroszewski.<sup>13</sup>

The Nuss procedure has some clear advantages. The duration of the operation is shorter than the Ravitch procedure and it is associated with less blood loss due to the minimally invasive nature of the procedure.<sup>16</sup> Although the Ravitch procedure is associated with less pain at the early stages, it is argued by many authors that there is no significant difference in pain between the 2 procedures.<sup>14</sup> On the contrary, the evaluation and management of postoperative pain and patient satisfaction are not standardized; therefore, it is impossible to compare these issues between the 2 procedures.<sup>16</sup>

For decades, the function of the lung has been a debate issue.<sup>18</sup> The results of pulmonary function tests may be normal or show a restrictive or obstructive pattern with some values above average.<sup>1,18</sup> Kelly et al.<sup>18</sup> reported that the bell curves of FVC, FEV1, and FEF 25–75 were shifted to significantly lower values in pectus excavatum. The curve was shifted to higher values after surgery by approximately 1 standard deviation. Oculo-electronic plethysmography (which was developed recently) clearly shows the effects of pectus repair on the improvement in the pulmonary function. Maagaard and Heiberg<sup>19</sup> concluded that after pectus repair, through the mechanism of increasing the anterior-posterior thoracic dimensions and relief of compression

on the cardiac chambers, the filling of the heart is facilitated and exercise capacity is augmented.

Our series is the first Iranian experience with the Nuss procedure performed on patients in different age ranges from adolescence to young and middle-aged. The literature review clearly shows that the optimal age for repair has changed from preschool age to prepuberty and adolescence.<sup>10</sup> Park et al.<sup>20</sup> reported that the Nuss procedure was safe in children aged between 4 and 6 years and recommended surgery in young children. Robicsek<sup>21</sup> questioned the safety of the Nuss procedure in young children and maintained that the transfixion of the anterior chest wall with rigid metal bars in children might indeed cause the same damage as radical cartilage resection in the Ravitch technique through restricting the growth and expansion of the thoracic cage. There are reports of successful operations on pediatric patients aged 6 to 19 years, as well as adults aged 20 to late fifty.<sup>9,10,13,22</sup>

In our country, Iran, most parents do not accept pectus repair in the pediatric age for cosmetic reasons and/or cardiopulmonary improvement. We frequently encounter prepubertal patients with complaints of poor body image, low self-esteem, and occasional physical intolerance. Their parents are reluctant or refuse correction. On the other hand, Nuss reported that some patients are symptomatic in the fourth and fifth decades of life; therefore, it is reasonable to address pectus repair in the prepubertal age and young adults before developing chest-wall rigidity.<sup>1</sup>

We used this new technique with all the modifications, including forced sternal elevation, thoracoscopic substernal tunneling, pericostal suturing, and use of stabilizers to prevent bar displacement. No bar displacement was observed in our series, but 2 patients complained of protrusion at the site of the stabilizers. Jaroszewski<sup>13</sup> did not use stabilizers and reported that the use of stabilizers was associated with popping out at the site of stabilizers, more pain, limitation in lateral mobility, and stacked effect with using multiple bars. She used shorter bars and fixed the bars with fiber wires at multiple points. In our experience, protrusion at the site of bar fixation was partly related to the length of the bar and the degree of lateral bending plus the bulk of the stabilizers. Pilegaard<sup>2</sup> recommended short bars and the use of stabilizers at 1 site, which is suitable for adolescents and not younger patients. Nuss mentioned that the bar should not be too tight where it is laterally fixed.<sup>1,10</sup> The number of bars and stabilizers and proper placement of the bar (i.e. simple bending, crossover, oblique, or

seagull-shaped) are different, and experienced surgeons apply bending or position placement techniques for Nuss for better correction and stabilization of severe or mixed type chest-wall deformities.<sup>1,2,4,5,13</sup>

The present study has some limitations, first and foremost among which is its small sample size. Another drawback of note is that we focused solely on pectus excavatum and failed to include mixed deformities. That our follow-up period was only 1 year is another weakness. Further studies are required to introduce the advantages and disadvantages of this technique and the necessary modifications.

## Conclusion

The results of the present study demonstrated that the Nuss procedure was safe and effective in pediatric and adult Iranian patients.

**Conflict of Interest:** None declared.

## References

1. Nuss D, Obermeyer RJ, Kelly RE. Nuss bar procedure: past, present and future. *Ann Cardiothorac Surg.* 2016;5:422-33. doi: 10.21037/acs.2016.08.05. PubMed PMID: 27747175; PubMed Central PMCID: PMC5056934.
2. Pilegaard HK. Single centre experience on short bar technique for pectus excavatum. *Ann Cardiothorac Surg.* 2016;5:450-5. doi: 10.21037/acs.2016.09.05. PubMed PMID: 27747178; PubMed Central PMCID: PMC5056931.
3. Abid I, Ewais MM, Marranca J, Jaroszewski DE. Pectus Excavatum: A Review of Diagnosis and Current Treatment Options. *J Am Osteopath Assoc.* 2017;117:106-13. doi: 10.7556/jaoa.2017.021. PubMed PMID: 28134952.
4. Jaroszewski D, Notrica D, McMahon L, Steidley DE, Deschamps C. Current management of pectus excavatum: a review and update of therapy and treatment recommendations. *J Am Board Fam Med.* 2010;23:230-9. doi: 10.3122/jabfm.2010.02.090234. PubMed PMID: 20207934.
5. Park HJ, Jeong JY, Jo WM, Shin JS, Lee IS, Kim KT, et al. Minimally invasive repair of pectus excavatum: a novel morphology-tailored, patient-specific approach. *J Thorac Cardiovasc Surg.* 2010;139:379-86. doi: 10.1016/j.jtcvs.2009.09.003. PubMed PMID: 20106400.

6. Chong CF, Nor S, Bhaskaran V, Latif ZA. Early experience of minimally invasive repair of pectus excavatum in RIPAS Hospital. *Brunei Int Med J.* 2012;8:315-322.
7. Tedde ML, de Campos JR, Wihlm JM, Jatene FB. The Nuss procedure made safer: an effective and simple sternal elevation manoeuvre. *Eur J Cardiothorac Surg.* 2012;42:890-1. doi: 10.1093/ejcts/ezs442. PubMed PMID: 22833539.
8. Robicsek F, Daugherty HK, Mullen DC, Harbold NB, Jr., Hall DG, Jackson RD, et al. Technical considerations in the surgical management of pectus excavatum and carinatum. *Ann Thorac Surg.* 1974;18:549-64. PubMed PMID: 4611362.
9. Johnson WR, Fedor D, Singhal S. Systematic review of surgical treatment techniques for adult and pediatric patients with pectus excavatum. *J Cardiothorac Surg.* 2014;9:25. doi: 10.1186/1749-8090-9-25. PubMed PMID: 24506826; PubMed Central PMCID: PMC3922335.
10. Nuss D, Obermeyer RJ, Kelly RE, Jr. Pectus excavatum from a pediatric surgeon's perspective. *Ann Cardiothorac Surg.* 2016;5:493-500. doi: 10.21037/acs.2016.06.04. PubMed PMID: 27747183; PubMed Central PMCID: PMC5056929.
11. Martinez D, Juame J, Stein T, Peña A. The effect of costal cartilage resection on chest wall development. *Pediatr Surg Int.* 1990;5:170-3. doi: 10.1007/BF00179655.
12. Haller JA, Jr., Colombani PM, Humphries CT, Azizkhan RG, Loughlin GM. Chest wall constriction after too extensive and too early operations for pectus excavatum. *Ann Thorac Surg.* 1996;61:1618-24. doi: 10.1016/0003-4975(96)00179-8. PubMed PMID: 8651758.
13. Jaroszewski DE. An overview of adult pectus surgery and latest techniques with a Q&A session with adult pectus surgery [webinar]. 2015. Retrieved from: <https://www.pectus.com/learn/webinars/item/webinar-from-jan-28-2015>
14. Jaroszewski DE, Johnson K, McMahon L, Notrica D. Sternal elevation before passing bars: a technique for improving visualization and facilitating minimally invasive pectus excavatum repair in adult patients. *J Thorac Cardiovasc Surg.* 2014;147:1093-5. doi: 10.1016/j.jtcvs.2013.09.049. PubMed PMID: 24237886.
15. Hamaji M, Hiraoka K, Jaroszewski DE, Deschamps C. Modified Robicsek procedure for pectus excavatum in adult patients. *Interact Cardiovasc Thorac Surg.* 2014;18:611-4. doi: 10.1093/icvts/ivt555. PubMed PMID: 24457817.
16. Kanagaratnam A, Phan S, Tchantchaleishvili V, Phan K. Ravitch versus Nuss procedure for pectus excavatum: systematic review and meta-analysis. *Ann Cardiothorac Surg.* 2016;5:409-21. doi: 10.21037/acs.2016.08.06. PubMed PMID: 27747174; PubMed Central PMCID: PMC5056933.
17. Nasr A, Fecteau A, Wales PW. Comparison of the Nuss and the Ravitch procedure for pectus excavatum repair: a meta-analysis. *J Pediatr Surg.* 2010;45:880-6. doi: 10.1016/j.jpedsurg.2010.02.012. PubMed PMID: 20438918.
18. Kelly RE, Jr., Obermeyer RJ, Nuss D. Diminished pulmonary function in pectus excavatum: from denying the problem to finding the mechanism. *Ann Cardiothorac Surg.* 2016;5:466-75. doi: 10.21037/acs.2016.09.09. PubMed PMID: 27747180; PubMed Central PMCID: PMC5056935.
19. Maagaard M, Heiberg J. Improved cardiac function and exercise capacity following correction of pectus excavatum: a review of current literature. *Ann Cardiothorac Surg.* 2016;5:485-92. doi: 10.21037/acs.2016.09.03. PubMed PMID: 27747182; PubMed Central PMCID: PMC5056930.
20. Park HJ, Sung SW, Park JK, Kim JJ, Jeon HW, Wang YP. How early can we repair pectus excavatum: the earlier the better? *Eur J Cardiothorac Surg.* 2012;42:667-72. doi: 10.1093/ejcts/ezs130. PubMed PMID: 22518034.
21. Robicsek F. Minimally invasive or maximally intrusive. *Eur J Cardiothorac Surg.* 2012;42:672-3. doi: 10.1093/ejcts/ezs210. PubMed PMID: 22766961.
22. Johnson KN, Jaroszewski DE, Ewais M, Lackey JJ, McMahon L, Notrica DM. Hybrid Technique for Repair of Recurrent Pectus Excavatum After Failed Open Repair. *Ann Thorac Surg.* 2015;99:1936-43. doi: 10.1016/j.athoracsur.2015.02.078. PubMed PMID: 25921256.