

Clinical results of cervical laminectomy and fusion for the treatment of cervical spondylotic myelopathy in 58 consecutive patients

Victor Chang¹, Daniel C. Lu^{1,2}, Haydn Hoffman¹, Colin Buchanan¹, Langston T. Holly^{1,2}

¹Departments of Neurosurgery, ²Orthopaedics, David Geffen UCLA School of Medicine, Los Angeles, USA

E-mail: Victor Chang - vwchang@mednet.ucla.edu; Daniel C. Lu - dclu@mednet.ucla.edu; Haydn Hoffman - [h hoffman@mednet.ucla.edu](mailto:hoffman@mednet.ucla.edu);
Colin Buchanan - colin.buchanan81@gmail.com; *Langston T. Holly - lholly@mednet.ucla.edu

*Corresponding author

Received: 05 February 14 Accepted: 18 February 14 Published: 16 April 14

This article may be cited as:

Chang V, Lu DC, Hoffman H, Buchanan C, Holly LT. Clinical results of cervical laminectomy and fusion for the treatment of cervical spondylotic myelopathy in 58 consecutive patients. *Surg Neurol Int* 2014;5:S133-7.

Available FREE in open access from: <http://www.surgicalneurologyint.com/text.asp?2014/5/4/133/130670>

Copyright: © 2014 Chang V. This is an open-access article distributed under the terms of the Creative Commons Attribution License, which permits unrestricted use, distribution, and reproduction in any medium, provided the original author and source are credited.

Abstract

Background: There are a number of surgical treatment options for cervical spondylotic myelopathy (CSM). In this study, the authors present their clinical results with cervical laminectomy and fusion for the treatment of patients with CSM.

Methods: This retrospective study included 58 consecutive patients who underwent cervical laminectomy and fusion for CSM. There were 38 males and 20 females, with a mean age of 64 (range 42-92) years. The Japanese orthopedic association score (mJOA) scale was used as the functional outcome measurement. Both the absolute increase in mJOA and the neurological recovery rate of mJOA were analyzed. The mean clinical follow-up was 17 months (range 5-52 months).

Results: There was a statistically significant improvement between mean preoperative (13.2, range 7-17) and postoperative (16.1, range 11-18) mJOA scores following surgery. The average improvement in mJOA score was 2.9 points. The mean neurological recovery rate was 56.6%. Overall 85.5% of patients improved with surgery ($n = 51$) and the remaining 14.5% of patients had no change in their mJOA score after surgery ($n = 7$). Fusion was documented in all 58 patients. There was a 10.3% overall complication rate ($n = 6$). The most common complications were C5 nerve palsies which occurred in 6.9% of the cohort ($n = 4$); all completely resolved.

Conclusion: Cervical laminectomy and fusion is a safe and efficacious procedure for the treatment of CSM. The clinical outcomes appear to be quite reproducible, and this technique is an important part of a spine surgeon's armamentarium.

Key Words: Cervical, fusion, laminectomy, myelopathy

Access this article online

Website:

www.surgicalneurologyint.com

DOI:

10.4103/2152-7806.130670

Quick Response Code:



INTRODUCTION

Cervical spondylotic myelopathy (CSM) is a degenerative disorder of the cervical spine that can potentially cause devastating and irreversible impairment of neurological

function.^[1,13,19,30] Among the adult population, CSM is a major source of disability and is the leading cause of acquired spinal cord dysfunction.^[29] Given the progressive nature of CSM, many authors advocate surgical treatment of patients diagnosed with this condition.^[5,6,24]

The most optimal surgical technique for CSM is frequently debated among surgeons, and is a source of controversy in our field. As such, investigations into the efficacy of surgical approaches for CSM are a worthwhile undertaking. Surgical treatment options for CSM include: Anterior cervical discectomy or corpectomy and fusion, laminoplasty, laminectomy, and cervical laminectomy with fusion. All four methods have been shown to be efficacious in the treatment of CSM,^[2,10,11,16,21-23] and each have their merits, indications and relative contraindications. In this study, the authors detail their clinical results with cervical laminectomy and fusion in the surgical management of CSM patients.

MATERIALS AND METHODS

In this retrospective analysis, 58 patients underwent cervical laminectomy and fusion by authors DL and LTH (2008-2012) for CSM attributed to spinal cord compression at the C2 level and below. A summary of patient demographics is illustrated in Table 1. Inclusion criteria included: Clinical and radiographic findings consistent with the diagnosis of CSM, age greater than 18 years, and a posterior approach alone without a concomitant anterior spinal procedure. Exclusion criteria included: acute deterioration related to a central cord syndrome or trauma, those with cervicomedullary compression associated with rheumatoid arthritis or other degenerative pathology, and patients with underlying neurological disorders (e.g. multiple sclerosis, Parkinson’s disease, normal pressure hydrocephalus). There were 38 males and 20 female patients. The mean patient age was 64 (range 42-92) years. The mean follow-up for this study was 17 months (range 5-52 months). All the patients were followed for at least 6 months, except for one patient who died 5 months postoperatively due to unrelated causes. The Office for the Protection of Research Subjects at our Institution approved the protocol for this study.

Clinical presentation

A total of 44 patients had multiple complaints of 3 months to 2 years duration at the time of presentation (76%). Gait disturbance, encountered in 40 patients (69%), was the most common presenting complaint [Figure 1]. Other complaints included: Loss of hand dexterity with difficulty in writing, buttoning buttons, and/or other fine finger movements (33 patients), upper extremity

sensory disturbances or paresthesias (27 patients), lower extremity paresthesias (6 patients), paresthesias in both the upper and lower extremities (6 patients), bladder incontinence (1 patient), and upper extremity pain (2 patients).

Hyperreflexia, the most common preoperative neurological sign, was encountered in 29 patients (50%); this was followed in descending order by Hoffman’s signs (22 patients), positive Babinski’s signs (15 patients), and lower extremity clonus (14 patients). Of interest, 17 patients had no evidence of long tract signs.

Radiographical evaluation

Preoperatively, cervical sagittal alignment was assessed utilizing lateral standing radiographs and documented; straightening of the cervical lordosis (27 patients) (47%), a lordotic cervical spine (17 patients), and kyphosis (14 patients). Notably, preoperative T2 weighted MR studies documented hyperintense signal in the spinal cords of 39 patients (57%).

Functional assessment

The modified Japanese orthopedic association score (mJOA) was used as the primary clinical outcome measure.^[3] Additionally, the neurological recovery rate was calculated utilizing the Hirabayashi *et al.*^[15] method where:

$$\text{Recovery rate} = \frac{\text{Postoperative mJOA} - \text{Preoperative mJOA}}{18 - \text{Preoperative mJOA}} \times 100$$

Statistical analysis for this study involved using the unpaired *t*-test to compare preoperative to postoperative mJOA. A sampling error of less than 5% was assumed in these calculations.

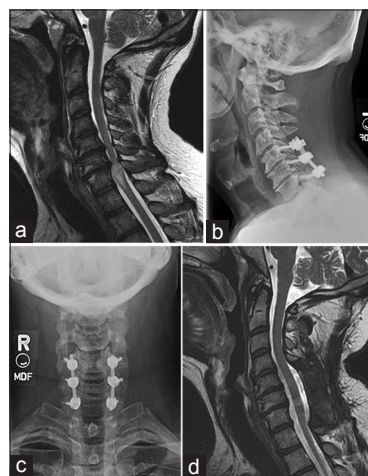


Figure 1: (a) T2-weighted sagittal MRI of a 47-year-old male with a history of CSM and severe gait dysfunction. He has spinal cord compression and significant spinal cord edema at the C6-7 level. He underwent C5-7 laminectomy and fusion to treat his condition. Postoperative lateral (b) and AP (c) plain radiographs demonstrate satisfactory placement of hardware and maintenance of his spinal alignment. He achieved significant gait improvement after surgery, and postoperative MRI demonstrated excellent spinal cord decompression and resolution of the edema

Table 1: Patient demographics

Demographic features	
Males	38
Females	20
Mean age	64 years
Average levels laminectomy	4.6
Average levels fused	4.5

Surgical selection

The patients in this series with CSM attributed to multilevel spinal cord compression were optimally treated utilizing a posterior approach consisting of laminectomy with fusion to address significant dorsal compression and/or in select cases to avoid postoperative kyphosis (e.g. related to preoperative alignment or segmental instability).

Description of surgical technique

For the 58 patients in this study, an average of 4.5 levels was decompressed utilizing laminectomy, and an average of 4.4 levels was fused. Local autograft (morselized lamina and spinous processes) was used in 100% of cases ($n = 58$), additionally supplemented with allograft 19.0% of the time ($n = 11$).

Intubation and intraoperative monitoring

As all patients had cord compression responsible for their underlying CSM, endotracheal intubation was performed utilizing either the fiber optic bronchoscope or GlideScope (video laryngoscopy; Verathon Inc, Bothell, WA).

Somatosensory evoked potentials (SSEPs) and motor evoked potentials (MEPs) were both monitored intraoperatively (IOM). Baseline MEPs and SSEPs were obtained after intubation, and prior to positioning. A 3-pin Mayfield head holder was used in all cases, with the patient positioned prone on chest bolsters. The patient's shoulders were secured with tape toward the feet to facilitate intraoperative fluoroscopy of the cervical spine. MEPs and SSEPs were repeated after the final position was obtained.

Cervical laminectomy and posterior fusion

A standard posterior midline incision was used with subperiosteal dissection and exposure of the spinous processes, lamina, and lateral mass facet complexes. Laminectomy was performed in en bloc fashion utilizing a high speed matchstick burr to drill troughs in the bone at the lateral edge of the lamina. The ligamentum flavum was incised using Kerrison rongeurs and the lamina were lifted off the spinal cord in one piece. The lamina and spinous processes were cleaned of soft tissue and morselized to be used as autograft. For fixation, a top loading lateral mass screw-rod system was utilized using the Margerl technique.^[27] The starting point for the screws was slightly medial and inferior to the midpoint of the lateral mass. Screws were angulated in line with the facets in the sagittal plane [Figure 2] and angled laterally aiming toward the rostral-lateral corner of the lateral mass. Arthrodesis was performed using morselized autograft in the majority of cases after decortication of the lateral masses and facet joints. Neck immobilization with an Aspen cervical collar was utilized in all cases for duration of 6 weeks.

RESULTS

mJOA Outcomes

The mean preoperative mJOA score was 13.2 (range 10-17, Std Dev 2.51) and the mean postoperative mJOA was 16.1 (range 11-18, Std Dev 1.77), with an average improvement of 2.9 (range 0-8, Std Dev 2.17) [Table 2]. The difference in mJOA score before and after surgery was statistically significant ($P < 0.0001$, CI -3.67 to -2.04). The average neurological recovery rate was 56.61% (range 0-100%, Std Dev 31.7%). Overall, 85.5% of patients improved at least one point in the mJOA score after surgery ($n = 51$) with 14.5% of patients having no improvement in mJOA ($n = 7$). No patients exhibited deterioration of their mJOA scores at last follow-up. All 58 patients had evidence of bony fusion on postoperative dynamic radiographs obtained an average of 11.9 months postoperatively (range 5-44 months).

Complications

There was a 10.3% overall complication rate ($n = 6$) that included minor complications. The most common complication, seen in four patients (6.9%), was a C5 nerve root palsy; all palsies completely resolved over a mean postoperative interval of 4 months (range 2 and 7 months). Other complications included one readmission for a fever of unknown origin, and one wound dehiscence of unknown etiology (e.g. no infection or seroma) that healed without further sequelae.

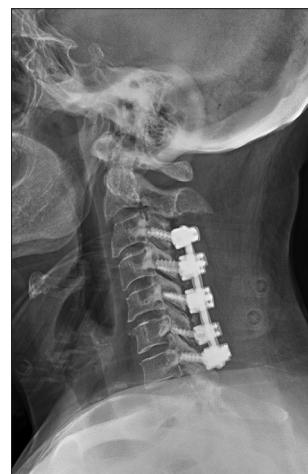

Figure 2: Lateral plain radiograph following C3-7 laminectomy and fusion demonstrating placement and trajectory of lateral mass screws

Table 2: Patient neurological function

	Mean	Range	Standard deviation
Preoperative mJOA	13.2	10-17	2.51
Postoperative mJOA	16.1	11-18	1.77
Increase mJOA	2.91	0-8	2.17
% Neurologic recovery	56.61	0-100	31.7

mJOA: Japanese orthopedic association

DISCUSSION

Background and rationale for cervical laminectomy and fusion

There is a lack of consensus regarding the optimal surgical technique for the management of moderate to severe CSM. A number of factors impact the choice of surgical procedure for CSM: Location of compressive pathology, spinal alignment, number of levels involved, clinical variables (e.g, age), surgeon preference, and even patient preference. For many years, cervical laminectomy alone was utilized to manage CSM. However, a recent survey of spine surgeons demonstrated that cervical laminectomy and fusion is now most commonly used (70%), followed by laminoplasty (23%), and laminectomy alone (7%).^[20]

Cervical laminectomy alone largely fell out of favor, due to the increased risk of postlaminectomy kyphosis attributed to the loss of the posterior musculoskeletal tension band (14-47%).^[18,25] In the Kaptain *et al.*, study, 46 CSM patients undergoing cervical laminectomy exhibited a postlaminectomy kyphosis rate of 21%; it was higher in patients with straight vs. lordotic preoperative alignment (30% vs. 14%).^[18] Postlaminectomy kyphosis was cited in 14-47% of cases in the Guidelines for the Surgical Management of Cervical Degenerative Disease.^[25] The latter authors concluded that “laminectomy with fusion improves functional outcome in patients with CSM and OPLL. Functional improvement is similar to laminectomy or laminoplasty in contrast to laminectomy, cervical laminectomy with fusion is not associated with late deformity.”^[2]

Concern regarding motion

Another reason to choose laminectomy and fusion over laminectomy is the limitation of motion thought to contribute to CSM. Although direct spinal cord compression is the most commonly encountered mechanism of spinal cord injury in CSM, dynamic forces (e.g, shear, distraction, and stretch injury) also play an important role.^[13] Cervical collars, commonly used in the nonoperative management of CSM, reduce motion, and can arrest/stabilize the progression of spinal cord injury in some cases. Inhibition of injury caused by motion attributed to successful fusion can also be beneficial without adequate cord decompression as shown by Bohlman *et al.* wherein 16 of 17 patients undergoing anterior cervical discectomy and fusion initially (ACDF) without removal of osteophytes or the posterior longitudinal ligament (e.g, without extended decompressions) exhibited good outcomes.^[4] Similarly, 85% of the Sorar *et al.*^[28] study had 20 CSM patients who underwent ACDF or corpectomy with fusion, and experienced 50% or greater neurological recovery (mJOA recovery rate) despite persistent magnetic resonance (MR)-documented spinal stenosis. While laminoplasty itself is not a fusion technique, many studies have

nevertheless shown a reduction in the amount of postoperative neck motion likely contributes to the subsequent improvement in myelopathy.^[7,26]

Cervical laminectomy and fusion in the medical literature

Gonzalez-Feria and Epstein initially described the utility of cervical laminectomy and fusion to treat CSM authors utilizing facet wiring for arthrodesis.^[8,12] Since then, there have been significant advances in spinal instrumentation, particularly including cervical laminectomy/fusion with lateral mass screw fixation. Highsmith *et al.* compared the results of cervical laminectomy and fusion (26 patients) to laminoplasty (30 patients) in 56 CSM patients; although the clinical improvement in the both groups was comparable (mean mJOA 12.4, mean improvement 2.8 points), but there was a statistically significant improvement in the neck visual analog scale (VAS) for the laminectomy and fusion group versus no improvement for the laminoplasty group.^[14] In a retrospective review of 38 patients undergoing laminectomy and fusion for CSM or OPLL by Houten *et al.*, patients demonstrated a similar degree of clinical improvement (e.g, as the mean preoperative mJOA score improved 2.7 points from 12.9 to 15.6).^[17]

Present study

The present study is one of the largest single center reports of consecutive patients undergoing cervical laminectomy and fusion for CSM. The mean mJOA score significantly improved 2.9 points (preoperative 13.2 to 16.1 postoperative), with a neurological recovery rate of 56.6%. These results were similar to those seen in other studies. Despite the older average age for this cohort of 64, the complication rate was fairly low (10.6%); there were no major complications requiring reoperation, and the 6.9% incidence of C5 palsies all fully recovered.

Our results compare favorably with the AOSpine North America multicenter prospective study that included 302 patients undergoing CSM surgery wherein 82 of 107 posterior cervical procedures consisted of laminectomy/fusion.^[9] Their patients averaged 62.9 years of age with slightly worse baseline mJOA scores of 11.7; notably, their overall complication rate was substantially higher (24.4%), and included a greater 8.5% major complication rate.

CONCLUSION

Cervical laminectomy and fusion is a safe and efficacious procedure for the treatment of CSM. The clinical outcomes appear to be quite reproducible, and this technique is an important part of a spine surgeon's armamentarium.

REFERENCES

1. Adams CB, Logue V. Studies in cervical spondylotic myelopathy. 3. Some functional effects of operations for cervical spondylotic myelopathy. *Brain* 1971;94:587-94.

2. Anderson PA, Matz PG, Groff MW, Heary RF, Holly LT, Kaiser MG, *et al*. Laminectomy and fusion for the treatment of cervical degenerative myelopathy. *J Neurosurg Spine* 2009;11:150-6.
3. Bartels RH, Verbeek AL, Benzel EC, Fehlings MG, Guiot BH. Validation of a translated version of the modified Japanese orthopaedic association score to assess outcomes in cervical spondylotic myelopathy: An approach to globalize outcomes assessment tools. *Neurosurgery* 2010;66:1013-6.
4. Bohlman H. Cervical Spondylosis with moderate to severe myelopathy: A report of 17 cases treated by Robinson anterior cervical discectomy and fusion. *Spine* 1977;2:151-62.
5. Chiles BW 3rd, Leonard MA, Choudhri HF, Cooper PR. Cervical spondylotic myelopathy: Patterns of neurological deficit and recovery after anterior cervical decompression. *Neurosurgery* 1999;44:762-9.
6. Ebersold MJ, Pare MC, Quast LM. Surgical treatment for cervical spondylitic myelopathy. *J Neurosurg* 1995;82:745-51.
7. Edwards CC 2nd, Riew KD, Anderson PA, Hilibrand AS, Vaccaro AF. Cervical myelopathy. Current diagnostic and treatment strategies. *Spine J* 2003;3:68-81.
8. Epstein NE. Laminectomy with posterior wiring and fusion for cervical ossification of the posterior longitudinal ligament, spondylosis, ossification of the yellow ligament, stenosis, and instability: A study of 5 patients. *J Spinal Disord* 1999;12:461-6.
9. Fehlings MG, Smith JS, Kopjar B, Arnold PM, Yoon ST, Vaccaro AR, *et al*. Perioperative and delayed complications associated with the surgical treatment of cervical spondylotic myelopathy based on 302 patients from the AOSpine North America Cervical Spondylotic Myelopathy Study. *J Neurosurg Spine* 2012;16:425-32.
10. Fehlings MG, Wilson JR, Kopjar B, Yoon ST, Arnold PM, Massicotte EM, *et al*. Efficacy and safety of surgical decompression in patients with cervical spondylotic myelopathy: Results of the AOSpine North America prospective multi-center study. *J Bone Joint Surg Am* 2013;95:1651-8.
11. Furlan JC, Kalsi-Ryan S, Kailaya-Vasan A, Massicotte EM, Fehlings MG. Functional and clinical outcomes following surgical treatment in patients with cervical spondylotic myelopathy: A prospective study of 81 cases. *J Neurosurg Spine* 2011;14:348-55.
12. Gonzalez-Feria L. The effect of surgical immobilization after laminectomy in the treatment of advanced cases of cervical spondylotic myelopathy. *Acta Neurochir* 1975;31:185-93.
13. Henderson FC, Geddes JF, Vaccaro AR, Woodard E, Berry KJ, Benzel EC. Stretch-associated injury in cervical spondylotic myelopathy: New concept and review. *Neurosurgery* 2005;56:1101-13.
14. Highsmith JM, Dhall SS, Haid RW Jr, Rodts GE Jr, Mummaneni PV. Treatment of cervical stenotic myelopathy: A cost and outcome comparison of laminoplasty versus laminectomy and lateral mass fusion. *J Neurosurg Spine* 2011;14:619-25.
15. Hirabayashi K, Miyakawa J, Satomi K, Maruyama T, Wakano K. Operative results and postoperative progression of ossification among patients with ossification of cervical posterior longitudinal ligament. *Spine* 1981;6:354-64.
16. Holly LT, Matz PG, Anderson PA, Groff MW, Heary RF, Kaiser MG, *et al*. Clinical prognostic indicators of surgical outcome in cervical spondylotic myelopathy. *J Neurosurg Spine* 2009;11:112-8.
17. Houten JK, Cooper PR. Laminectomy and posterior cervical plating for multilevel cervical spondylotic myelopathy and ossification of the posterior longitudinal ligament: Effects on cervical alignment, spinal cord compression, and neurological outcome. *Neurosurgery* 2003;52:1081-7.
18. Kaptain GJ, Simmons NE, Replogle RE, Pobereskin L. Incidence and outcome of kyphotic deformity following laminectomy for cervical spondylotic myelopathy. *J Neurosurg* 2000;93 (2 Suppl):199-204.
19. Law MD Jr, Bernhardt M, White AA 3rd. Cervical spondylotic myelopathy: A review of surgical indications and decision making. *Yale J Biol Med* 1993;66:165-77.
20. Manzano GR, Casella G, Wang MY, Vanni S, Levi AD. A prospective, randomized trial comparing expansile cervical laminoplasty and cervical laminectomy and fusion for multilevel cervical myelopathy. *Neurosurgery* 2012;70:264-77.
21. Matz PG, Anderson PA, Groff MW, Heary RF, Holly LT, Kaiser MG, *et al*. Cervical laminoplasty for the treatment of cervical degenerative myelopathy. *J Neurosurg Spine* 2009;11:157-69.
22. Matz PG, Holly LT, Mummaneni PV, Anderson PA, Groff MW, Heary RF, *et al*. Anterior cervical surgery for the treatment of cervical degenerative myelopathy. *J Neurosurg Spine* 2009;11:170-3.
23. Mummaneni PV, Kaiser MG, Matz PG, Anderson PA, Groff MW, Heary RF, *et al*. Cervical surgical techniques for the treatment of cervical spondylotic myelopathy. *J Neurosurg Spine* 2009;11:130-41.
24. Naderi S, Ozgen S, Pamir MN, Ozek MM, Erzen C. Cervical spondylotic myelopathy: Surgical results and factors affecting prognosis. *Neurosurgery* 1998;43:43-9.
25. Ryken TC, Heary RF, Matz PG, Anderson PA, Groff MW, Holly LT, *et al*. Cervical laminectomy for the treatment of cervical degenerative myelopathy. *J Neurosurg Spine* 2009;11:142-9.
26. Satomi K, Ogawa J, Ishii Y, Hirabayashi K. Short-term complications and long-term results of expansive open-door laminoplasty for cervical stenotic myelopathy. *Spine J* 2001;11:26-30.
27. Silveri CP, Vaccaro AR. Posterior atlantoaxial fixation: The Magerl screw technique. *Orthopedics* 1998;21:455-9.
28. Sorar M, Seckin H, Hatipoglu C, Budakoglu I, Yigitkanli K, Bavbek M, *et al*. Cervical compression myelopathy: Is fusion the main prognostic indicator? *J Neurosurg Spine* 2007;6:531-9.
29. Wilkinson M. Cervical spondylosis. *Practitioner* 1970;204:537-45.
30. Young WF. Cervical spondylotic myelopathy: A common cause of spinal cord dysfunction in older persons. *Am Fam Physician* 2000;62:1064-70.