

# Research trends and perspectives on immediate facial reanimation in radical parotidectomy (Review)

IULIAN FILIPOV<sup>1,2</sup>, LUCIAN CHIRILA<sup>3</sup>, FEDERICO BOLOGNESI<sup>4,5</sup>,  
MIHAI SANDULESCU<sup>6</sup>, SERGIU DRAFTA<sup>7</sup> and CORINA MARILENA CRISTACHE<sup>8</sup>

<sup>1</sup>Doctoral School, 'Carol Davila' University of Medicine and Pharmacy, 020021 Bucharest; <sup>2</sup>Department of Maxillofacial Surgery, 'Queen Maria' Military Emergency Hospital, 500007 Brasov; <sup>3</sup>Department of Oral and Maxillofacial Surgery, 'Carol Davila' University of Medicine and Pharmacy, 010221 Bucharest, Romania; <sup>4</sup>Oral and Maxillo-Facial Surgery Unit, IRCCS Policlinico di Sant'Orsola, I-40138 Bologna; <sup>5</sup>Department of Biomedical and Neuromotor Sciences (DIBINEM), University of Bologna, I-40100 Bologna, Italy; Departments of <sup>6</sup>Implant Prosthetic Therapy and <sup>7</sup>Fixed Dental Prosthetics and Occlusion, Faculty of Dental Medicine, 'Carol Davila' University of Medicine and Pharmacy, 010221 Bucharest; <sup>8</sup>Department of Dental Techniques, 'Carol Davila' University of Medicine and Pharmacy, 050474 Bucharest, Romania

Received July 13, 2023; Accepted September 5, 2023

DOI: 10.3892/br.2023.1663

**Abstract.** For patients diagnosed with advanced malignant parotid tumour, radical parotidectomy with facial nerve sacrifice is part of the treatment. Multiple surgical techniques have been developed to cure facial paralysis in order to restore the function and aesthetics of the face. Despite the large number of publications over time on facial nerve reanimation, a consensus on the timing of the procedure or the donor graft selection has remained to be established. Therefore, the aim of the present study was to conduct a bibliometric analysis to identify and analyse scientific publications on the reconstruction of the facial nerve of patients who underwent radical parotidectomy with facial nerve sacrifice. The analysis on the topic was conducted using the built-in tool of the Scopus database and VOSviewer software. The first 100 most cited articles were separately reviewed to address the aim of the study. No consensus was found regarding the recommended surgical techniques for facial nerve reanimation. The most used donor cranial nerves for transfer included the following: Masseteric branch of the V nerve, contralateral VII nerve with cross-face graft, the XI nerve and the XII nerve. The best timing of surgery is also controversial depending on pre-existing pathology and degree of nerve degeneration. However, most of the clinical experience suggests facial nerve restoration immediately after

the ablative procedure to reduce complications and improve patients' quality of life.

## Contents

1. Introduction
2. Literature search and bibliometric analysis
3. Tumoral nerve invasion
4. Grading systems
5. Neurophysiological preoperative assessment of facial nerve function
6. Imaging in ablative and reconstructive surgery of the facial nerve
7. Intraoperative management of tumoral invaded facial nerve
8. Timing of facial nerve reanimation
9. Strengths and limitations of the study
10. Conclusions

## 1. Introduction

According to the 5th edition of the World Health Organization Classification of Head and Neck Tumours from 2022, salivary gland tumours (SGTs) consist of 15 benign and 21 malignant entities of epithelial origin, one type of benign mesenchymal tumour and two types of non-neoplastic epithelial lesions (1,2). SGTs are rare, with the overall incidence of benign and malignant tumours accounting for 2.5-3.0 cases per 100,000 individuals in Western countries (3). Most benign tumours arise in major glands (~70%) (4). The majority of benign tumours (e.g. pleomorphic adenomas, Warthin tumours, basal cell adenomas) involve the parotid gland (70%), while malignant tumours mostly involve the minor glands (56%), followed by the parotid gland (34%) (4). According to Rousseau and Badoual (5), 15-32% of parotid tumours

---

*Correspondence to:* Professor Corina Marilena Cristache, Department of Dental Techniques, 'Carol Davila' University of Medicine and Pharmacy, 8 Eroilor Sanitari Blvd., 050474 Bucharest, Romania  
E-mail: corina.cristache@umfed.ro

*Key words:* parotid malignancy, facial nerve sacrifice, facial reanimation, bibliometric analysis

are malignant. Even though parotid gland tumours are not very frequent, the presence of the facial nerve, a significant functional structure within the parotid, has raised significant interest focused on this pathological entity.

Surgery is the standard treatment for parotid cancer and parotidectomy is a common procedure in parotid tumour entities. Parotidectomy with facial nerve preservation is a pre-requisite ever since it was first described by Thomas Carwdine in 1907 (6). Whether the mass lies above or below the plane of the facial nerve, there is a consensus that facial nerve branches should not be sacrificed unless there is clear evidence of tumoral nerve involvement. Close margins do not necessarily prognosticate an unfavourable result (7). However, advanced neoplasms with facial nerve involvement require radical parotidectomy in conjunction with facial nerve resection (8,9). Facial nerve rehabilitation is an important goal to be achieved for increasing the quality of patients' life, the priority being corneal protection and maintenance of oral competence, followed by the restoration of facial symmetry and dynamic movements (8).

Multiple surgical techniques have been developed for curing facial paralysis and thus restore the function and aesthetics of the face. Both the literature and previous clinical results from our group encourage the idea of performing facial nerve restoration immediately after the ablative procedure in order to avoid repeated general anesthesia, to prevent neural scarring and difficulty identifying nerve endings.

Despite the great number of publications over the last decade on facial nerve reanimation, a consensus on the timing of the procedure or the donor graft selection has remained to be established. Therefore, it is necessary to summarize the research on facial reanimation in radical parotidectomy, highlighting the trends over time and the advantages of the new techniques.

Bibliometric analysis is a precise mathematical and statistical evaluation of publications (such as journal articles, books and proceedings), using literature databases, to provide new insight into specific research/clinical fields (10). Using such computer-assisted review methodology, core research or authors, as well as their relationship, may be identified by covering all of the publications related to a given topic of interest (11).

The aim of the present study was to conduct a bibliometric analysis to identify and analyse scientific publications on the reconstruction of the facial nerve in patients who underwent radical parotidectomy with facial nerve sacrifice in order to improve the understanding of the importance of the timing of facial reanimation.

## 2. Literature search and bibliometric analysis

A bibliometric analysis was performed using the in-built tool of the Scopus database (Elsevier) and VOSviewer software (version 1.6.19) developed by van Eck and Waltman at Leiden University's Centre for Science and Technology Studies, The Netherlands (12), following the guidelines proposed by Donthu *et al* (11).

*Search strategy.* A Scopus database search was conducted up to June 2023, containing the following keywords, with the Boolean operator OR: ('radical parotidectomy' OR 'facial

nerve reinnervation' OR 'facial reanimation' OR 'concurrent facial reanimation' OR 'facial reanimation timing'); limited to the English language; study type limited: Article, review, book chapter.

The full record and cited references were retrieved and exported in comma-separated values format for further analysis in VOSviewer software.

Scopus in-built tools were used to assess the distribution of the studies in terms of publication year, country/region, journal and top cited articles. VOSviewer software was used to perform data mining, mapping and clustering of the retrieved articles.

*Reviewing of the most cited articles.* The top 100 most cited articles were independently reviewed by two researchers (IF and CMC) looking for answers to the following questions, in accordance with the aim of the present study: i) Tumoral nerve invasion; ii) facial nerve grading systems; iii) neuro-physiological preoperative assessment of facial nerve function; iv) imaging in ablative and reconstructive surgery of the facial nerve; v) intraoperative management of tumoral invaded facial nerve; and vi) timing of facial nerve reanimation.

To complete the literature review, besides the selected articles, a manual search in the 10 most relevant journals, revealed from the bibliometric analysis, as well as in the reference lists of the included papers, was also performed.

*Search results.* A total of 851 publications were retrieved from the Scopus database, published from 1970 to June 2023. These documents were full articles (79%), reviews (15.2%) and book chapters (5.2%). A constant increase in the number of articles published was noticed, with a peak in 2021 (72 documents) (Fig. 1A), published from >57 countries, with a considerably higher rate of publications coming from the USA (n=361; 42.4%), followed by the United Kingdom (n=80; 9.4%) and Italy (n=65; 7.6%; Fig. 1B). The network visualization of the co-authorship relationship between countries obtained in VOSviewer software is displayed in Fig. 1C. The size of the circles is proportional to the occurrence in the country. Only countries with a minimum of 5 articles were included. The USA is an important center of research on radical parotidectomy with facial nerve reconstruction, in close collaboration with the United Kingdom, Canada, Germany and Italy. A recent center is South Korea, in close connection with Canada.

Among the countries with research on facial reanimation and parotid neoplasm, the first five representative institutions (out of the 161 institutions with at least three publications in the field) are as follows: Massachusetts Eye and Ear Infirmary (Boston, USA), Harvard Medical School (Boston, USA), Johns Hopkins School of Medicine (Baltimore, USA), University of Toronto (Toronto, Canada) and Ospedale San Paolo (Milan, Italy). The top 10 institutions in terms of productivity in the analyzed field are presented in Fig. 2.

The network map showing the collaboration between the institutions with research published in the field is illustrated in Fig. 3. All organizations with a minimum of one article were included.

The main financial support for the research was provided by the following 10 institutions: National Institute of Neurological Disorders and Stroke (USA), Japan Society for the Promotion of Science (Japan), National Institute on Deafness and Other Communication Disorders (USA), National Center for

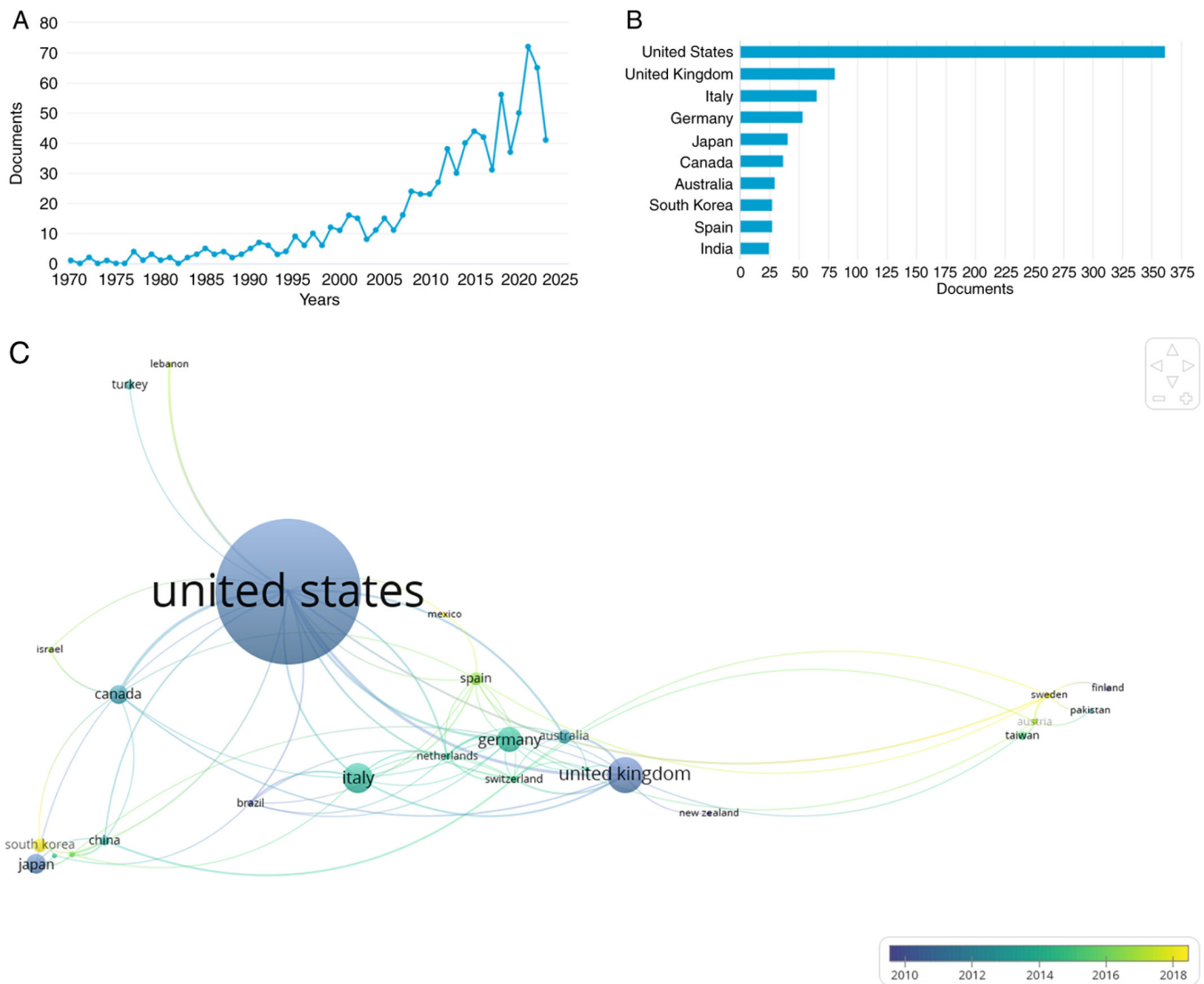


Figure 1. Distribution of the published research on the topic among years and countries. (A) Yearly distribution of the published articles; (B) country distribution; (C) network map showing the relations (co-authorship) between various countries. The colors of links between countries indicate the publication year, with the most recent contributions being marked in yellow color. The size of the circles and their labels is proportional to the number of publications.

Advancing Translational Sciences (USA), National Institutes of Health (USA), Deutsche Forschungsgemeinschaft (Germany), National Cancer Institute (USA), National Institute for Health and Care Research (Great Britain), National Institute of Dental and Craniofacial Research (USA) and National Natural Science Foundation of China (People's Republic of China), with most of the financial support being from the USA (7 out of 10).

The top 10 journals in terms of the number of articles published on facial reanimation in parotid neoplasms are as follows: Plastic and Reconstructive Surgery (70 papers), Journal of Plastic, Reconstructive and Aesthetic Surgery (67 papers), Journal of Craniofacial Surgery (35 papers), Annals of Plastic Surgery (32 papers), Laryngoscope (30 papers), JAMA Facial Plastic Surgery (22 papers), Journal of Cranio-Maxillo-Facial Surgery (19 papers), Facial Plastic Surgery (17 papers), Head and Neck (17 papers) and Current Opinion in Otolaryngology and Head and Neck Surgery (16 papers) (Fig. 4). Of note, the trend of an increased number

of publications on the topic in the last years was observed. The Journal of Plastic, Reconstructive and Aesthetic Surgery published 8 papers on the topic in 2015 and the Journal of Cranio-Maxillo-Facial Surgery published 8 papers on the topic in 2021 and another 8 in 2022.

The authors with the largest number of publications in the field are displayed in Fig. 5A and the most cited authors are presented in Fig. 5B.

The co-authorship network, including authors with at least one publication on the topic, clustered on research groups, is displayed in Fig. 6. The color code highlights the date of published articles, the most recent being colored in yellow.

When performing the key-words analysis, the minimum number of occurrences of an author's key word was set at 5. Out of 1,218 keywords, 88 meet the threshold. Among the most commonly used keywords by the authors are: Facial reanimation, facial paralysis, facial palsy, hypoglossal nerve, masseteric nerve and facial nerve (Fig. 7).

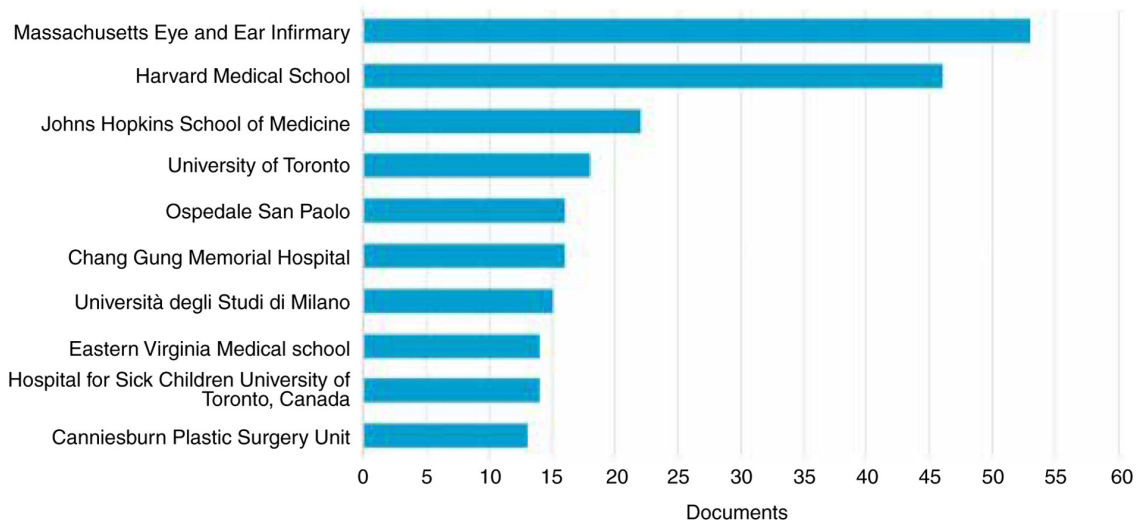


Figure 2. Top 10 productive organizations in the analyzed field.

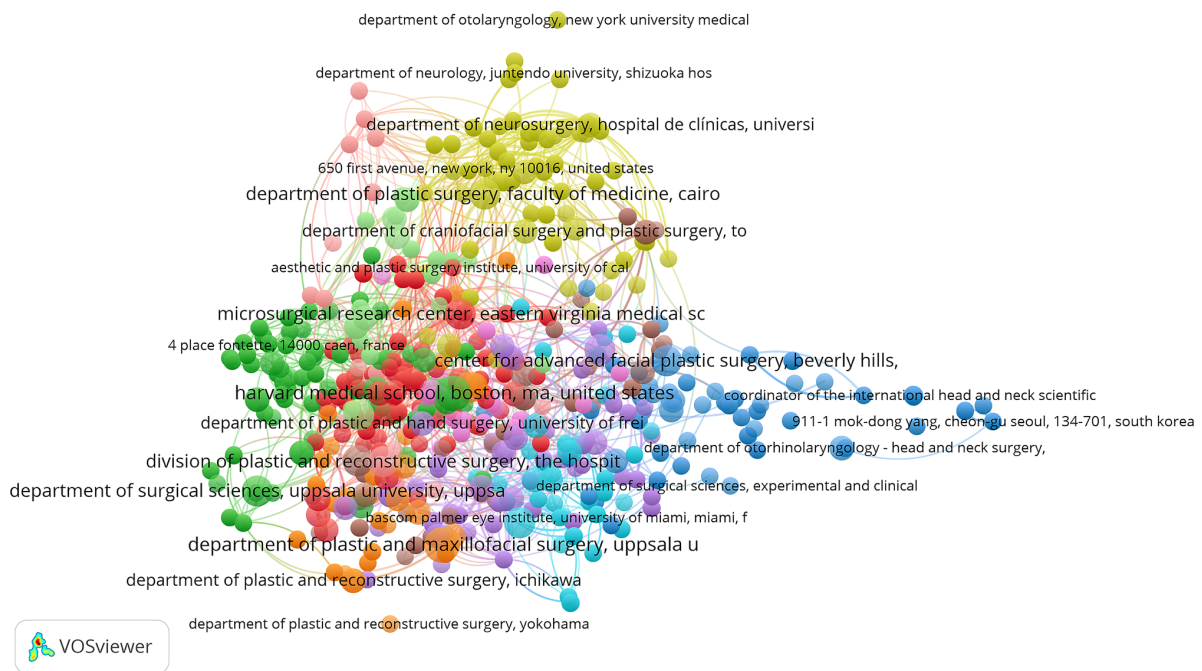


Figure 3. Network map illustrated with VOSviewer software showing the collaborations between various organizations in terms of research on facial reconstruction in radical parotidectomy. The color of an element (organization research) is determined by the cluster to which the element belongs and the lines between the elements represent the links between the organizations (co-authorship of the papers).

### 3. Tumoral nerve invasion

The face is one of the most important parts of the human body and facial expressions represent a critical pillar in non-verbal communication. Nerve invasion can occur in a variety of malignant tumours, and together with the tumour grade and stage, has been reported as a strong prognostic factor for survival (13). Facial palsy may have different causes: Nerve invasion, extrinsic compression and inflammation. Perineural and intraneural nerve invasion may vary between 7% (14) and 69.1% (for patients with parotid cancer and preoperative facial weakness) (13). The tumour diameter has been determined to be associated with the risk of facial nerve invasion, with

tumours sized >4-5 cm having positive facial nerve margins in >80% of cases (15,16). Paraesthesia and pain are two predictive factors of perineural nerve invasion (13).

Whether diagnosed preoperatively or intraoperatively, facial nerve invasion by the malignant neoplasm is an indication for radical parotidectomy, a procedure in which part of the nerve or even the entire nerve branching from the stylomastoid foramen exit to the parotid margins requires to be surgically removed. This may cause an impairment for the patient, both functionally and psychosocially. According to Bovenzi *et al* (17), facial nerve sacrifice was recorded in 3.7% of cases of parotid tumour and only 25.5% of those patients underwent a concurrent reinnervation procedure. Lu *et al* (18)

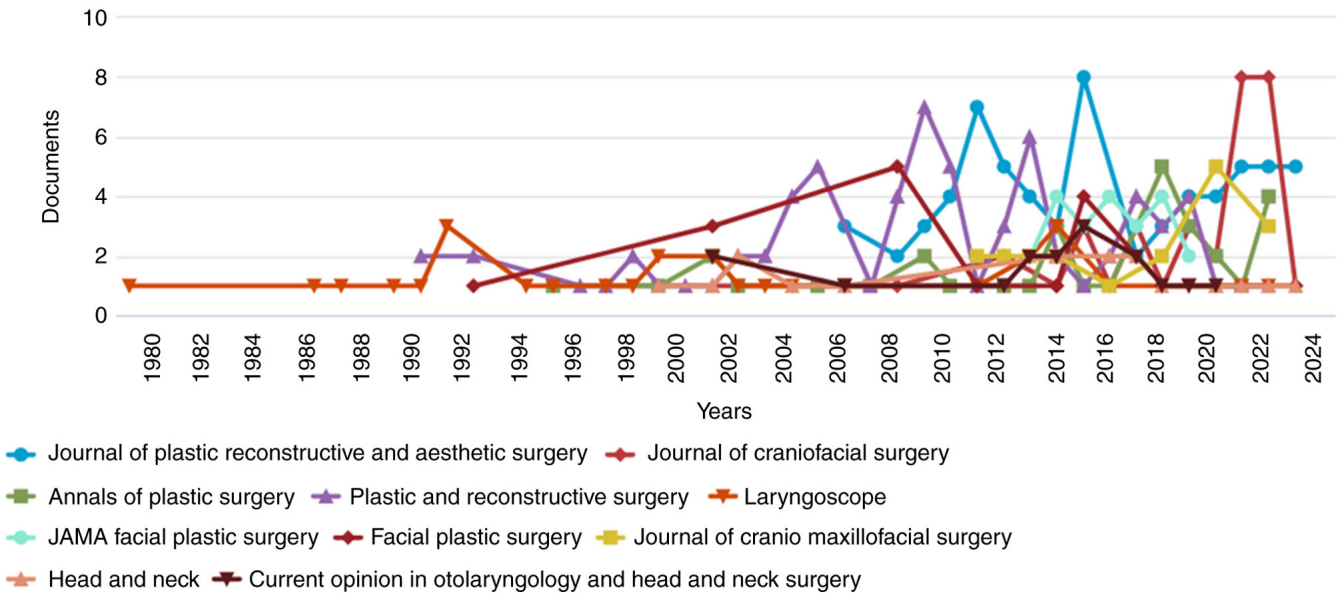


Figure 4. Top 10 journals with the highest number of publications and their yearly distribution.

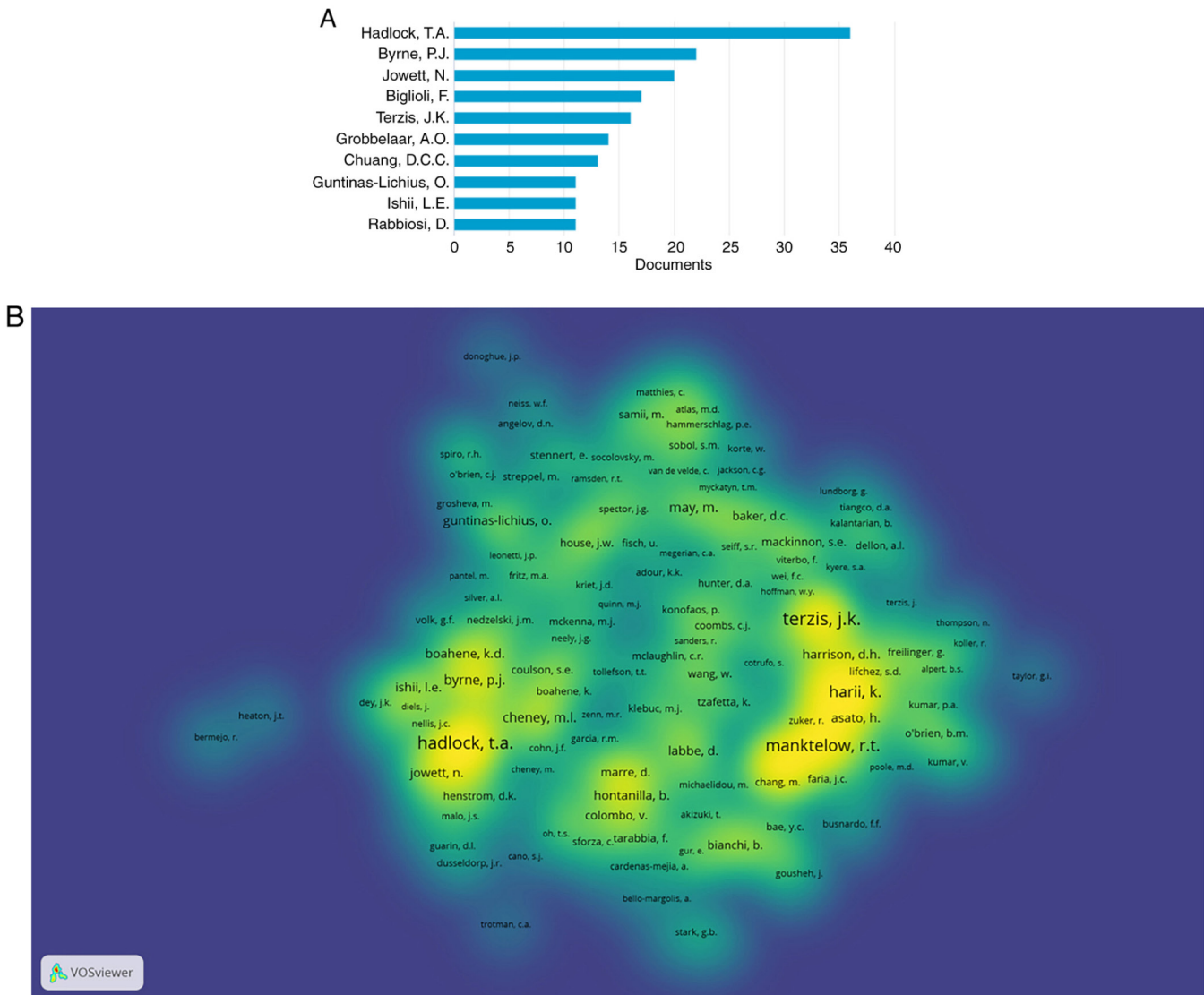


Figure 5. Analysis by author. (A) Top 10 authors in terms of the number of published papers on the analyzed topic. (B) Density map of the authors with the highest number of citations on the topic.



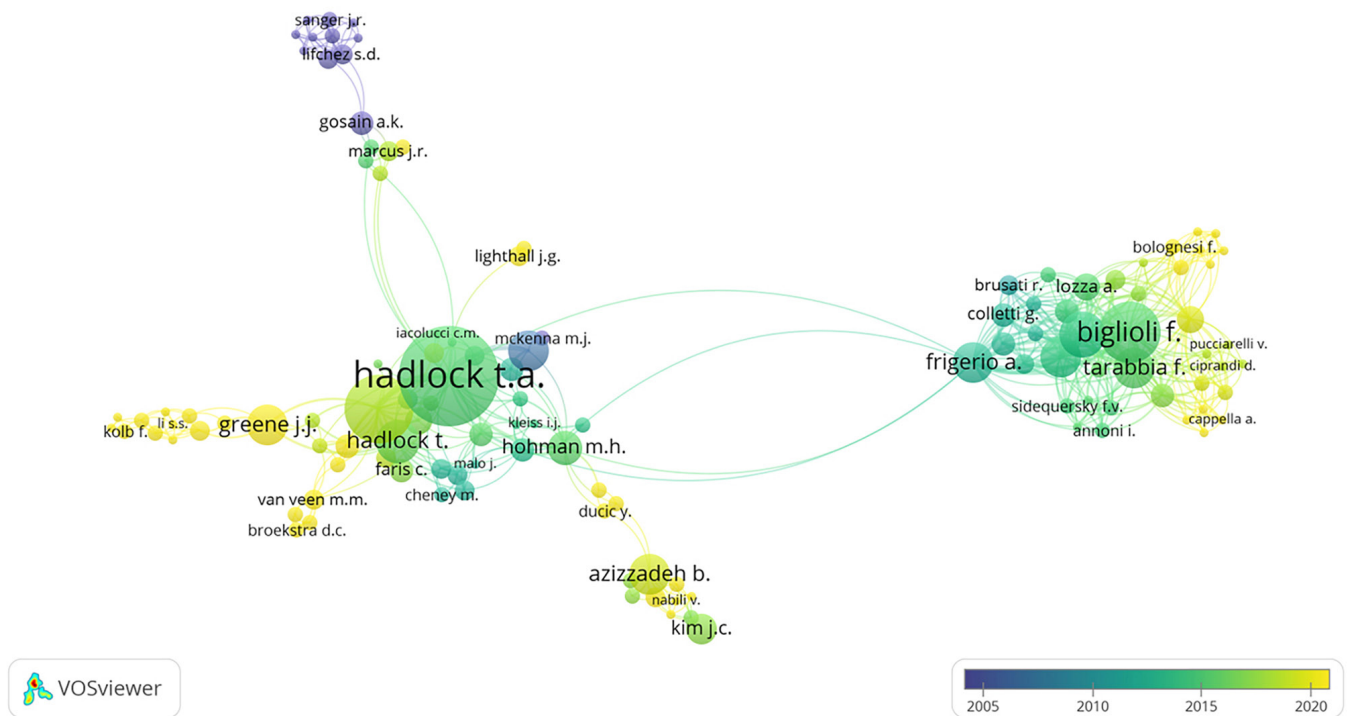


Figure 6. Researchers' network clustered based on research groups. The size of the labels and the circles indicates the weight of the items (number of publications). The links represent co-authorship. The researchers with yellow labels published in recent years.

found a similar percentage of patients that underwent concurrent facial reanimation (31.2%) of any type, after radical parotidectomy. Since facial weakness may be caused not only by tumoral invasion, the question arises of how surgeons should make the decision of whether to spare or sacrifice the facial nerve (19). Extrinsic tumoral compression or inflammatory processes (20) may also determine facial weakness and in this situation, a thorough intraoperative evaluation is a critical factor in the decision-making process of facial nerve management. In a comprehensive study, Park *et al* (13) found that in cases with nerve reaction, 26.9% had intra-neural tumour invasion, 42.3% had perineural invasion and 30.8% had no neural invasion of the facial nerve. This understanding is crucial because facial weakness did not always indicate tumour invasion of the facial nerve. As a consequence, the decision to preserve or sacrifice the facial nerve should be based on intraoperative additional findings.

#### 4. Grading systems

In order to evaluate the status of the facial nerve either before or after treatment, several facial nerve grading systems were established. An ideal method for evaluating the facial nerve has to be easy to use even by inexperienced clinicians, reproducible, fast, objective, with minimal expenses involved and clinically relevant. House and Brackmann (21) classified grading systems into 3 categories: Gross, regional and specific. Also, they introduced the concept of weighted or unweighted regional grading systems. Weighted means that certain areas of the face are given less importance within the grading system due to less functional or aesthetic importance (e.g. the forehead) (22). Specific systems

highlight the existence of certain associated symptoms and signs.

In 1971, Adour and Swanson (23) suggested a weighted grading system, comparing the frontal, eye and mouth regions of the face on the paralyzed compared with the normal side. In 1976, Yanagihara (24) described an unweighted system that assesses 10 areas of facial function, without the consideration of secondary effects. Subsequently, in 1977, Stennert *et al* (25) described a double-weighted system: Face at rest, weighted at 40%; and in motion, weighted at 60%. The different regions of the face were also weighted. Secondary effects were graded independently (25).

Since 1985, the House-Brackmann (H-B) scale is the most frequently used grading scale to evaluate the function of the facial nerve (26). As it is based on clinical observational judgment, which may differ from one clinician to another, this option is a clinical means to assess the voluntary facial motion and categorize 6 degrees of facial nerve impairment. There are 6 grades within the H-B grading system: Grade 1 indicates a functionally normal face; grade 2 patients show mild facial weakness; grade 3 indicates moderate weakness with the ability to voluntarily close the eye; grade 4 patients show moderate weakness without volitional eye closure ability; grade 5 indicates severe facial weakness; and grade 6 represents total facial paralysis.

The Bures-Fisch (B-F) linear measurement system (26) was introduced in 1986 and it consists of 3 parts: The patient's global analysis, the physician's detailed analysis and the physician's global evaluation. In the patient's analysis, a gross self-evaluation is performed in order to evaluate the improvement, and it is expressed as a percentage. In the physician's detailed analysis, a weighted approach is performed: The



overall disfigurement and offers a graphic output (34). Facial Assessment by Computer Evaluation (FACE) software is a computer-based clinical tool, designed for facial analysis and described by Hadlock and Urban (35). The program involves a photography-based concept by analysing facial photography at rest and during 5 standard movements. According to the authors, with the use of the FACE program, the mean time to complete a set of measurements was only 1.3 min, which provides a significant benefit in clinical practice (35).

The Facial Motor Evaluation scale was developed and validated by Ojha *et al* (36) to overcome the limitations regarding the subjectivity and the expertise of the professionals administering the tests (e.g. H-B, B-F, SFGS tests), the requirements of specific software, hardware, longer data entry time such as for the case of e-FACE software and the lack of graphic representations of scoring criteria.

### 5. Neurophysiological preoperative assessment of facial nerve function

Since for patients diagnosed with advanced malignant parotid tumour, radical parotidectomy is part of the treatment, there is the need for a clear therapeutic evaluation, in order to establish whether facial nerve sacrifice is required so that a negative oncological margin can be achieved. According to the study by Bendet *et al* (37) from 1998, facial neurological deficit may become visible after more than half of the facial nerve fibres are invaded by the malignant neoplasm. The key implication drawn from this fact is that in numerous oncological patients, there is a subclinical nerve degeneration and an objective and reliable method is necessary to assess the facial nerve integrity. Facial nerve degeneration may be quantitatively assessed using facial neurography, which is a reliable method in numerous conditions affecting the facial nerve (37,38). This examination is based on a comparative result between stimulation of the facial nerve on the healthy side and the contralateral side. Facial electroneurography (ENG) is a subclinical analysis that may influence the therapeutical decision-making process (39), as it may objectively establish the degree of nerve damage preoperatively and postoperatively.

In a prospective study on 33 patients with parotid neoplasms, Aimoni *et al* (40) found, in 3 out of the 6 patients with a histologically confirmed malignant tumour, potential abnormalities of amplitude and latency of the facial movements in the absence of facial nerve deficits, indicating a strong need for objective neurophysiological assessment. However, their study was limited in its application, as the number of patients with parotid cancer was relatively small (only 6 patients with parotid gland cancer). Wiertel-Krawczuk *et al* (39) found a positive correlation between changes in facial motor fibre transmission, determined on facial motor nerve fibers (ENG), and the type of tumour. This understanding is crucial because neurophysiological preoperative assessment of each facial nerve branch can guide the clinician in the decision-making process and allows them to decide on surgical nerve reconstruction at an appropriate time, depending on the degree of neural degeneration. Timing of surgical nerve reconstruction can be divided into immediate, early (1 month), delayed (3 to 6 months) and late (1 to 2 years or more). When electrodiagnostics reveal a

complete lesion of a neural branch (neurotmesis), immediate nerve reconstruction is desired (39).

### 6. Imaging in ablative and reconstructive surgery of the facial nerve

Preoperative prediction of the facial nerve status and its relation to the parotid neoplasm is of tremendous importance for surgical planning, since it is a highly vulnerable structure with a complex course, prone to injury during parotid surgery. Imaging tools commonly used in preoperative assessment are ultrasonography, computed tomography (CT) and magnetic resonance imaging (MRI). The choice of the imaging modality utilized in the assessment of the facial nerve and relation with other anatomical or pathological structures is dependent on the differential diagnosis, patient status, localization of the pathological entity and purpose of the investigation (41).

Ultrasonography is a dynamic non-invasive diagnostic tool that has several advantages over other imaging diagnostic tools, namely: It is fast and cheap, has the ability to be used at the bedside and does not require radiation. Due to recent advancements in high-resolution ultrasonography, this investigation allows the assessment of the extra-temporal course of the facial nerve in an accurate and reproducible way. High-resolution ultrasonography is a valuable diagnostic tool, as it has a superior resolution; it is faster and more dynamic in comparison to conventional ultrasonography. Wegscheider *et al* (42) found that the use of a 5-18 MHz linear array transducer facilitated the identification of the main facial nerve trunk, parotid plexus and branches innervating the orbicularis oculi and zygomatic major muscle in 8 cadaveric hemifaces, as follows: The main trunk was identified in 75% (6 out of 8) of the cases, parotid plexus was clearly identified in 100% (8 out of 8) of the cases, the branches innervating the orbicularis oculi muscle were identified in 7 out of 8 cases (87.5%) and the branches innervating the zygomatic major muscle in 6 out of 8 cases (75%). Also, the furcation of the main trunk of the facial nerve was clearly visible on 4 of 4 sides (100%) *in vivo* in the two volunteers included in the study (42). However, the study has limitations, as it was performed mostly on cadavers and the number of specimens was small.

Conventional CT and MRI may offer significant information related to the extent of the parotid neoplasm and the relation of the tumour to the stylomastoid foramen. As is common practice in numerous countries, CT scans together with ultrasounds are the first choice of imaging investigations in cases of patients clinically diagnosed with parotid tumour. When using CT to evaluate the facial nerve, high-resolution temporal bone CT may offer valuable information regarding the intra-fallopian segment of the facial nerve to the stylomastoid foramen, but the intratemporal part of the nerve may be indirectly assessed, only if the pathological entity determined bone erosion or destruction (41). For the assessment of the extratemporal segment of the facial nerve, MRI has proven to be a more accurate imaging examination.

MRI can also be used as a valuable tool in the assessment of the facial mimetic muscles in long-standing paralysis cases and in exploring the status of postoperative free flaps, or facial muscle growth after facial nerve reconstruction (43). However, it has been previously demonstrated that certain MRI sequences



may enable visualizing the facial nerve from the stylomastoid foramen at least to the level of the proximal part or even further for both cervico-facial and temporo-facial trunks in a predictable and repeatable manner. Guenette *et al* (44) assessed 32 facial nerves of 16 healthy patients, with no exceptions. The same success rate was described for the assessment of the facial nerve in 4 patients diagnosed with parotid tumours. A weakness of his study was that in only 3 out of 36 nerve assessments, an intraoperative anatomical validation had been made by the surgeon. In a comprehensive prospective study, Takahashi *et al* (45) made the preoperative assessment of the main trunk of the facial nerve, as well as the cervico-facial and temporo-facial divisions, using high-resolution MRI with a surface coil. The imaging results were then superimposed with the anatomical surgical findings. The accuracy of the MRI assessment of the facial nerve is reflected by the following numerical data: The main trunks and cervico-facial and temporo-facial divisions of the facial nerves were identified in 100, 84.1 and 53.8%, respectively, in the axial plane of three-dimensional gradient-recalled acquisition in the steady-state images and the relationships of the tumours to the facial nerves were correctly diagnosed in 11 (91.7%) of 12 cases (45). That study highlighted the important value of high-resolution MRI using specific sequences in the preoperative evaluation of the facial nerve status and its relation with the parotid tumour.

## 7. Intraoperative management of tumoral invaded facial nerve

There is currently no consensus on the best practice for immediate facial reanimation. Mild improvement of facial palsy will tremendously improve the quality of life. Static and dynamic reanimation may be performed. Non-vascularized nerve grafts are used for facial nerve reconstruction and there are various alternatives for donors, e.g. greater auricular nerve, sural nerve, medial or lateral antebrachial cutaneous nerve, superficial radial nerve or thoracodorsal nerve.

*Quality of life.* Even though there is a subjective component of perception from one individual to another, a disabled person is likely to have a lower quality of life. Facial palsy has a tremendous negative impact both on functional and psychological status of patients affected by this disorder. The inability to physiologically move the mimetic muscles may jeopardize numerous functions dependent on these muscles. Speech disturbance, saliva running out of the mouth, dropping eye or corner of the mouth, as well as eating difficulties, are common functional issues specific to facial palsy. The perception of individuals suffering from facial paralysis by others may also lead to the deterioration of the quality of life for the affected individual (46). In a study published by Walker *et al* (47), it was indicated that 60% of all patients showed symptoms suggestive of anxiety and/or depression. The communication is clearly disturbed due to numerous factors: Decreased facial movement was the most frequent cause reported by the affected individuals (74%), followed by synkinesis as a second reason (48%), dislike of their facial appearance (13%) and facial asymmetry (3%) (46). Coulson *et al* (46) reported that 50% of the patients classified themselves as not effective at expressing

one or more of the six primary emotions described by Ekman (48) (happiness, disgust, surprise, anger, sadness and fear).

Clinicians should be aware of the risk factors involved in the dysfunction of facial nerves, and proper preoperative information related to the management of facial nerves should be delivered to the patients. Multiple studies have established the importance of facial palsy treatment in order to increase the quality of life of the patients who had radical parotidectomy (49), as well as pre- and postoperative psychological counseling.

*Immediate reanimation options in radical parotidectomy.* Optimal reconstruction following a radical parotidectomy requires that several aspects should be aesthetically and functionally restored. Contour deformity, cutaneous defects and facial reanimation are the main issues to be addressed. For facial reanimation, the available options may be grossly classified into cable grafting procedures, regional muscle transfer and suspension procedures (50,51). One of the main important ablative sequelae to be managed is the inability to close the eye.

Immediate or recent facial reanimation after radical parotidectomy has several benefits; two of the most important gains are the duration of paralysis, which is shortened, and the quality of life, which is statistically higher in patients whose facial reanimation was performed in an immediate or recent approach in comparison to those that had a delayed reanimation (52). Repeated general anesthesia, neural scarring, Wallerian degeneration and difficulty in identifying nerve endings are the disadvantages of performing facial reanimation in a delayed approach. However, due to several aspects, in most of the oncological ablative procedures that involve sacrificing the facial nerve, only some of the patients benefit from facial reanimation or ancillary procedures. Lu *et al* (18) found that one-third of the oncological patients whose main procedure was radical parotidectomy had concurrent or recent reanimation.

Depending on the nerve resection extent and availability of the proximal/and distal part of the facial nerve, several options are available for facial nerve reconstruction: Direct coaptation/neuroorrhaphy [usually when <1 cm is missing (18)], cable grafting, mastoidectomy to assess the proximal segment of the facial nerve + cable grafting, and nerve substitution, when the proximal part of the nerve is not accessible (53).

Other different ways to make the classification of the procedures to be performed in facial reanimation are nerve-type repairs, non-nerve or sling-type repairs and muscle-free flap procedures (51).

Salivary drooling and incompetence in closing the eye are common complications after an ablative tumour procedure. Mixing both static and dynamic facial reanimation is the treatment of choice for such patients (54).

Frozen sections are supposed to be performed both at the proximal and distal stump of the resected facial nerve. However, positive margins do not significantly affect nerve recovery according to a study published by Wax and Kaylie (55).

In order to facilitate the adaptation between the caliber of the nerve graft and several distal stumps of the facial nerve, the stumps can be pulled together and coated to a single extremity of the nerve graft (56). Another option is to divide the graft

in order to make the coaptation with multiple distal stumps possible (57).

Cable grafting cases have a larger rate of synkinesis in comparison to direct coaptation (58,59). Using 2 different neural inputs for the upper and the lower aspect of the face also decreases the likelihood of sinkinetic complication (56).

The distinction between quantitative and qualitative neural inputs also requires consideration. Tomita *et al* (60) described the concept of double innervation by mixing neural inputs from both the hypoglossal (quantitative source) and facial nerve (qualitative input). Bianchi *et al* (61) and Biglioli *et al* (62) introduced double enervation with masseteric and contralateral facial input.

The masseteric nerve provides neural input, decreasing the risk of muscular fibrosis and cross-facial nerve grafts offer spontaneity to smile. Combining these two options, the complication of sinkinesis is decreased, since the nerves corresponding to the upper face have different neural input in comparison to the muscles of the lower face (63).

The recovery time is also decreased due to the neural input from the masseteric nerve (53). A technique featuring triple neural inputs was later on described by Biglioli *et al* (64). For recent paralysis [cases in which electromyography (EMG) was used to confirm the presence of fibrillations], 3 neural sources were used: 2 quantitative neural inputs (masseteric and 30% of hypoglossal nerve) and one qualitative source (contralateral facial nerve via two sural nerve cable grafts). The temporo-facial branch (on the paralyzed side of the face) is supposed to be identified, sectioned and skeletonized, and an end-to-end coaptation must be performed to the masseteric nerve, previously dissected. The cervico-facial branch (on the paralyzed side of the face) is identified and sectioned in a similar manner to the one described for the temporo-facial one. After an epineural window is created on the hypoglossal nerve and 30% of this nerve is incised, an end-to-side coaptation between the cervico-facial and hypoglossal nerve must be performed. In order to achieve a tension-free coaptation, a short surreal nerve graft should be used (64).

When wide excision of malignant neoplasms is required, in numerous cases, an important part of the mimetic muscles is sacrificed, either due to direct tumoral invasion or in order to achieve negative ontological margins. This situation needs to be addressed by the reconstructive surgeon in order to reconstruct the missing facial and intraoral soft tissue. Traditionally, soft tissue and facial nerve reconstruction are performed in 2 different stages. However, in the literature one-stage technique has been indicated to provide optimal results (60-63).

Urken *et al* (65) was the first to report a concurrent facial nerve reconstruction after extended radical parotidectomy with a vascularized radial nerve graft and radial free flap; the resulting soft-tissue defect after the ablative procedure was reconstructed with radial free flap and the radial nerve was used to bridge the defect of the facial nerve.

Teknos *et al* (66) reported, for the first time, the reconstruction of complex parotidectomy defects using lateral arm free tissue transfer, and in the case presented, the posterior cutaneous nerve of the forearm and the nerve to the lateral arm were used to reconstruct the facial nerve.

Primary facial nerve reanimation with simultaneous soft tissue reconstruction using a gracilis myocutaneous free

flap was first described by Lin *et al* (54). When there was no through-and-through defect, the cutaneous paddle of the gracilis free flap was used to restore the intraoral defect followed by inset of the other part of the muscular flap in order to restore the facial defect. When there was a through-and-through check resection, two free flaps were used to restore the ablative defect: The Anterolateral thigh, antero-medial thigh or fibula flap was used to restore the intramural defect and the cutaneous paddle of the gracilis free flap was used to rehabilitate the facial defect (54). The technique, as described by Lin *et al* (54), was performed as follows: A gracilis myocutaneous free flap was harvested in a conventional manner. After the tumour ablative procedure was done, the proximal part of the flap was inset between the modiolus and zygomatic arch (with interosseous wires). The inset was performed only after the optimal length and vector direction had been determined. The muscular part of the flap was used to fill either the retromolar or maxillary antrum dead space and the skin paddle segment of the flap was used either to reconstruct the intraoral mucosal defect or the facial skin wound. The coaptation between the obturator nerve and the proximal facial nerve stumps was performed together with the microvascular anastomosis to a branch of the internal jugular vein and a branch of the external carotid artery (54).

Revenaugh *et al* (67) described a method for single-stage reconstruction during radical parotidectomy with the use of anterolateral thigh fat and fascia flaps for facial contouring, orthodromic temporalis tendon transfer, cable grafting of the facial nerve and fascia lata lower lip suspension.

A similar approach was reported by Ch'ng *et al* (68). The procedure was a combination of the anterolateral thigh free flap and cervico-facial rotation advancement flap, repair of the facial nerve with the nerve to the vastus lateralis segmental interpositional graft, gold weight loading of the upper eyelid, lateral canthopexy, temporalis and digastric muscle transfers, and a delayed brow lift (68).

*Donor nerve graft selection.* Numerous sources of nervous tissue have been described for use in facial nerve reconstruction, such as the sural nerve, lateral antebrachial cutaneous nerve, medial antebrachial cutaneous nerve, the nerve to the vastus lateralis and the great auricular nerve. Both sensory and motor nerve may be used as nerve grafts in facial reanimation but there is evidence that motor nerve grafts may offer better results than sensory nerve grafts (69).

The great auricle nerve (10 cm) is a good option as a nerve graft, since both the donor site and recipient site are within the same surgical field. The only drawback it brings is the morbidity associated with the numbness of their lobe, which is a neglectable aspect in most of the patients (62,70). However, in parotid cancer, the great auricle nerve is not commonly used, since it is not uncommon that this nerve is invaded by the malignant neoplasm as well (71).

The sural nerve is one the most commonly used nerves as a cable graft due to its available length (40 cm) and its low morbidity, involving hypoesthesia on the lateral aspect of the foot (72).

Other nerve graft options are the medial antebrachial cutaneous nerve and lateral antebrachial cutaneous nerve of the upper arm (73). The mean length of this nerve graft is 15-20 cm and its branching is an important characteristic that fits distal stumps of the sectioned facial nerve. The most

important disadvantage to be taken into consideration is the risk of injury of the median nerve, brachial artery or basilica vein (74).

The superficial radial nerve may be a suitable option, particularly in those clinical situations where the radial forearm flap is used to reconstruct the soft tissue after ablative parotid surgery (75).

Thoracodorsal nerve graft used for facial nerve reconstruction was first described by White *et al* (76). The limitation of his article is that there was only one case described using thoracodorsal nerve graft. A more comprehensive study on this topic was published by Biglioli *et al* (77). The main advantages of the thoracodorsal nerve graft consist of the branching pattern, similar to the one of the facial nerve, which facilitates the coaptation between the distal stumps of the facial nerve and branches of the thoracodorsal nerve.

*Cranial nerve selection for transfer.* Selection of the cranial nerves for transfer requires thorough clinical judgment and a careful understanding of the balance between advantages and disadvantages of each donor site. The balance must be individualized for each case scenario, taking into account several variables, including the type of neural input that is necessary for an optimal reanimation (quantitative and qualitative), morbidity associated with the donor site, topographic characteristics of the donor nerve (fibre type, branching pattern, diameter and number of axons) and the necessity of a supplemental nerve graft (78).

Conventional donor nerves for transfer to reconstruct the facial nerve include the following: Masseteric branch of the V nerve, contralateral VII nerve with cross-face graft, the XI nerve and the XII nerve (78), which are described in detail below. Nerve coaptation may be achieved using suture, tissue glue, nerve wraps or a combination of these.

i) The masseteric nerve, branching from mandibular division of the trigeminal nerve (V), for nerve substitution was first described by Spira (79), who used it for the reinnervation of the lower division of the facial nerve. Since then, the use of the masseteric nerve for facial reanimation gradually evolved due its numerous advantages. From a surgical point of view, its location is a favourable characteristic, since the donor location is in the same surgical field as the recipient site (80). Related to the anatomical features, the masseteric nerve is quite similar in diameter to the trunk of the facial nerve and it provides >1,500-2,500 motor axons for coaptation (81,82). The morbidity associated with its harvest is low and acceptable in most patients, since the masseter muscle and temporalis muscle work in synergy and there is subsequent chewing dysfunction after nerve disruption. Since it is located close to the facial nerve divisions, in most cases, there is no need for an adjunctive nerve graft to bridge the masseteric to facial nerve. Even though the masseteric neural input is a quantitative one, it may produce an effortless smile without biting in most patients (83,84). This is due to the neuroplasticity of the brain, a mechanism in which new pathways are created between the trigeminal and facial nerve (85). Even though the provided tone is poor, masseteric division of the trigeminal nerve facilitates significant facial movements (61,62,64). It provides a reduced time for the reinnervation, ~5 months (range, 2-7 months) (86), varying based on the facial nerve branch reanimated (increased for the main trunk and shorter

for the zygomatic/buccal branches) and patient's age (faster in younger patients) (87).

ii) The hypoglossal nerve (XII) has been traditionally considered the 'gold standard' in facial reanimation using a nerve transfer procedure. The advantage provided by the use of this nerve in facial reanimation procedures is that it is relatively easy to dissect without the necessity to extend the conventional incision performed for reanimation. The nerve transfer was first described by Korte in 1901, but the morbidity associated with hypoglossal nerve transection in order to perform an end-to-end coaptation determined the modification of the surgical approach. In order to avoid permanent morbidity, a window is supposed to be created into the hypoglossal nerve and an end-to-side coaptation to be performed. This neurotomy procedure is facilitated by the high number of myelinated axons, between 9,200 and 12,594 myelinated axons (88-90). The neural input is a quantitative one, providing an optimal tone and movement. Even though the traditional procedure was classified as one with high morbidity related to tongue atrophy and deglutition disturbance, using 1/3 of the XII nerve has been accepted as an optimal alternative. By convention, it is necessary to use a nerve graft to bridge the VII nerve to the XII nerve. However, the vertical or mastoid segment of the facial nerve measures between 15 and 20 cm and mastoidectomy may facilitate the transposition of the facial nerve in order to avoid the necessity of an additional cable graft. Another drawback of using the XII nerve for facial transfer is the synkinesis complication that has a higher incidence in comparison to other nerve transfer sources.

iii) Contralateral facial nerve (VII) with cross-face graft: The facial nerve is composed of 6,000-7,000 myelinated motor fibers that innervate between 19 to 24 mimic muscles (91). Cross-face nerve grafting with the use of the sural nerve, as a cable nerve graft, was first described in 1971 by Scaramella, but the result was suboptimal (92,93). Harii *et al* (94) described a modification of the technique by performing the coaptation to a gracilis muscle in a secondary stage. The neural input is a truly qualitative one, providing an effortless, natural and spontaneous smile and blinking ability to the reanimated face (95). Conventionally, buccal or zygomatic branches of the contralateral facial nerve are selected to transfer the neurological signal to the affected side. The main disadvantages of this technique are the low power provided to the innervated mimetic muscles and the time required to neural input, with a mean reinnervation time of ~9 months. Statistically, only half of the axons reach the sural nerve extremity on the affected side of the face (51). Another drawback of the cross-face graft is that axons are required to pass 2 suture 'barriers' in order to reinnervate the mimetic muscles on the paralysis side. In order to facilitate a favourable outcome, the facial reanimation using cross-face nerve graft must be approached as an adjunctive procedure and not as a standalone one. A two-stage procedure is the preferred choice as it allows the axons to reach the extremity of the sural cable graft on the palsy side, and thereafter, the coaptation to the desired facial stumps is then performed, usually 12 months later (96). Since it is necessary to wait for a significant amount of time, in most cases, another nerve transfer will be performed in order to avoid the atrophy of the mimetic muscles ['babysitter' procedure described by

Terzis and Tzafetta (97), Biglioli *et al* (98) in 2012; 'triple innervation' concept described by Biglioli (64) in 2018].

iv) Accessory nerve (XI) transfer: The spinal nerve is a somatic nerve innervating both the trapezius and sternocleidomastoid (SCM) muscles. The average number of myelinated fibres may vary between 817 (at terminal end) to 1,328 axons (at the proximal end), according to a study published by Vathana *et al* (99). Traditionally, the spinal accessory nerve is not considered as a first-line option for nerve transfer in facial reanimation due to the significant morbidity that may result from its transection. An alternative to spinal nerve transection is to coat only branches that innervate the SCM muscle, and by doing so, the morbidity is significantly reduced. Thulin *et al* (100) reported 15 cases with no significant atrophy of the trapezius muscle. XI nerve transfer is an alternative neural source in cases in which masseteric or hypoglossal nerves are not available, or there is functionality impairment of speech or swallowing.

*Spinal nerve selection for transfer-phrenic nerve.* The phrenic nerve is a mixed nerve, originating from C3-C5, and is the only source for motor innervation of the diaphragm. The number of motor nerve fibres in the phrenic nerve is  $911 \pm 321$  to  $1,338 \pm 467$  (101). Phrenic nerves have been widely used in the reconstruction of brachial plexus injuries with a high success rate. The length, ease of dissection and relatively high number of motor fibres of the ipsilateral phrenic nerve make it possible to use it as a donor motor source for facial reanimation (102). According to Perret (103), unilateral transection of the phrenic nerve in individuals without any associated pulmonary disorders does not significantly affect the ventilating capacity. In the 23 cases with phrenico-facial coaptation performed at the University of Iowa by Perret (103), good symmetry was achieved in most of the patients, but the major reported drawbacks were sinkinetic facial movements with inspiration, coughing and laughing. Of note, Xu *et al* (102) reported 6 cases with facial reanimation performed with latissimus dorsi muscle free flaps and phrenic nerve transfer with no significant morbidity related to pulmonary ventilation in a single-stage approach.

## 8. Timing of facial nerve reanimation

The potential for recovery of any denervated muscle is highly dependent on the duration of denervation. The time passed from the moment of nerve functional disruption to the moment of nerve regeneration is an important aspect influencing the therapeutic outcome. The mimetic muscles must be reinnervated before muscular atrophy occurs. The decision-making process of whether to perform a certain technique or another for reanimation of a palsy face is directly dependent on the status of the muscular mimetic muscles. EMG is a preoperative prognostic tool and may determine whether mimetic muscles are still functional or a muscle-free flap transfer is necessary for dynamic reanimation. If muscle tension appears insufficient or there is a hype contraction at 6 months after the onset of contraction, the flap must be revised (77).

Another time-dependent aspect is neural degeneration. The physiopathologic mechanism involved is mainly explained by Wallerian degeneration. The lag between injury and axon degeneration is 24-48 h in young rats but it takes several days

for primate (including human) axons to degenerate (104). Motor nerves are more prone to being impacted by the timing of restoration in comparison to sensitive ones. Sarhane *et al* (85) made a solid point highlighting that delayed nerve repair has a greater deleterious effect on motor than sensory functional recovery. In a retrospective study, Ozmen *et al* (58) found that the most important variable influencing the final outcome is the time passed after facial paralysis onset. They concluded that 6 months is the cutoff point between cases showing an optimal outcome and those with a suboptimal result; however, no correlation between the size of the tumour and facial grafting outcome was found. Their results are supported by those of Zhang *et al* (105), who found that patients with complete paralysis who underwent facial nerve transfer 6 months after denervation achieved postoperative oral commissural excursion of 11.1 vs. 6.5 mm.

In long-standing facial paralysis cases, muscle transfer is the treatment of choice in order to achieve dynamic facial reanimation.

## 9. Strengths and limitations of the study

To the best of our knowledge, the present study provides the first bibliometric analysis on facial nerve reconstruction following radical parotidectomy.

The present bibliometric analysis focused on the recommendations and the new trends in facial reanimation after radical parotidectomy by examining the records from the Scopus database and did not include any complementary information from other databases. The Scopus database was chosen due to the fact that it is a more comprehensive database, reportedly having 20% unique material compared with Web of Sciences and covering the entire MEDLINE (PubMed) database (106). In addition, Scopus has built-in tools to analyze various bibliometric aspects such as published document by year, authors, territory, affiliation, subject area, funding sponsor, year and source. Also, the main databases allowing for direct analysis using VOSviewer software are Web of Science, Scopus and PubMed.

## 10. Conclusions

The present bibliometric analysis provides a basic worldwide analysis of the research publications on facial nerve reanimation in radical parotidectomy. The interest in the subject is continuously growing over the years, as facial nerve sacrifice is a debilitating condition with a dramatic impact on patients' quality of life.

So far, the United States is the main contributor in the field and the main research financial support was provided by the National Institute of Neurological Disorders and Stroke (USA), closely followed by the Japan Society for the Promotion of Science.

No consensus was found regarding the recommended surgical techniques for facial nerve reanimation, nor for the best timing for surgery, while most of the clinical experience suggests facial nerve restoration immediately after the ablative procedure.

The decision to perform immediate facial nerve grafting directly depends on numerous factors related to the general



health status of the individual, the underlying disease, the occupational activity, the existing anatomy and patient's wishes corroborated with the surgical team's recommendations and should take into consideration the fact that facial reanimation outcomes are not always predictable, may involve donor site morbidity and rely on of the complex nature of peripheral nerve regeneration and reinnervation.

Further research on preoperative prediction of the facial nerve status and the relation with the tumour in patients with parotid gland malignancy are mandatory for a conservative decision or immediate reconstruction.

### Acknowledgements

Not applicable.

### Funding

No funding was received.

### Availability of data and materials

Not applicable.

### Authors' contributions

Conceptualization: IF, CMC, SD and LC; methodology: IF, CMC, MS, FB; WOSviewer software: CMC and IF; validation: SD, IF and CMC; data curation: CMC, LC and SD; writing-original draft preparation: IF, FB, CMC; writing-review and editing: SD, IF and CMC; visualization: LC, SD, MS and FB; supervision: CMC. Data authentication is not applicable. All authors have read and agreed to the published version of the manuscript.

### Ethics approval and consent to participate

Not applicable.

### Patient consent for publication

Not applicable.

### Competing interests

The authors declare that they have no competing interests.

### References

- Skalova A and Hycza MD: Proceedings of the North American society of head and neck pathology companion meeting, new Orleans, LA, March 12, 2023: classification of salivary gland tumors: Remaining controversial issues? *Head Neck Pathol* 17: 285-291, 2023.
- Skálová A, Hycza MD and Leivo I: Update from the 5th edition of the World Health Organization classification of head and neck tumors: Salivary glands. *Head Neck Pathol* 16: 40-53, 2022.
- Speight PM and Barrett AW: Salivary gland tumours. *Oral Dis* 8: 229-240, 2002.
- Alsanie I, Rajab S, Cottom H, Adegun O, Agarwal R, Jay A, Graham L, James J, Barrett AW, van Heerden W, *et al*: Distribution and frequency of salivary gland tumours: An international multi-center study. *Head Neck Pathol* 16: 1043-1054, 2022.
- Rousseau A and Badoual C: Head and neck: Salivary gland tumors: An overview. *Atlas Genet Cytogenet Oncol Haematol* 15: 534-541, 2011.
- Dulguerov P, Marchal F and Lehmann W: Postparotidectomy facial nerve paralysis: Possible etiologic factors and results with routine facial nerve monitoring. *Laryngoscope* 109: 754-762, 1999.
- Lombardi D, McGurk M, Vander Poorten V, Guzzo M, Accorona R, Rampinelli V and Nicolai P: Surgical treatment of salivary malignant tumors. *Oral Oncol* 65: 102-113, 2017.
- David AP, Seth R and Knott PD: Facial reanimation and reconstruction of the radical parotidectomy. *Facial Plast Surg Clin North Am* 29: 405-414, 2021.
- Sánchez-Burgos R, Otero TG, Lassaletta L, Arias Gallo J, Cuellar IN and García MB: Facial nerve reconstruction following radical parotidectomy and subtotal petrosotomy for advanced malignant parotid neoplasms. *Ann Maxillofac Surg* 5: 203-207, 2015.
- Weng R, Lin DX, Song YK, Guo HW, Zhang WS, He XM, Li WC, Lin HH, He MC and Wei QS: Bibliometric and visualized analysis of research relating to minimally invasive spine surgery reported over the period 2000-2022. *Digit Heal* 9: 20552076231173562, 2023.
- Donthu N, Kumar S, Mukherjee D, Pandey N and Lim WM: How to conduct a bibliometric analysis: An overview and guidelines. *J Bus Res* 133: 285-296, 2021.
- Van Eck N and Waltman L: Software survey: VOSviewer, a computer program for bibliometric mapping. *Scientometrics* 84: 523-538, 2010.
- Park W, Park J, Park SI, Kim H, Bae H, Cho J, Won H, Park M and Jeong HS: Clinical outcomes and management of facial nerve in patients with parotid gland cancer and pretreatment facial weakness. *Oral Oncol* 89: 144-149, 2019.
- Spiro RH: Salivary neoplasms: Overview of a 35-year experience with 2,807 patients. *Head Neck Surg* 8: 177-184, 1986.
- Domenick NA and Johnson JT: Parotid tumor size predicts proximity to the facial nerve. *Laryngoscope* 121: 2366-2370, 2011.
- Preis M, Soudry E, Bachar G, Shufel H, Feinmesser R and Shpitzer T: Predicting facial nerve invasion by parotid gland carcinoma and outcome of facial reanimation. *Eur Arch Otorhinolaryngol* 267: 107-111, 2010.
- Bovenzi CD, Ciolek P, Crippen M, Curry JM, Krein H and Heffelfinger R: Reconstructive trends and complications following parotidectomy: Incidence and predictors in 11,057 cases. *J Otolaryngol Neck Surg* 48: 64, 2019.
- Lu GN, Villwock MR, Humphrey CD, Kriet JD and Bur AM: Analysis of facial reanimation procedures performed concurrently with total parotidectomy and facial nerve sacrifice. *JAMA Facial Plast Surg* 21: 50-55, 2019.
- Biglioli F: Facial reanimations: Part I-recent paralyses. *Br J Oral Maxillofac Surg* 53: 901-906, 2015.
- Huyett P, Duvvuri U, Ferris RL, Johnson JT, Schaitkin BM and Kim S: Perineural invasion in parotid gland malignancies. *Otolaryngol Head Neck Surg* 158: 1035-1041, 2018.
- House JW and Brackmann DE: Facial nerve grading system. *Otolaryngol Head Neck Surg* 93: 146-147, 1985.
- Chee GH and Nedzelski JM: Facial nerve grading systems. *Facial Plast Surg* 16: 315-324, 2000.
- Adour KK and Swanson PJ Jr: Facial paralysis in 403 consecutive patients: Emphasis on treatment response in patients with Bell's palsy. *Trans Am Acad Ophthalmol Otolaryngol* 75: 1284-1301, 1971.
- Yanagihara N: Grading of facial palsy. In: Fisch U (ed). *Proceedings of the third international symposium on facial nerve surgery*. Kugler Medical Publications, Zurich, pp533-535, 1976.
- Stennert E, Limberg CH and Frentrup KP: An index for paresis and defective healing-an easily applied method for objectively determining therapeutic results in facial paresis (author's transl). *HNO* 25: 238-245, 1977 (In German).
- Burres S and Fisch U: The comparison of facial grading systems. *Arch Otolaryngol Head Neck Surg* 112: 755-758, 1986.
- Zhai MY, Feng GD and Gao ZQ: Facial grading system: Physical and psychological impairments to be considered. *J Otol* 3: 61-67, 2008.
- Murty GE, Diver JP, Kelly PJ, O'Donoghue GM and Bradley PJ: The nottingham system: Objective assessment of facial nerve function in the clinic. *Otolaryngol Head Neck Surg* 110: 156-161, 1994.

29. ten Harkel TC, de Jong G, Marres HAM, Ingels KJAO, Spekniijder CM and Maal TJJ: Automatic grading of patients with a unilateral facial paralysis based on the sunnybrook facial grading system-A deep learning study based on a convolutional neural network. *Am J Otolaryngol* 44: 103810, 2023.
30. Neely JG, Cherian NG, Dickerson CB and Nedzelski JM: Sunnybrook facial grading system: Reliability and criteria for grading. *Laryngoscope* 120: 1038-1045, 2010.
31. el-Naggar M, Rice B and Oswal V: Life-size photograph transparencies: A method for the photographic detection and documentation of recovery from facial paralysis. *J Laryngol Otol* 109: 748-750, 1995.
32. Yuen K, Inokuchi I, Maeta M, Kawakami SI and Masuda Y: Evaluation of facial palsy by moiré topography index. *Otolaryngol Head Neck Surg* 117: 567-572, 1997.
33. Labecka MK and Plandowska M: Moiré topography as a screening and diagnostic tool-A systematic review. *PLoS One* 16: e0260858, 2021.
34. Banks CA, Bhama PK, Park J, Hadlock CR and Hadlock TA: Clinician-graded electronic facial paralysis assessment: The eFACE. *Plast Reconstr Surg* 136: 223e-230e, 2015.
35. Hadlock TA and Urban LS: Toward a universal, automated facial measurement tool in facial reanimation. *Arch Facial Plast Surg* 14: 277-282, 2012.
36. Ojha PT, Nagendra S, Ansari A, Kadam ND, Mathur A, Gopinathan N, Ojha N, Patel H, Bansode A, Kalel O, *et al*: Validation of a new graphic facial nerve grading system: FAME scale. *Ann Indian Acad Neurol* 25: 464-472, 2022.
37. Bendet E, Talmi YP and Kronenberg J: Preoperative electroneurography (ENoG) in parotid surgery: Assessment of facial nerve outcome and involvement by tumor-a preliminary study. *Head Neck* 20: 124-131, 1998.
38. Lee DH: Clinical efficacy of electroneurography in acute facial paralysis. *J Audiol Otol* 20: 8-12, 2016.
39. Wiertel-Krawczuk A, Huber J, Wojtyasiak M, Golusiński W, Pieńkowski P and Golusiński P: Correlations between the clinical, histological and neurophysiological examinations in patients before and after parotid gland tumor surgery: Verification of facial nerve transmission. *Eur Arch Otorhinolaryngol* 272: 1219-1229, 2015.
40. Aimoni C, Lombardi L, Gastaldo E, Stacchini M and Pastore A: Preoperative and postoperative electroneurographic facial nerve monitoring in patients with parotid tumors. *Arch Otolaryngol Head Neck Surg* 129: 940-943, 2003.
41. Gupta S, Mends F, Hagiwara M, Fatterpekar G and Roehm PC: Imaging the facial nerve: A contemporary review. *Radiol Res Pract* 2013: 248039, 2013.
42. Wegscheider H, Volk GF, Guntinas-Lichius O and Moriggl B: High-resolution ultrasonography of the normal extratemporal facial nerve. *Eur Arch Otorhinolaryngol* 275: 293-299, 2018.
43. Guntinas-Lichius O, Silver CE, Thielker J, Bernal-Sprekelsen M, Bradford CR, De Bree R, Kowalski LP, Olsen KD, Quer M, Rinaldo A, *et al*: Management of the facial nerve in parotid cancer: Preservation or resection and reconstruction. *Eur Arch Otorhinolaryngol* 275: 2615-2626, 2018.
44. Guenette JP, Ben-Shlomo N, Jayender J, Seethamraju RT, Kimbrell V, Tran NA, Huang RY, Kim CJ, Kass JI, Corrales CE and Lee TC: MR imaging of the extracranial facial nerve with the CISS sequence. *AJNR Am J Neuroradiol* 40: 1954-1959, 2019.
45. Takahashi N, Okamoto K, Ohkubo M and Kawana M: High-resolution magnetic resonance of the extracranial facial nerve and parotid duct: Demonstration of the branches of the intraparotid facial nerve and its relation to parotid tumours by MRI with a surface coil. *Clin Radiol* 60: 349-354, 2005.
46. Coulson SE, O'dwyer NJ, Adams RD and Croxson GR: Expression of emotion and quality of life after facial nerve paralysis. *Otol Neurotol* 25: 1014-1019, 2004.
47. Walker DT, Hallam MJ, Ni Mhurchadha S, McCabe P and Nduka C: The psychosocial impact of facial palsy: Our experience in one hundred and twenty six patients. *Clin Otolaryngol* 37: 474-477, 2012.
48. Ekman P: Basic emotions. *Handb Cogn Emot* 98: 16, 1999.
49. Guntinas-Lichius O, Straesser A and Streppel M: Quality of life after facial nerve repair. *Laryngoscope* 117: 421-426, 2007.
50. Park H, Kim DJ, Chung JH, Yoon ES and Park SH: Quantitative analysis of facial symmetry and animation following intra-oral orthodromic temporalis transfer in facial paralysis. *J Craniomaxillofac Surg* 51: 272-279, 2023.
51. Pinkiewicz M, Dorobisz K and Zatoński T: A comprehensive approach to facial reanimation: A systematic review. *J Clin Med* 11: 2890, 2022.
52. Subramaniam N, Luu E, Asher R, Oates J, Clark JR and Low TH: The impact of radical parotidectomy with immediate facial nerve reconstruction: A quality-of-life measure. *J Laryngol Otol* 135: 804-809, 2021.
53. Owusu JA, Truong L and Kim JC: Facial nerve reconstruction with concurrent masseteric nerve transfer and cable grafting. *JAMA Facial Plast Surg* 18: 335-339, 2016.
54. Lin CH, Wallace C and Liao CT: Functioning free gracilis myocutaneous flap transfer provides a reliable single-stage facial reconstruction and reanimation following tumor ablation. *Plast Reconstr Surg* 128: 687-696, 2011.
55. Wax MK and Kaylie DM: Does a positive neural margin affect outcome in facial nerve grafting? *Head Neck* 29: 546-549, 2007.
56. Volk GF, Pantel M, Streppel M and Guntinas-Lichius O: Reconstruction of complex peripheral facial nerve defects by a combined approach using facial nerve interpositional graft and hypoglossal-facial jump nerve suture. *Laryngoscope* 121: 2402-2405, 2011.
57. Osinga R, Buncke HJ, Buncke GM and Meuli-Simmen C: Subdivision of the sural nerve: Step towards individual facial reanimation. *J Plast Surg Hand Surg* 45: 3-7, 2011.
58. Ozmen OA, Falcioni M, Lauda L and Sanna M: Outcomes of facial nerve grafting in 155 cases: Predictive value of history and preoperative function. *Otol Neurotol* 32: 1341-1346, 2011.
59. Humphrey CD and Kriet JD: Nerve repair and cable grafting for facial paralysis. *Facial Plast Surg* 24: 170-176, 2008.
60. Tomita K, Hosokawa K and Yano K: Reanimation of reversible facial paralysis by the double innervation technique using an intraneural-dissected sural nerve graft. *J Plast Reconstr Aesthet Surg* 63: e535-e539, 2010.
61. Bianchi B, Ferri A and Sesenna E: Facial reanimation after nerve sacrifice in the treatment of head and neck cancer. *Curr Opin Otolaryngol Head Neck Surg* 20: 114-119, 2012.
62. Biglioli F, Frigerio A, Colombo V, Colletti G, Rabbiosi D, Mortini P, Dalla Toffola E, Lozza A and Brusati R: Masseteric-facial nerve anastomosis for early facial reanimation. *J Craniomaxillofac Surg* 40: 149-155, 2012.
63. Vincent AG, Bevans SE, Robitschek JM, Wind GG and Hohman MH: Masseteric-to-facial nerve transfer and selective neurectomy for rehabilitation of the synkinetic smile. *JAMA Facial Plast Surg* 21: 504-510, 2019.
64. Biglioli F, Allevi F, Rabbiosi D, Cupello S, Battista VMA, Saibene AM and Colletti G: Triple innervation for re-animation of recent facial paralysis. *J Craniomaxillofac Surg* 46: 851-857, 2018.
65. Urken ML, Weinberg H, Vickery C and Biller HF: The neurofaciocutaneous radial forearm flap in head and neck reconstruction: A preliminary report. *Laryngoscope* 100: 161-173, 1990.
66. Teknos TN, Nussenbaum B, Bradford CR, Prince ME, El-Kashlan H and Chepeha DB: Reconstruction of complex parotidectomy defects using the lateral arm free tissue transfer. *Otolaryngol Head Neck Surg* 129: 183-191, 2003.
67. Revenaugh PC, Knott PD, Scharpf J and Fritz MA: Simultaneous anterolateral thigh flap and temporalis tendon transfer to optimize facial form and function after radical parotidectomy. *Arch Facial Plast Surg* 14: 104-109, 2012.
68. Ch'ng S, Ashford BG, Gao K, McGuinness J and Clark JR: Reconstruction of post-radical parotidectomy defects. *Plast Reconstr Surg* 129: 275e-287e, 2012.
69. Jandali D and Revenaugh PC: Facial reanimation: An update on nerve transfers in facial paralysis. *Curr Opin Otolaryngol Head Neck Surg* 27: 231-236, 2019.
70. Biglioli F, D'Orto O, Bozzetti A and Brusati R: Function of the great auricular nerve following surgery for benign parotid disorders. *J Craniomaxillofac Surg* 30: 308-317, 2002.
71. Biglioli F, Colombo V, Pedrazzoli M, Frigerio A, Tarabbia F, Autelitano L and Rabbiosi D: Thoracodorsal nerve graft for reconstruction of facial nerve branching. *J Craniomaxillofac Surg* 42: e8-e14, 2014.
72. Lee MC, Kim DH, Jeon YR, Rah DK, Lew DH, Choi EC and Lee WJ: Functional outcomes of multiple sural nerve grafts for facial nerve defects after tumor-ablative surgery. *Arch Plast Surg* 42: 461-468, 2015.
73. Haller JR and Shelton C: Medial antebrachial cutaneous nerve: A new donor graft for repair of facial nerve defects at the skull base. *Laryngoscope* 107: 1048-1052, 1997.

74. Li H, Zhu W, Wu S, Wei Z and Yang S: Anatomical analysis of antebrachial cutaneous nerve distribution pattern and its clinical implications for sensory reconstruction. *PLoS One* 14: e0222335, 2019.
75. Vaughan ED and Richardson D: Facial nerve reconstruction following ablative parotid surgery. *Br J Oral Maxillofac Surg* 31: 274-280, 1993.
76. White WM, McKenna MJ and Deschler DG: Use of the thoracodorsal nerve for facial nerve grafting in the setting of pedicled latissimus dorsi reconstruction. *Otolaryngol Head Neck Surg* 135: 962-964, 2006.
77. Biglioli F, Frigerio A, Rabbiosi D and Brusati R: Single-stage facial reanimation in the surgical treatment of unilateral established facial paralysis. *Plast Reconstr Surg* 124: 124-133, 2009.
78. Klebuc M and Shenaq SM: Donor nerve selection in facial reanimation surgery. *Semin Plast Surg* 18: 53-60, 2004.
79. Spira M: Anastomosis of masseteric nerve to lower division of facial nerve for correction of lower facial paralysis. Preliminary report. *Plast Reconstr Surg* 61: 330-334, 1978.
80. Sakthivel P, Singh CA, Thakar A, Thirumeni G, Raveendran S and Sharma SC: Masseteric-facial nerve anastomosis: Surgical techniques and outcomes-A pilot Indian study. *Indian J Otolaryngol Head Neck Surg* 72: 92-97, 2020.
81. Coombs CJ, Ek EW, Wu T, Cleland H and Leung MK: Masseteric-facial nerve coaptation-an alternative technique for facial nerve reinnervation. *J Plast Reconstr Aesthet Surg* 62: 1580-1588, 2009.
82. Borschel GH, Kawamura DH, Kasukurthi R, Hunter DA, Zuker RM and Woo AS: The motor nerve to the masseter muscle: An anatomic and histomorphometric study to facilitate its use in facial reanimation. *J Plast Reconstr Aesthet Surg* 65: 363-366, 2012.
83. Manktelow RT, Tomat LR, Zuker RM and Chang M: Smile reconstruction in adults with free muscle transfer innervated by the masseter motor nerve: Effectiveness and cerebral adaptation. *Plast Reconstr Surg* 118: 885-899, 2006.
84. Klebuc MJA: Facial reanimation using the masseter-to-facial nerve transfer. *Plast Reconstr Surg* 127: 1909-1915, 2011.
85. Sarhane KA, Shappell H, Slavin B, von Guinneau N, Hanwright P, Borschel GH and Tuffaha SH: Abstract QS19: Elucidating the effects of delayed nerve repair on motor vs sensory functional recovery: A systematic review and meta-analysis. *Plast Reconstr Surg Glob Open* 7 (4 Suppl): S114-S115, 2019.
86. Murphey AW, Clinkscales WB and Oyer SL: Masseteric nerve transfer for facial nerve paralysis: A systematic review and meta-analysis. *JAMA Facial Plast Surg* 20: 104-110, 2018.
87. Wang W, Yang C, Li Q, Li W, Yang X and Zhang YX: Masseter-to-facial nerve transfer: A highly effective technique for facial reanimation after acoustic neuroma resection. *Ann Plast Surg* 73 (Suppl 1): S63-S69, 2014.
88. Tiago RSL, de Faria FP, de Lima Pontes PA and do Brasil O de OC: Morphometric aspects of the human hypoglossal nerve in adults and the elderly. *Braz J Otorhinolaryngol* 71: 554-558, 2005.
89. May M, Sobol SM and Mester SJ: Hypoglossal-facial nerve interpositional-jump graft for facial reanimation without tongue atrophy. *Otolaryngol Head Neck Surg* 104: 818-825, 1991.
90. Mackinnon SE and Dellon AL: Fascicular patterns of the hypoglossal nerve. *J Reconstr Microsurg* 11: 195-198, 1995.
91. Chuang DCC, Lu JCY, Chang TNJ and Laurence VG: Comparison of functional results after cross-face nerve graft-, spinal accessory nerve-, and masseter nerve-innervated gracilis for facial paralysis reconstruction: The chang gung experience. *Ann Plast Surg* 81 (6S Suppl 1): S21-S29, 2018.
92. Galli SKD, Valauri F and Komisar A: Facial reanimation by cross-facial nerve grafting: Report of five cases. *Ear Nose Throat J* 81: 25-29, 2002.
93. Kim IA, Maxim T and Echanique K: Modern cross-facial nerve grafting in facial paralysis. *Oper Tech Otolaryngol Neck Surg* 33: 20-28, 2022.
94. Harii K, Ohmori K and Torii S: Free gracilis muscle transplantation, with microneurovascular anastomoses for the treatment of facial paralysis. A preliminary report. *Plast Reconstr Surg* 57: 133-143, 1976.
95. Hontanilla B, Marre D and Cabello Á: Facial reanimation with gracilis muscle transfer neurotized to cross-facial nerve graft versus masseteric nerve: A comparative study using the FACIAL CLIMA evaluating system. *Plast Reconstr Surg* 131: 1241-1252, 2013.
96. Rodríguez-Lorenzo A and Tzou CHJ: Principles of facial nerve reconstruction. In: *Facial Palsy: Techniques for Reanimation of the Paralyzed Face*. Tzou CHJ and Rodríguez-Lorenzo A (eds.) Springer International Publishing, Cham, pp55-69, 2021.
97. Terzis JK and Tzafetta K: The 'babysitter' procedure: Mini-hypoglossal to facial nerve transfer and cross-facial nerve grafting. *Plast Reconstr Surg* 123: 865-876, 2009.
98. Biglioli F, Colombo V, Tarabbia F, Pedrazzoli M, Battista V, Giovanditto F, Dalla Toffola E, Lozza A and Frigerio A: Double innervation in free-flap surgery for long-standing facial paralysis. *J Plast Reconstr Aesthet Surg* 65: 1343-1349, 2012.
99. Vathana T, Larsen M, de Ruiter GCW, Bishop AT, Spinner RJ and Shin AY: An anatomic study of the spinal accessory nerve: Extended harvest permits direct nerve transfer to distal plexus targets. *Clin Anat* 20: 899-904, 2007.
100. Thulin CA, Petersen I and Granholm L: Follow-up study of spinal accessory-facial nerve anastomosis with special reference to the electromyographic findings. *J Neurol Neurosurg Psychiatry* 27: 502-506, 1964.
101. Wang C, Zhang Y, Nicholas T, Wu G, Shi S, Bo Y, Wang X, Zhou X and Yuan W: Neurotization of the phrenic nerve with accessory nerve for high cervical spinal cord injury with respiratory distress: An anatomic study. *Turk Neurosurg* 24: 478-483, 2014.
102. Xu YB, Liu J, Li P, Donelan MB, Parrett BM and Winograd JM: The phrenic nerve as a motor nerve donor for facial reanimation with the free latissimus dorsi muscle. *J Reconstr Microsurg* 25: 457-463, 2009.
103. Perret G: Results of phrenicofacial nerve anastomosis for facial paralysis. *Arch Surg* 94: 505-508, 1967.
104. Gaudet AD, Popovich PG and Ramer MS: Wallerian degeneration: Gaining perspective on inflammatory events after peripheral nerve injury. *J Neuroinflammation* 8: 110, 2011.
105. Zhang S, Hembd A, Ching CW, Tolley P and Rozen SM: Early masseter to facial nerve transfer may improve smile excursion in facial paralysis. *Plast Reconstr Surg Glob Open* 6: e2023, 2018.
106. Falagas ME, Pitsouni EI, Malietzis GA and Pappas G: Comparison of PubMed, scopus, web of science, and google scholar: Strengths and weaknesses. *FASEB J* 22: 338-342, 2008.



Copyright © 2023 Filipov et al. This work is licensed under a Creative Commons Attribution-NonCommercial-NoDerivatives 4.0 International (CC BY-NC-ND 4.0) License.