

Case Report

Large cerebellar mass lesion: A rare intracranial manifestation of blastomycosis

Stephan A. Munich, Andrew K. Johnson, Sumeet K. Ahuja, Alexander Venizelos¹, Richard W. ByrneDepartments of Neurosurgery, ¹Department of Neurology, Rush University Medical Center, Chicago, IL USAE-mail: *Stephan A. Munich - Stephan_Munich@Rush.edu; Andrew K. Johnson - Andrew_Johnson@Rush.edu; Sumeet K. Ahuja - Sumeet_K_Ahuja@Rush.edu; Alexander Venizelos - Alexander_Venizelos@Rush.edu; Richard W. Byrne - Richard_W_Byrne@Rush.edu

*Corresponding author

Received: 13 July 2013 Accepted: 08 September 2013 Published: 15 October 2013

This article may be cited as:Munich SA, Johnson AK, Ahuja SK, Venizelos A, Byrne RW. Large cerebellar mass lesion: A rare intracranial manifestation of blastomycosis. *Surg Neurol Int* 2013;4:141. Available FREE in open access from: <http://www.surgicalneurologyint.com/text.asp?2013/4/1/141/119882>

Copyright: © 2013, Munich SA. This is an open-access article distributed under the terms of the Creative Commons Attribution License, which permits unrestricted use, distribution, and reproduction in any medium, provided the original author and source are credited.

Abstract

Background: *Blastomyces dermatitidis* is a dimorphic fungus found endemically in the Mississippi and Ohio River basins and in the Midwestern and Canadian provinces that border the Great Lakes. Unlike other fungal infections, it most commonly affects immunocompetent hosts. Blastomycosis typically manifests as pulmonary infection, but may affect nearly any organ, including the skin, bone, and genitourinary system. Central nervous system (CNS) blastomycosis is rare, but potentially fatal manifestation of this disease. When it does occur, it most commonly presents as acute or chronic meningitis.

Case Description: We present a case of a patient who suffered intractable nausea and vomiting for several months before discovery of a large cerebellar blastomycoma causing mass effect and obstructive hydrocephalus. The enhancing lesion with unusual peripheral cystic structures is a unique radiographic appearance of CNS blastomycosis.

Conclusion: We review this patient's purely intraparenchymal manifestation of CNS blastomycosis and describe the unique imaging characteristics encountered.

Key Words: Blastomycosis, cerebellum, CNS blastomycosis, fungal infection

Access this article online**Website:**www.surgicalneurologyint.com**DOI:**

10.4103/2152-7806.119882

Quick Response Code:**INTRODUCTION**

Blastomyces dermatitidis is a thermally dimorphic fungus that exists in nature in the mycelial phase and converts to yeast at body temperature. It is endemic to several areas of North America, including the areas of the south-eastern and south-central United States bordering the Mississippi and Ohio river basins, Midwestern and Canadian provinces bordering the Great Lakes, and surrounding the Saint Lawrence river.^[2] Unlike many fungal infections, blastomycosis often affects immunocompetent individuals, especially those who engage frequently in activities outdoors.^[3] Lesions may be present in virtually

any organ, making clinical presentations highly variable and often nonspecific. Misdiagnosis is common, except in the setting of larger outbreaks.

Pulmonary disease is the most common manifestation of blastomycosis, often mimicking pneumonia in both symptomatology and radiographic appearance. Treatment of presumed pneumonia often leads to delays in identification of blastomycosis, which can be reliably diagnosed by isolation of the organism via bronchoscopy. Extra-pulmonary disease is most common in the skin, bones, and prostate. Cutaneous lesions are typically verrucous or ulcerative and aspiration of these lesions typically reveals the organism, allowing for diagnosis.

Osteomyelitis may occur in almost any bone, including the vertebrae, pelvis, sacrum, skull, and long bones. The organism is also found within these lesions. The most common genitourinary manifestation is prostatitis. The fungus may be present in urine following prostatic massage.^[2]

Central nervous system (CNS) disease occurs in 5-10% of patients with disseminated disease. Though there are rare reports of isolated CNS infection,^[6,11,18] most CNS disease occurs concomitant with disease at non-CNS sites. CNS involvement typically occurs in the form of acute or chronic meningoencephalitis; intracranial, spinal, and epidural mass lesions are less common.^[1,6,11,13] CSF findings of *Blastomyces dermatitidis* meningitis typically include pleocytosis with lymphocytic predominance and elevated protein.^[1] Isolation of the organism by India ink preparation or fungal culture from the CSF, especially when it is obtained via lumbar puncture, is uncommon.^[7,16] Therefore, isolation of the organism from the CNS often requires biopsy.

The patient presented here came to medical attention due to manifestations of his CNS disease, an enhancing cerebellar mass with surrounding cystic lesions. We present one of very few cases in the literature in which the intracranial lesion was purely intraparenchymal and without diffuse leptomeningeal enhancement. We observed unusual peripheral cystic structures surrounding an enhancing lesion, radiographic constellation not previously reported in association with CNS blastomycosis.

CASE REPORT

History and examination

The patient is a 63-year-old man with a history of non-Hodgkin's lymphoma 9 years prior; he had sustained remission after treatment with chemotherapy and radiation. He had presented with persistent nausea and vomiting for 2 months prior to his transfer to our institution. The patient underwent multiple gastrointestinal studies, which did not reveal a clear etiology of his symptoms. Routine chest X-ray demonstrated nonspecific left upper lobe opacities that were further evaluated with computed tomography (CT) and determined to be consistent with pneumonia. Head CT demonstrated a hypodense right cerebellar lesion that minimally enhanced with contrast [Figure 1a and b], prompting further investigation with magnetic resonance imaging (MRI). This revealed an enhancing right cerebellar mass with surrounding cystic lesions causing compression of the 4th ventricle and dorsal medulla resulting in obstructive hydrocephalus [Figure 2a-f].

Surgical intervention

The patient underwent a suboccipital craniotomy, finding an intradural lesion that was adherent to the surrounding

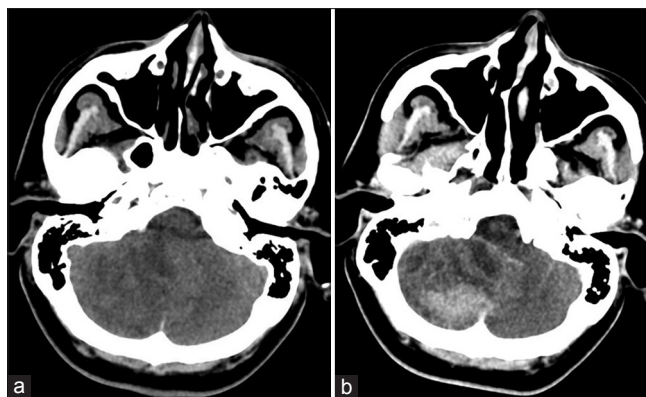


Figure 1: Noncontrast head CT (a) demonstrating an ill-defined hypodense lesion in the right cerebellar hemisphere causing compression of the 4th ventricle. Contrast-enhanced head CT (b) demonstrating an ill-defined, mildly enhancing right cerebellar lesion. The indistinct appearance of cystic structures can be appreciated surrounding the area of enhancement

meninges. Dissection around the lesion revealed a firm, avascular mass with surrounding cystic structures that were filled with yellow fluid. Gross total resection of the mass lesion and surrounding cystic structures was achieved.

Postoperative course

The patient recovered from surgery well and his nausea and vomiting slowly resolved. Pathology and microbiologic analysis revealed fungal elements and budding yeast consistent with blastomycosis [Figure 3a-c]. There was no evidence of CNS dissemination. The patient was started on antifungal therapy with amphotericin B. He was able to tolerate 1 week of amphotericin B before he developed acute hepatitis, prompting its discontinuation. At that time, he was switched to voriconazole. Treatment with voriconazole was planned to last for 1 year.

At last follow up, the patient had mild ataxia. His MRI performed 1 month after surgery demonstrated expected postoperative changes and improvement in ventricular dilation seen preoperatively; there was no evidence of recurrent infection [Figure 4].

DISCUSSION

CNS disease is rare manifestation of blastomycosis, occurring in 5-10% of those with disseminated disease. When it does occur, it is typically in the form of meningoencephalitis. Intraparenchymal lesions are rare and are thought to be due to hematogenous spread of the organism from the lungs.^[16] However, intracranial blastomycosis may be more common in the epidural space as a consequence of extension from osteomyelitis of the skull. Indeed, in their review of surgical indication for CNS blastomycosis, Ward *et al.* described intraoperative findings of epidural abscesses and empyemas in the region of underlying lytic skull lesions.^[17]

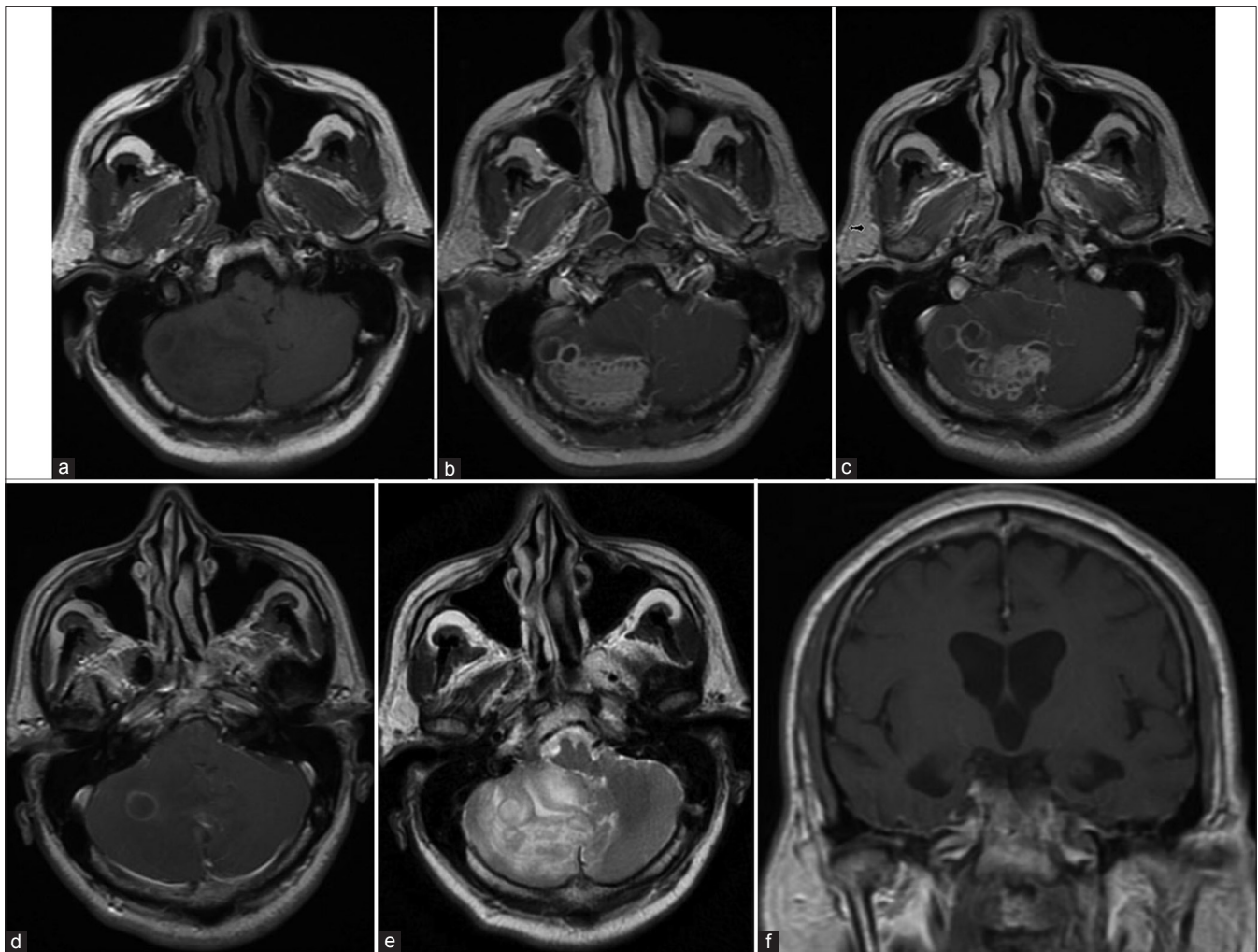


Figure 2: Noncontrast brain MRI (a) demonstrating an indistinct, heterogeneous lesion in the right cerebellar hemisphere causing mass effect and compression of the 4th ventricle. A cystic component can be seen laterally. Contrast-enhanced T1-weighted MRI (b-d) demonstrating a strongly enhancing lesion in the right cerebellar hemisphere. Innumerable, peripherally enhancing cystic structures are seen mostly surrounding, but also within, the area of enhancement. T2-weighted MRI (e) demonstrating diffuse hyperintensity within and surrounding the lesion. Contrast-enhanced T1-weighted MRI (f) demonstrating evidence of obstructive hydrocephalus with marked dilation of the lateral and third ventricles

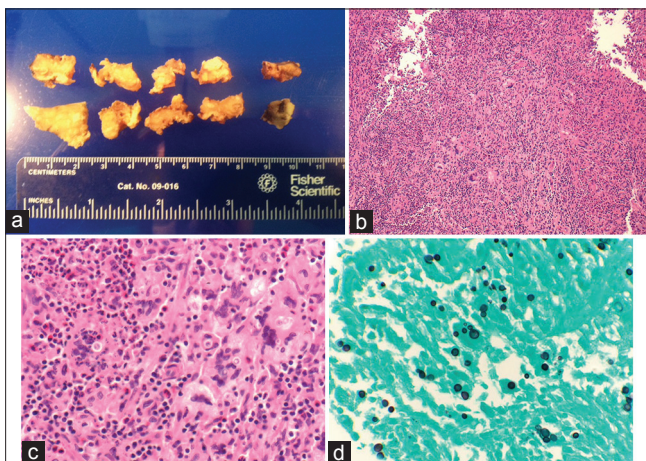


Figure 3: Gross specimen of the right cerebellar lesion (a) corresponding to the enhancing portion seen in Figure 2b-d. Hematoxylin and eosin preparation (b-c) demonstrating granulomatous inflammation with yeast-like organisms. Grocott's methenamine silver preparation (d) demonstrating budding spores

Like the symptoms of non-CNS blastomycosis, those of CNS disease are also nonspecific. Bariola *et al.* provided the most robust review of a series of patients with CNS blastomycosis.^[1] In their retrospective, multicenter review of 22 patients, they found headache to be the most common neurologic symptom, present in 86% of patients. Other common complaints included focal neurologic deficit, altered mental status, visual disturbance, and seizures. Our patient presented with months of intractable nausea and vomiting, attributable to the lesion's mass effect on the floor of the 4th ventricle and resultant obstructive hydrocephalus.

The imaging characteristics of CNS blastomycosis are variable and ill defined, ranging from diffuse leptomeningeal enhancement to innumerable punctate lesions to discrete mass lesions.^[15] CT findings are nonspecific, thus, MRI is considered the imaging modality of choice for CNS blastomycosis. Bariola *et al.*

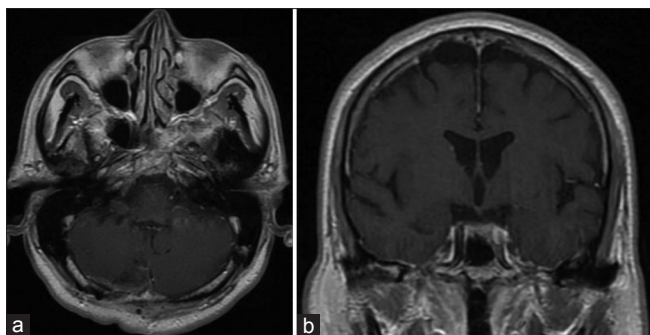


Figure 4: Contrast-enhanced T1-weighted MRI performed 1 month after the patient's operation. There is no evidence of the cystic lesions seen in Figure 2. There is resolution of the patient's obstructive hydrocephalus (b)

reported one case in which a patient had normal CT findings, but diffuse leptomeningeal enhancement with a basal ganglia lesion on MRI.^[1] When discrete lesions are present, their appearance is often nonspecific. On MRI, the lesions typically demonstrate marked, often homogenous, enhancement.^[8,14] Wylene *et al.* reported a case of a strongly enhancing, dural-based plaque.^[19] Kale *et al.* reported a case of a homogeneously enhancing prepontine mass, appearing to arise from a dural-based plaque.^[9] Similarly, Chander *et al.* reported a case of a large homogeneously enhancing mass appearing to arise from the anterior cranial floor.^[4] In these cases, minimal surrounding edema, the homogeneous enhancement pattern and the lesions' proximity to the meninges were highly suggestive of meningioma.

Our patient's MRI was unique in that, although part of the lesion demonstrated enhancement, there were innumerable peripheral cystic lesions. Both the enhancing and cystic portions were located solely within the brain parenchyma. There was no evidence of extradural disease and no evidence of a lytic skull lesion; this was reminiscent of neoplasm and suggested a discrete intraparenchymal lesion rather than extension from adjacent locations. Marked edema with effacement of the 4th ventricle was also present. Due to the unusual peripheral cystic structures observed in our patient, meningioma seemed unlikely. These cystic structures have not been described in association with CNS blastomycosis. Rather, the MRI findings closely resembled those seen in racemose neurocysticercosis as reported by Kim *et al.*,^[10] which was considered as a potential diagnosis in our patient.

Antifungal agents are the primary treatment for systemic blastomycosis, as well as CNS disease without discrete lesions. In 2008, the Infectious Disease Society of America published guidelines for the treatment of blastomycosis.^[5] For CNS blastomycosis, they recommend lipid amphotericin B 3-5 mg/kg per day for 1-2 weeks followed by itraconazole 200 mg BID for 12 months. Recently, voriconazole has been favored in place of itraconazole due to increased CNS penetration.^[12]

Surgical resection is integral to the treatment of CNS mass lesions, providing relief of mass effect, as well as definitive diagnosis. Ward *et al.* described three indications for surgical management: (1) mass lesions causing neurologic deficit, (2) lesions of uncertain etiology, and (3) osteomyelitis of the skull and spine.^[17] In these cases, antifungal therapy remains mandatory following surgical treatment.

CONCLUSION

CNS blastomycosis may affect 5-10% of patient with systemic blastomycosis and most commonly presents in the setting of non-CNS disease. Both systemic and neurologic symptoms are highly variable and nonspecific. Although most often presenting as meningitis, intracranial and intraspinal mass lesions may occur. The imaging characteristics of intracranial lesions are highly variable. Though rare, this case highlights that intraparenchymal lesions may occur by themselves, without evidence of leptomeningeal enhancement or extradural disease. Surgical resection followed by prolonged antifungal therapy is the mainstay of treatment in patients presenting with intracranial mass lesions.

REFERENCES

- Bariola JR, Perry P, Pappas PG, Proia L, Shealey W, Wright PW, *et al.* Blastomycosis of the central nervous system: A multicenter review of diagnosis and treatment in the modern era. *Clin Infect Dis* 2010;50:797-804.
- Bradsher RW, Chapman SW, Pappas PG. Blastomycosis. *Infect Dis Clin North Am* 2003;17:21-40.
- Buechner HA, Clawson CM. Blastomycosis of the central nervous system. II. A report of nine cases from the Veterans Administration Cooperative Study. *Am Rev Respir Dis* 1967;95:820-6.
- Chander B, Deb P, Sarkar C, Garg A, Mehta VS, Sharma MC. Cerebral blastomycosis: A case report. *Indian J Pathol Microbiol* 2007;50:821-4.
- Chapman SW, Dismukes WE, Proia LA, Bradsher RW, Pappas PG, Threlkeld MG, *et al.* Clinical practice guidelines for the management of blastomycosis: 2008 update by the Infectious Diseases Society of America. *Clin Infect Dis* 2008;46:1801-12.
- Friedman JA, Wijdicks EF, Fulgham JR, Wright AJ. Meningoencephalitis due to *Blastomyces dermatitidis*: Case report and literature review. *Mayo Clin Proc* 2000;75:403-8.
- Gonyea EF. The spectrum of primary blastomycotic meningitis: A review of central nervous system blastomycosis. *Ann Neurol* 1978;3:26-39.
- Jain KK, Mittal SK, Kumar S, Gupta RK. Imaging features of central nervous system fungal infections. *Neurol India* 2007;55:241-50.
- Kale H, Narlawar R, Maheswari S, Desai S, Kohli A. CNS blastomycosis, mimic of meningioma. *Indian J Radiol Imaging* 2002;12:483-4.
- Kim SW, Kim MK, Oh SM, Park SH. Racemose cysticercosis in the cerebellar hemisphere. *J Korean Neurosurg Soc* 2010;48:59-61.
- Kravitz GR, Davies SF, Eckman MR, Sarosi GA. Chronic blastomycotic meningitis. *Am J Med* 1981;71:501-5.
- Lutsar I, Roffey S, Troke P. Voriconazole concentrations in the cerebrospinal fluid and brain tissue of guinea pigs and immunocompromised patients. *Clin Infect Dis* 2003;37:728-32.
- Morgan D, Young RF, Chow AW, Mehringer CM, Itabashi H. Recurrent intracerebral blastomycotic granuloma: Diagnosis and treatment. *Neurosurgery* 1979;4:319-24.
- Ostrow TD, Hudgins PA. Magnetic resonance imaging of intracranial fungal infections. *Top Magn Reson Imaging* 1994;6:22-31.
- Szedler V, Ortega-Gutierrez S, Frank M, Jaradeh SS. CNS blastomycosis in a young man working in fields after Hurricane Katrina. *Neurology* 2007;68:1746-7.

16. Treseler CB, Sugar AM. Fungal meningitis. *Infect Dis Clin North Am* 1990;4:789-808.
17. Ward BA, Parent AD, Raila F. Indications for the surgical management of central nervous system blastomycosis. *Surg Neurol* 1995;43:379-88.
18. Wolfe JW. Responses of the cerebellar auditory area to pure tone stimuli. *Exp Neurol* 1972;36:295-309.
19. Wylen EL, Nanda A. Blastomyces dermatitidis occurring as an isolated cerebellar mass. *Neurosurg Rev* 1999;22:152-4.

Disclaimer: The authors of this article have no conflicts of interest to disclose, and have adhered to *SNI*'s policies regarding human/animal rights, and informed consent. Advertisers in *SNI* did not ask for, nor did they receive access to this article prior to publication.