



Contents lists available at ScienceDirect

International Journal of Surgery Case Reports

journal homepage: www.casereports.com

Avoiding the pocket: A case report of coiling of distal shunt catheter into subcutaneous pocket

Richard Justin Garling^{a,*}, Sandeep Sood^{a,b}, Carolyn Anne Harris^{a,c}^a Wayne State University Department of Neurosurgery, 4201 St. Antoine blvd, Suite 6E, Detroit, MI 48201, United States^b Children's Hospital of Michigan Department of Neurosurgery, Detroit, MI, United States^c Wayne State University Department of Biomedical Engineering, Detroit, MI, United States

ARTICLE INFO

Article history:

Received 25 August 2017

Accepted 30 September 2017

Available online 10 October 2017

Keywords:

Distal shunt malfunction

Coiled shunt

Hydrocephalus

ABSTRACT

INTRODUCTION: Hydrocephalus is one of the most common disorders of neurosurgery and ventricular shunting, the primary surgical intervention, malfunctions in 85% of patients by 10 years.

PRESENTATION OF CASE: Here we present a case of a 12-year-old girl with history of a vagal nerve stimulator (VNS) and ventricular shunt, most recently revised from ventriculoatrial (VA) to ventriculoperitoneal (VP) shunt at an outside hospital. The patient presented with a new left chest bulge, nausea, emesis, and seizures. Imaging revealed the patient's distal shunt catheter to have completely migrated and coiled into the VNS subcutaneous pocket. Subsequently, the patient's distal shunt catheter was externalized, and later internalized back to a VA shunt.

DISCUSSION: Potential spaces from previous surgeries such as VNS can lead to coiling of distal shunt catheters. In this case, the coiled distal shunt catheter led to hydrocephalus and the patient's presenting symptoms.

CONCLUSION: It is imperative to recognize patients with previous surgeries, especially those involving subcutaneous implants and to avoid passing of distal shunt catheters through these potential spaces.

© 2017 The Authors. Published by Elsevier Ltd on behalf of IJS Publishing Group Ltd. This is an open access article under the CC BY-NC-ND license (<http://creativecommons.org/licenses/by-nc-nd/4.0/>).

1. Introduction

Hydrocephalus is one of the most common disorders of neurosurgery and placement of a shunt catheter for diversion of cerebrospinal fluid (CSF) is the primary treatment. Shunt malfunction is a frequent complication in neurosurgery, occurring in approximately 85% of patients by 10 years [1]. Ventricular shunts most commonly divert CSF to the abdomen, atrium of the heart, or pleural space. Distal catheter migration has been shown in the literature to occur in the subcutaneous tissue space of the abdomen, thorax, neck, and even into the subgaleal space [2–10]. We present a case of a patient with history of vagal nerve stimulation (VNS) who presented with shunt malfunction and seizures in which the distal shunt catheter became completely coiled into the VNS subcutaneous pocket. This work has been reported in line with the SCARE criteria [11].

2. Case presentation

This is a 12-year-old girl who presented with new left chest bulge, nausea, and emesis. The patient had a history of staring spells

and grand mal seizures for which she was treated with VNS, with resolution of her seizures. The patient also had a history of congenital hydrocephalus requiring multiple shunt revisions with the most recent shunt being converted from a VA to VP shunt at an outside hospital two months prior to this presentation. Per the mother of the patient, the family was on a long road trip when the child was noted to be progressively more tired and nauseated with emesis. The mother then noticed an enlarged area on the patient's left chest which she believed to be secondary to migration of the VNS battery. Further, the mother stated that the patient had several seizure episodes on this road trip though she had not had a seizure in years since the VNS was placed. On physical examination, the child was lethargic but alert, following commands, and full strength but visibly nauseated. The child complained of headache, nausea, but denied blurry vision.

3. Investigations

A chest x-ray (Figs. 1 and 3) was initially performed in the emergency room due to the chief complaint of the mother being new left chest bulge. This quickly revealed complete migration of the distal shunt catheter into the VNS subcutaneous pocket. Next, a computed tomography (CT) of the head without contrast and a shunt series consisting of anterior/posterior (AP) and lateral skull x-rays and abdominal x-rays were ordered. CT Head revealed hydrocephalus

* Corresponding author.

E-mail address: jgarling@med.wayne.edu (R.J. Garling).

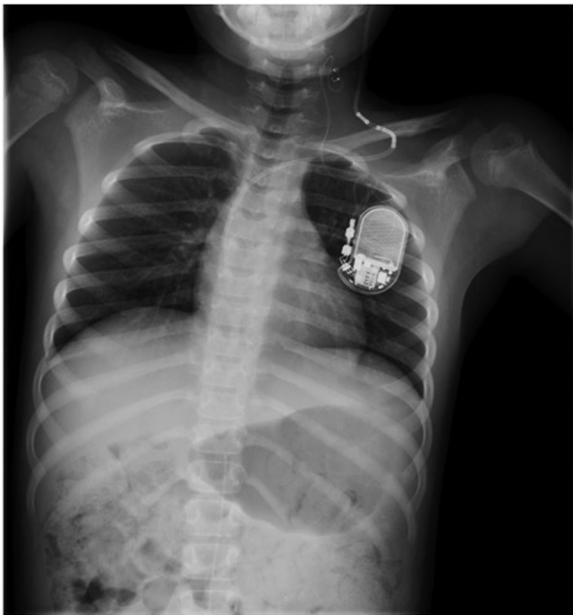


Fig. 1. Chest x-ray from 4 years prior to presentation. Shunt tubing noted to be going into the right atrium.

compared to the most recent CT head in the medical record (Fig. 3). The skull x-rays did not show any signs of catheter disconnection or fracturing and the abdominal x-ray did not show retained catheter fragments.

4. Treatment

The patient was consented and taken for externalization of the VP shunt. The VNS was interrogated the following morning and found to be functioning appropriately. Previously, the patient's shunt was changed from VP to VA shunt at our center secondary to adhesions that had developed due to the patient's multiple shunt revisions. Ultrasound of the left subclavian vein was obtained for pre-operative planning, and the patient was taken the next day for internalization of the shunt. During the surgery it was first attempted to tunnel the catheter around the VNS subcutaneous pocket to the patient's recent peritoneal site. However, upon feeding the catheter into the peritoneum the catheter immediately met

resistance and backed out. Repositioning the catheter trajectory did not improve the length of catheter that was able to be placed. The catheter was then backed out and tunneled to the left subclavian where the catheter was easily tunneled in the left subclavian vein. The patient tolerated the procedure well and at three months post-operation has not required a revision to our knowledge.

5. Discussion

Shunt migration is not an uncommon cause of shunt malfunction. Subcutaneous coiling of the distal catheter may occur in any region of the body where there is a potential space. Most shunt migrations occur in the first three months post op [3,12]. Theories for why these shunt migrations occur include pressure gradient between ventricular space and peritoneum, windlass effect from flexion and extension at the neck, non linear tortuous course of the catheter, and intrinsic memory of the catheter material [3,7,8]. In this case, tunneling of the distal catheter through the VNS subcutaneous pocket in the left chest was partially responsible for the malfunction. In addition, the patient's history of abdominal adhesions likely contributed to the migration of the distal catheter out of the peritoneum and into the subcutaneous pocket. The migration of the catheter out of the peritoneum probably occurred slowly over the two months since her last shunt revision. Perhaps the patient did not become symptomatic immediately following distal catheter dislodgement from the peritoneum because the cerebrospinal fluid (CSF) was able to freely pass into the peritoneum via the tunneled tract; conceivably small volumes were absorbed in the subcutaneous pocket. Once the distal catheter was completely coiled in the VNS subcutaneous space the path of least resistance for CSF flow was no longer into the peritoneum but proximally; leading to hydrocephalus and the patient's presenting symptoms of nausea, emesis, and seizures.

6. Conclusion

- Recognize patients with previous surgeries, especially those involving subcutaneous implants.
- Distal shunt catheters must be passed around potential spaces to avoid coiling leading to shunt malfunction.
- Note that if a peritoneal catheter does not pass easily a different approach should be considered.

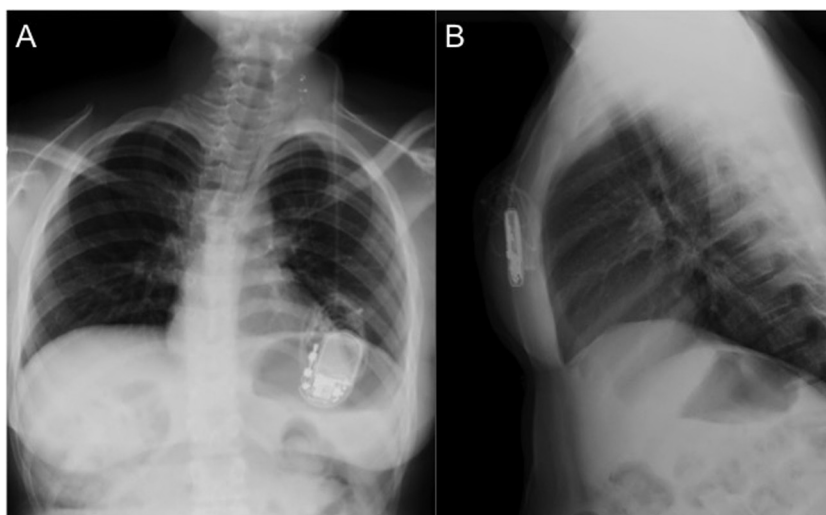


Fig. 2. AP (A) and Lateral (B) chest x-ray performed on presentation showing migration of the VP shunt catheter into the VNS subcutaneous pocket.

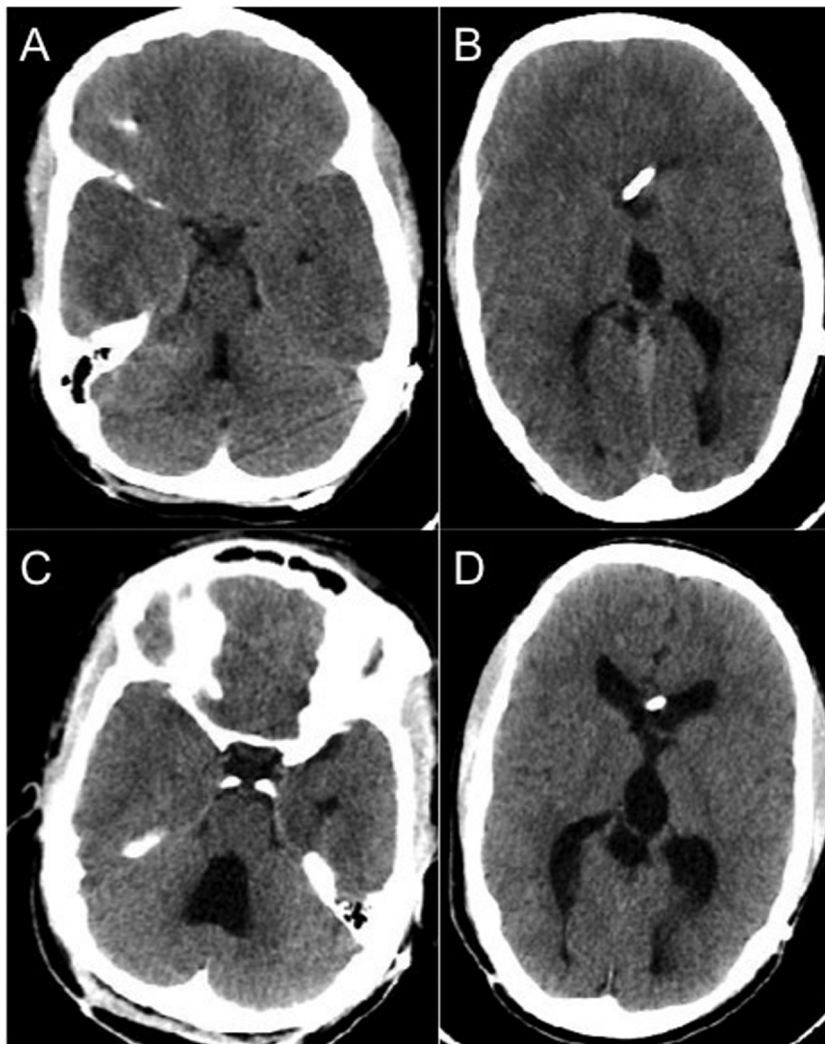


Fig. 3. Previous CT Head without contrast from four years prior to presentation (A, B). CT Head without contrast at presentation showing hydrocephalus (C, D).

Conflict of interest

None.

Sources of funding

No funding to disclose.

Ethical approval

Completed in compliance with Wayne State University IRB.

Consent

Consent was obtained from the mother of the patient for writing of case report and available upon request.

Author contribution

Richard Justin Garling: design, data collection, writing of paper.
Sandeep Sood: writing of paper, critical review of paper.
Carolyn A. Harris: writing of paper, critical review of paper.

Guarantor

Richard Justin Garling.
Sandeep Sood.
Carolyn A. Harris.

References

- [1] Y. Enchev, S. Oi, Historical trends of neuroendoscopic surgical techniques in the treatment of hydrocephalus, *Neurosurg. Rev.* 31 (3) (2008) 249–262.
- [2] J.F. Martínez-Lage, M. Poza, V. Izura, Retrograde migration of the abdominal catheter as a complication of ventriculoperitoneal shunts: the fishhook sign, *Childs Nerv. Syst.* 9 (7) (1993) 425–427.
- [3] A. Agarwal, A. Kakani, Shunt malfunction due to proximal migration and subcutaneous coiling of a peritoneal catheter, *J. Neurosci. Rural Pract.* 1 (2) (2010) 120–121.
- [4] D. Curri, C. Bollini, C. Carbonin, et al., Rare complication in the surgical therapy of hydrocephalus with ventriculo-peritoneal shunt, *J. Neurosurg. Sci.* 18 (3) (1974) 206–209.
- [5] R.C. Heim, B.A. Kaufman, T.S. Park, Complete migration of peritoneal shunt tubing to the scalp, *Childs Nerv. Syst.* 10 (6) (1994) 399–400.
- [6] M.J. Joubert, S. Stephanov, Extrusion of peritoneal catheter through the mid-lumbar region: an unusual complication of ventriculo-peritoneal shunt, *Surg. Neurol.* 19 (2) (1983) 120–121.
- [7] K.J. Kim, K.C. Wang, B.K. Cho, Proximal migration and subcutaneous coiling of a peritoneal catheter: report of two cases, *Childs Nerv. Syst.* 11 (7) (1995) 428–431.
- [8] D. Pang, J.E. Wilberger, Upward migration of peritoneal tubing, *Surg. Neurol.* 14 (5) (1980) 363–364.

- [9] S. Prabhu, W. Cochran, A.F. Azmy, Wandering distal ends of ventriculo-peritoneal shunts, *Z. Kinderchir.* 40 (2) (1985) 80–81.
- [10] N.G. Thaker, A. Mammis, D.S. Yanni, et al., Distal subgaleal-peritoneal shunt migration into the abdominal wall with subsequent formation of a pre-peritoneal pseudocyst: a rare complication, *J. Surg. Case Rep.* 2010 (7) (2010) 9.
- [11] R.A. Agha, A.J. Fowler, A. Saeta, et al., The SCARE statement: consensus-based surgical case report guidelines, *Int. J. Surg.* 34 (2016) 180–186.
- [12] S.R. Browd, B.T. Ragel, O.N. Gottfried, et al., Failure of cerebrospinal fluid shunts: part I: obstruction and mechanical failure, *Pediatr. Neurol.* 34 (2) (2006) 83–92.

Open Access

This article is published Open Access at sciedirect.com. It is distributed under the [IJSCR Supplemental terms and conditions](#), which permits unrestricted non commercial use, distribution, and reproduction in any medium, provided the original authors and source are credited.