

Intracavitary course of right coronary artery

Dear Sir,

This is in context to a case report published in the Feb 2011 issue of the *Indian Journal of Radiology and Imaging* titled, "Case Report: Intra-atrial course of right coronary artery: Evaluation by dual-source CT" by Johann Christopher and Chary Duraikannu.^[1]

We too have encountered two similar cases. Both patients showed a right dominant circulation with normal origins of the left main (LM) artery and right coronary artery (RCA). The proximal RCA had a normal epicardial course between the pulmonary trunk and the right atrial appendage in both the patients. The segment 3 (modified AHA 17-segment model) of the RCA in one patient [Figure 1] and segment 2 in another patient [Figure 2] were seen to tunnel into the right atrium and continue their intracavitary course for lengths of 1.32 and 1.56 cm, respectively, before continuing their

normal epicardial course and dividing into the posterior descending and posterolateral ventricular branches. The rest of the coronary arteries were normal.

Such cases are now being diagnosed with increasing frequency owing to the widespread use of coronary computed tomography angiography and its ability to simultaneously visualize the coronary arteries, cardiac chambers, and the surrounding soft tissues.^[2,3] The pick-up rate of this particular anomaly is bound to increase in the years to come.

Abhishek Bansal, Maria M D'souza¹,
Rajendra P Tripathi

Department of Radiological Imaging, ¹Division of PET Imaging, Institute of Nuclear Medicine and Allied Sciences, Delhi – 110 054, India.

E-mail: abhishek_mamc@yahoo.co.in

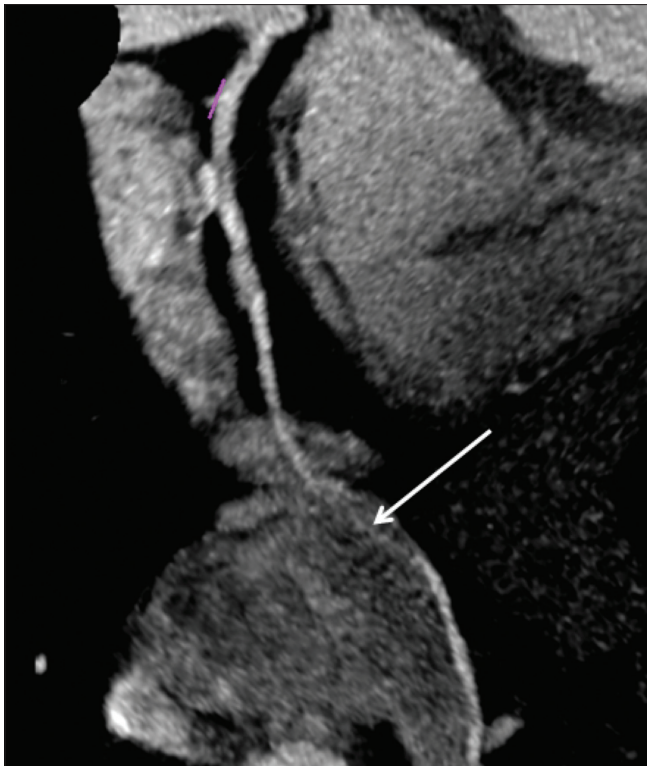

Figure 1: Maximum intensity projection (MIP) image shows intracavitary course of segment 3 (arrow) of the RCA

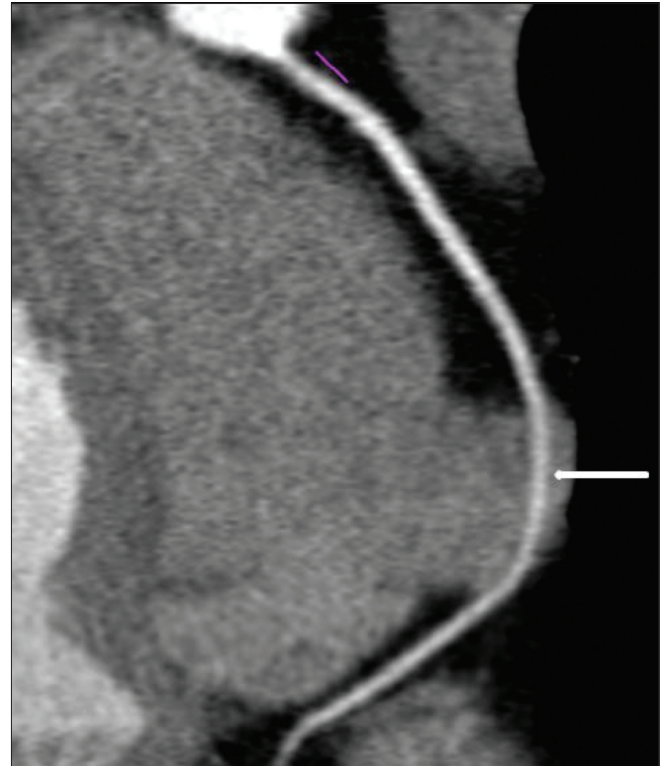


Figure 2: Maximum intensity projection (MIP) image shows intracavitary course of segment 2 (arrow) of the RCA

References

1. Christopher J, Duraikannu C. Case report: Intra-atrial course of right coronary artery: Evaluation by dual-source CT. Indian J Radiol Imaging 2011;21:57-9.
2. Renapurkar R, Desai M, Curtin RJ. Intracavitary course of the right coronary artery: An increasingly recognized anomaly by coronary computed tomography angiography. J Thorac Imaging 2010;25:W77-8.
3. Lee YS, Bastarrika G, Schoepf UJ. Intra-atrial course of the right coronary artery demonstrated at computed tomography coronary

angiography. J Thorac Imaging 2010;25:W115-7.

Access this article online	
Quick Response Code:	Website: www.ijri.org
	DOI: 10.4103/0971-3026.85378