

Late-Onset Hematoma Due to Bleeding of a Small Branch of the Lateral Circumflex Femoral Artery Following Proximal Femur Intramedullary Nailing

Review began 03/20/2022

Review ended 03/24/2022

Published 03/26/2022

© Copyright 2022

Papaioannou et al. This is an open access article distributed under the terms of the Creative Commons Attribution License CC-BY 4.0., which permits unrestricted use, distribution, and reproduction in any medium, provided the original author and source are credited.

Ioannis Papaioannou¹, Georgia Pantazidou², Thomas Repantis¹, Vasileios K. Mousafeiris¹, Nektaria Kalyva³

1. Orthopedics, General Hospital of Patras, Patras, GRC 2. Otolaryngology - Head and Neck Surgery, General Hospital of Patras, Patras, GRC 3. Pediatrics, University Hospital of Patras, Patras, GRC

Corresponding author: Ioannis Papaioannou, john.pane1984@gmail.com

Abstract

Intramedullary nailing of proximal femur fracture is not deprived of complications, although vascular complications are very rare and a high index of suspicion is required for timely diagnosis. This case report describes how a late-onset hematoma formation and bleeding of a small branch of the lateral circumflex femoral artery can complicate intramedullary nailing after a pertrochanteric fracture. To the best of our knowledge, this complication has never been reported and should be considered among the possible vascular complications of intramedullary nailing. Orthopedic surgeons should be aware of the vascular complications that can occur even with late-onset presentation and even from small vessels, while administration of anticoagulants is an aggravating factor. Elderly patients with proximal femur fractures are more susceptible to vascular injury due to the structure of their vessels and the vicinity of the fracture to the arterial supply of the hip.

Categories: Orthopedics

Keywords: anticoagulants, bleeding, intramedullary locked nail, lateral circumflex femoral artery, hematoma

Introduction

Fragility hip fracture is the most common orthopedic injury among elderly patients and represents a huge public health issue with significant socioeconomic impact [1]. Surgical treatment of trochanteric hip fractures includes extramedullary implants, intramedullary nails, and arthroplasty. During the last 15 years, intramedullary nailing gained popularity among orthopedic surgeons and became the implant of choice for the majority of extracapsular hip fractures [2]. Intramedullary nailing is not deprived of complications, although vascular complications are very rare and require a high index of suspicion for timely diagnosis. These complications are potentially limb and life-threatening. The most common vascular injury concerns the profunda femoris artery with many reports in the literature [3-5]. The aim of this study is to appose how a late-onset hematoma formation and bleeding of a small branch of the lateral circumflex femoral artery can complicate intramedullary nailing after a pertrochanteric fracture and describe the proper management of the vascular complications. To the best of our knowledge, this complication has never been reported and should be considered among the possible vascular complications of intramedullary nailing.

Case Presentation

An 84-year-old female patient was admitted to our emergency department after a ground-level fall. She reported landing directly on her left side and was unable to ambulate. Clinical examination demonstrated shortened and externally rotated leg accompanied with worsening groin pain with any manipulation of the left leg. She was unable to perform a straight leg raise, while there was no neurovascular deficit. The patient's medical history included type 2 diabetes mellitus (insulin therapy) and atrial fibrillation treated with apixaban. Apixaban was stopped for 56 hours before surgery, while preoperative blood tests were within normal limits. Radiographic evaluation revealed a minimal displaced intertrochanteric fracture of the left hip, classified as 31 A1 according to the AO/OTA (Arbeitsgemeinschaft für Osteosynthesefragen/Orthopaedic Trauma Association) classification (Figure 1).

How to cite this article

Papaioannou I, Pantazidou G, Repantis T, et al. (March 26, 2022) Late-Onset Hematoma Due to Bleeding of a Small Branch of the Lateral Circumflex Femoral Artery Following Proximal Femur Intramedullary Nailing. *Cureus* 14(3): e23513. DOI 10.7759/cureus.23513

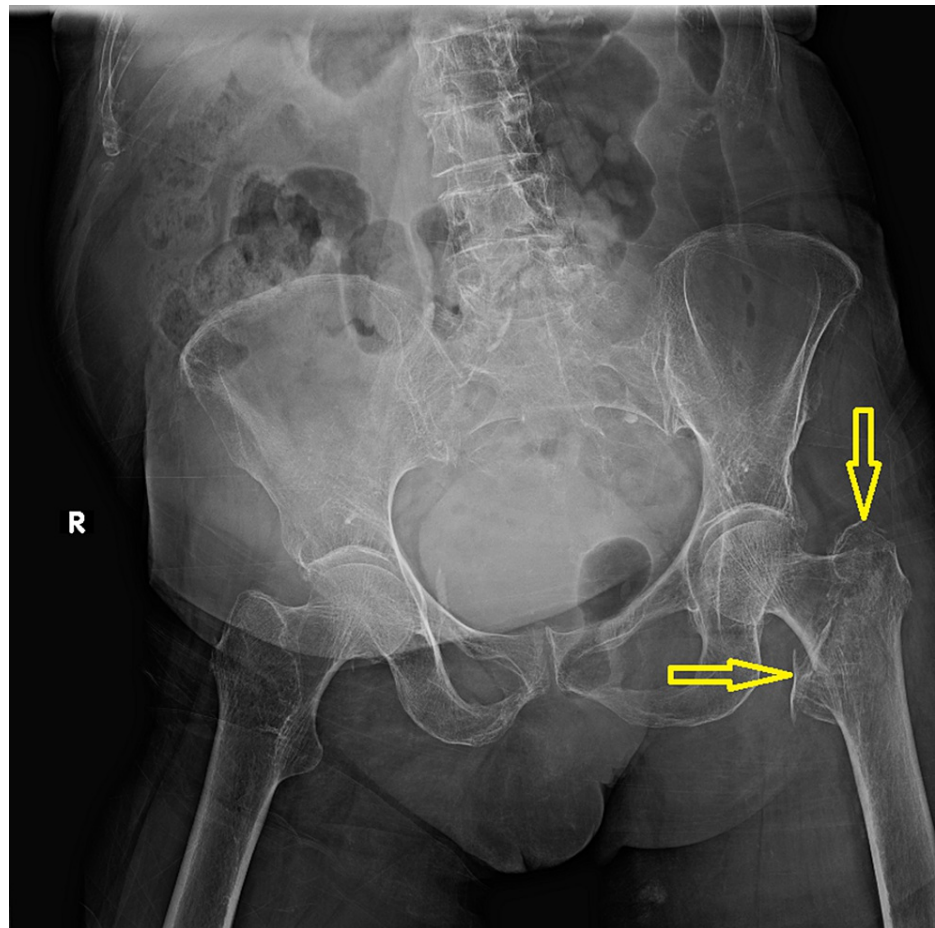


FIGURE 1: Anteroposterior plain radiogram of the hip and pelvis on admission to the emergency department.

Yellow arrows demonstrate the fracture line of the left proximal femur.

A short Gamma 3 nail (Trochanteric Nail 180, Stryker Trauma GmbH, Schönkirchen, Germany) was implanted two days after admission and the patient had an uneventful recovery (Figure 2).

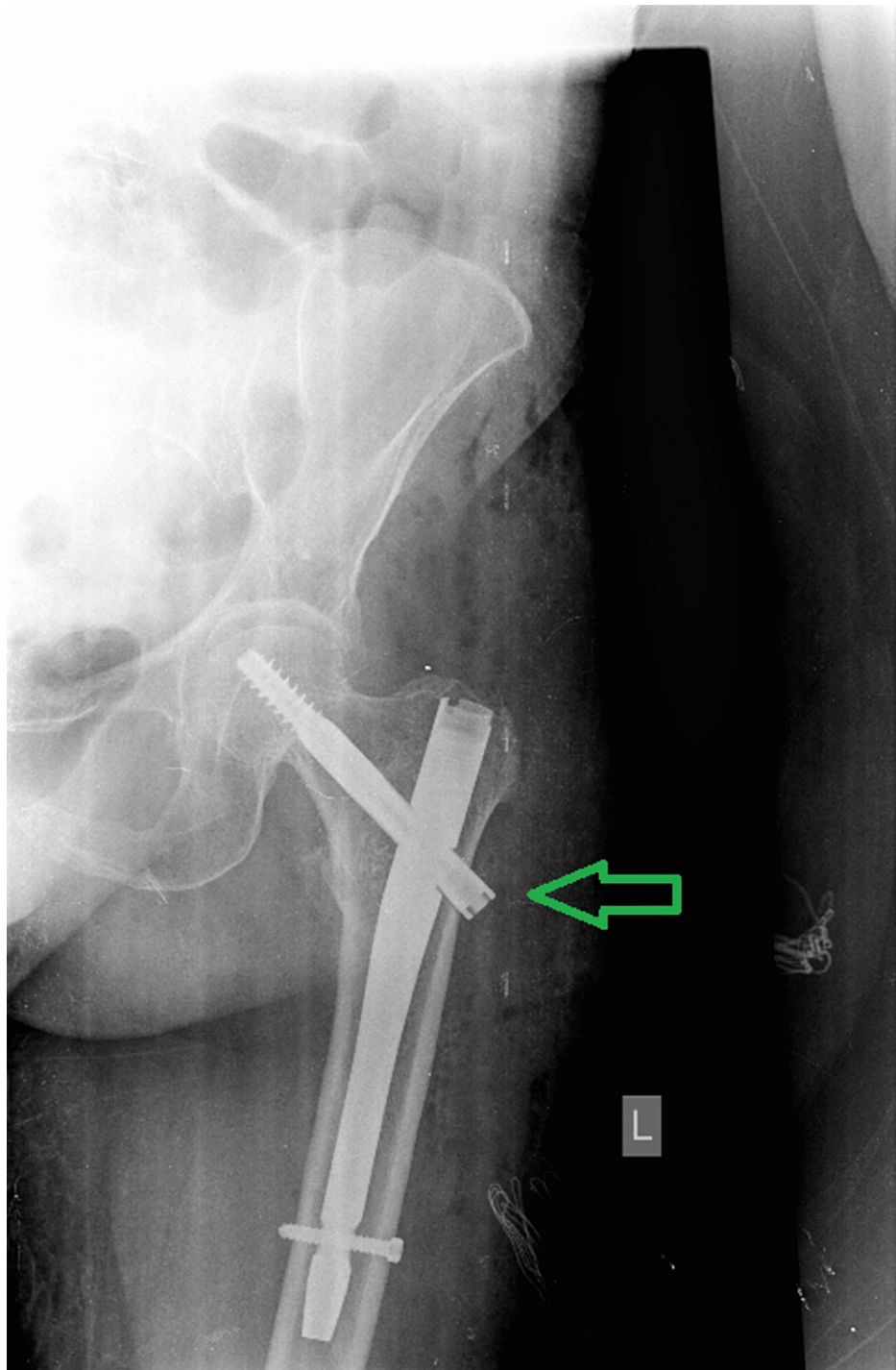


FIGURE 2: Postoperative anteroposterior plain radiogram of the left hip and proximal femur.

The green arrow demonstrates the Gamma 3 nail with adequate fracture reduction and a very satisfying outcome.

Three days postoperatively, the patient was hemodynamically stable with a hematocrit of 31% and hemoglobin of 10.3 g/dL, stable for three days, and was discharged. Twenty-five days after surgery, she was admitted again to our emergency department due to significant edema of the left thigh accompanied with remarkable pain, weakness, and inability to bear weight. The radiographic evaluation was normal, without any displacement of the implant (Figure 3).

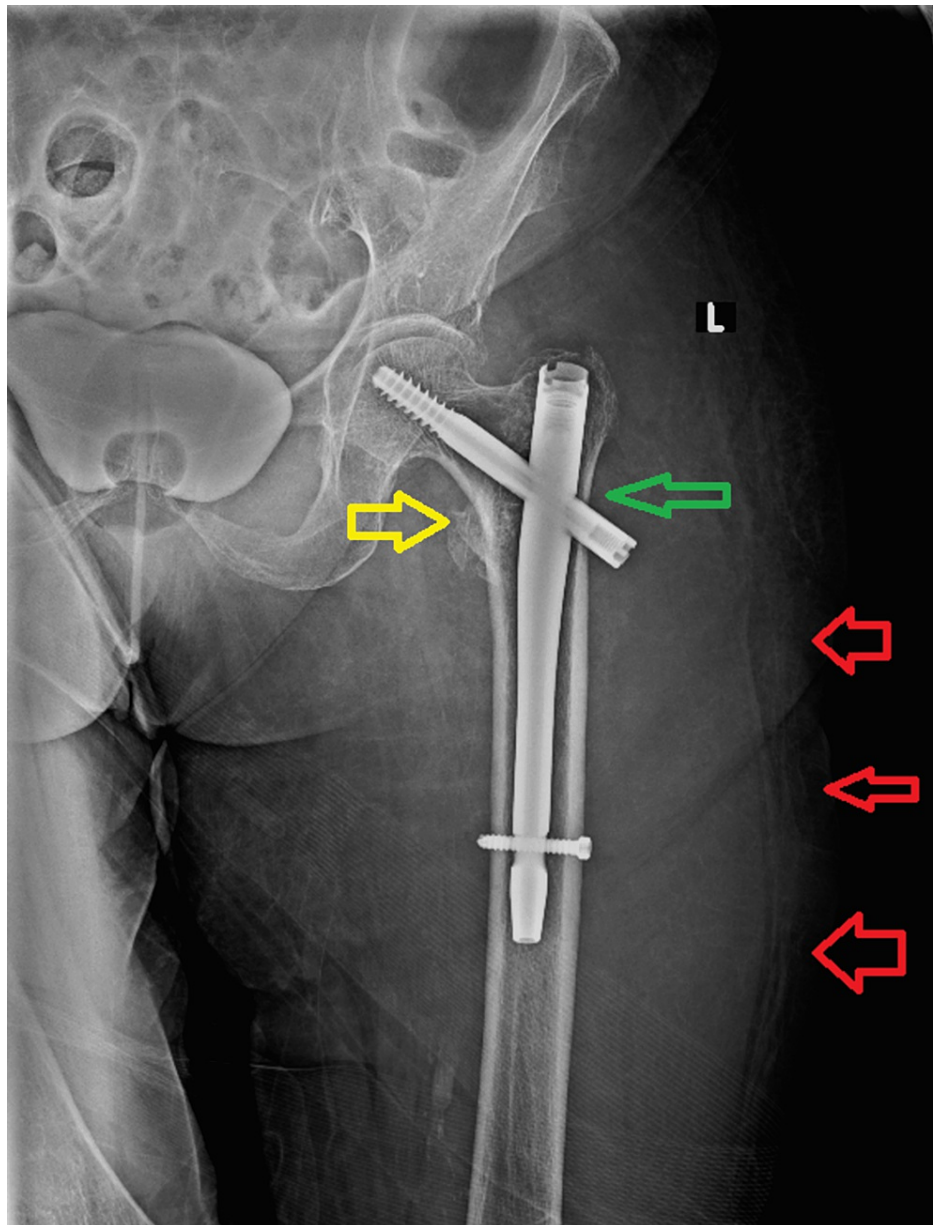


FIGURE 3: Anteroposterior plain radiogram of the left hip and proximal femur of our patient on the second admission to the emergency department.

The implant was in the previous correct position, while the yellow arrow demonstrates the compression of the fracture line and the green arrow shows the sliding of the lag screw. Red arrows indicate the excessive edema of the thigh.

The patient's hemoglobin was found to be 6.9 g/dL and she underwent a blood transfusion. Computed tomography angiography (CTA) revealed a large hematoma on the lateral side of the thigh (Figure 4) and active small extravasation (Figure 5). Once the diagnosis was settled, apixaban was stopped until the bleeding is completely controlled and the patient remains hemodynamically stable.

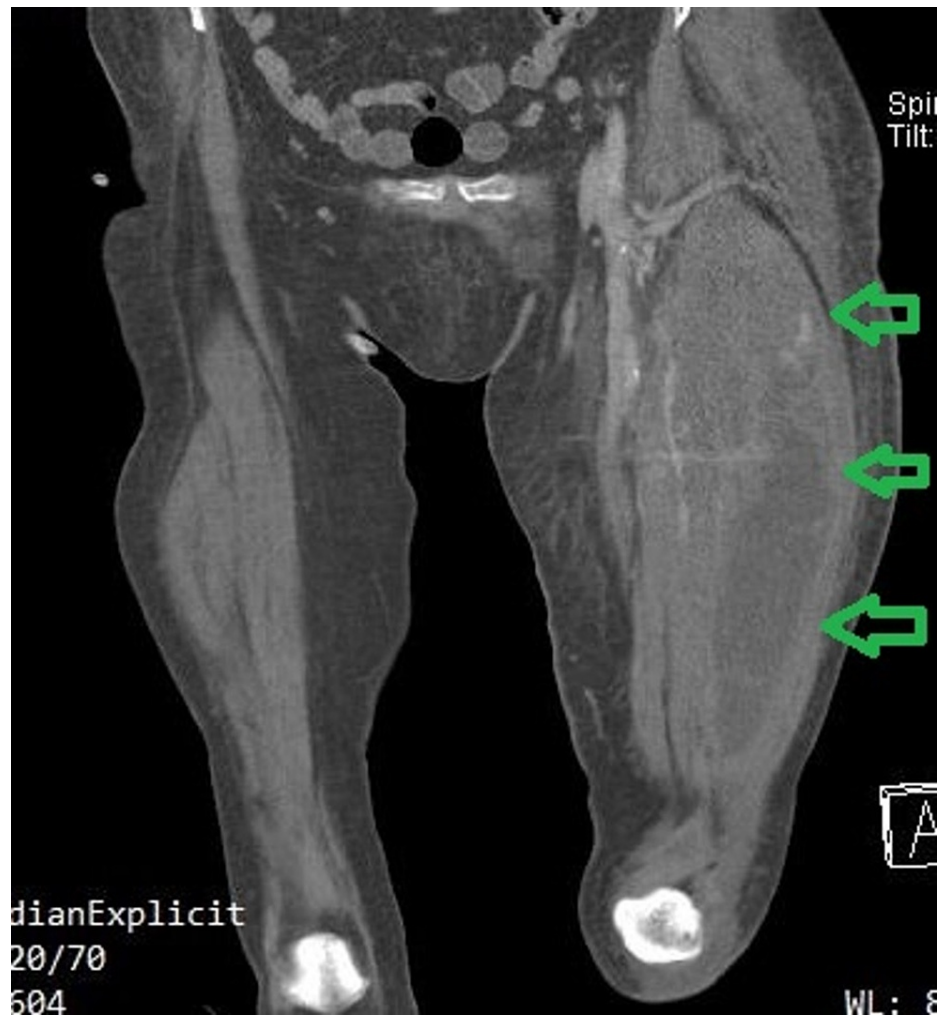

FIGURE 4: Coronal computed tomography angiography image indicates the huge hematoma formation of the left thigh (green arrows).

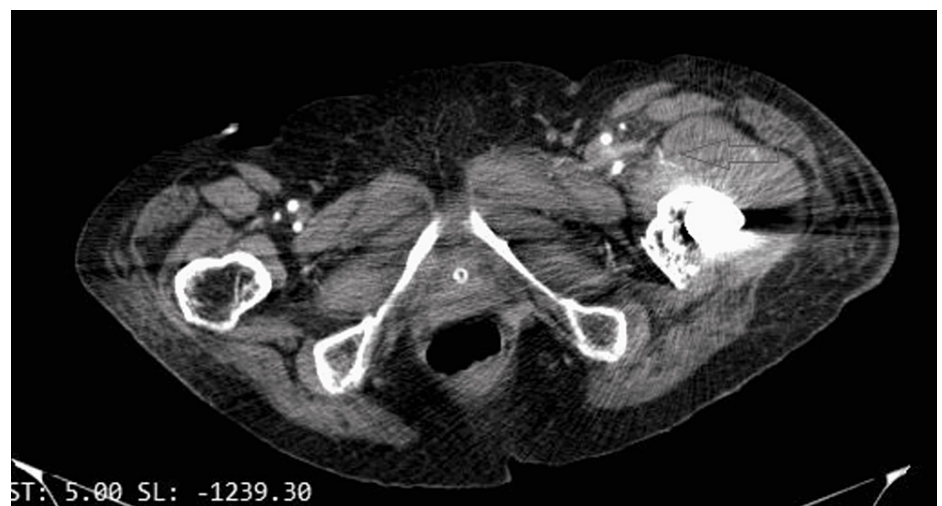

FIGURE 5: Axial computed tomography angiography image demonstrates the small extravasation (red arrow).

The patient was referred to the invasive radiology department and underwent conventional angiography. A small branch of the lateral circumflex femoral artery (branch of the deep femoral artery) was found with

active bleeding (Figure 6). Coil embolization was performed and the bleeding was stopped (Figure 7).

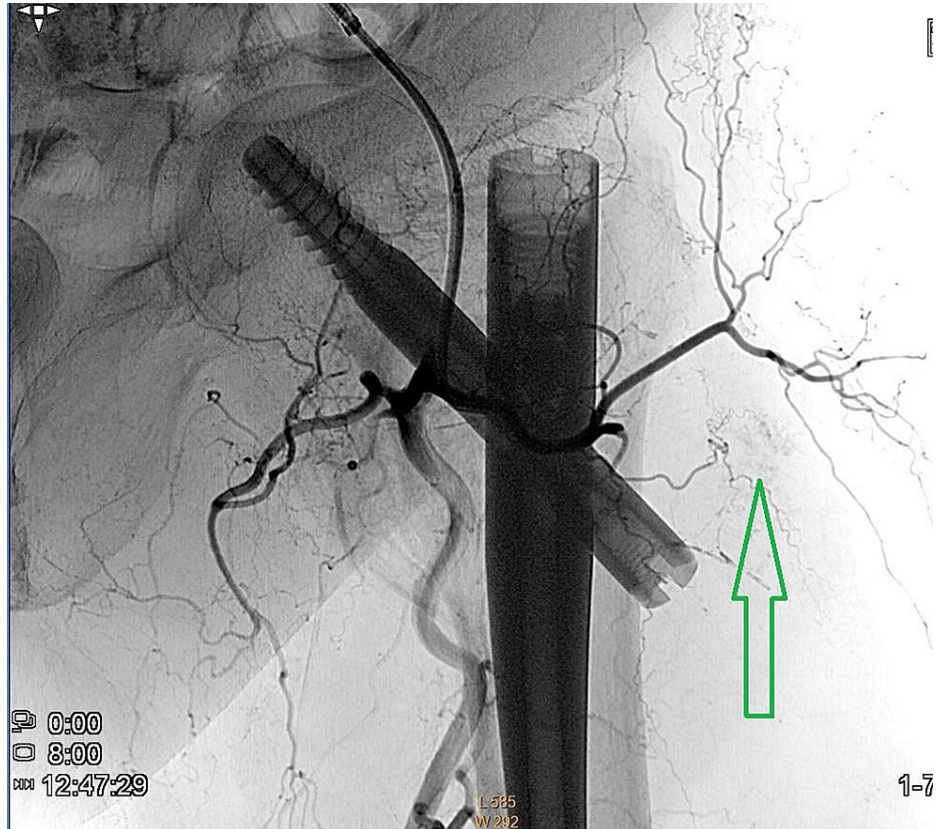


FIGURE 6: Coronal conventional angiography image of the left hip and proximal femur demonstrates the arterial flow to the hip, while the green arrow demonstrates active bleeding.

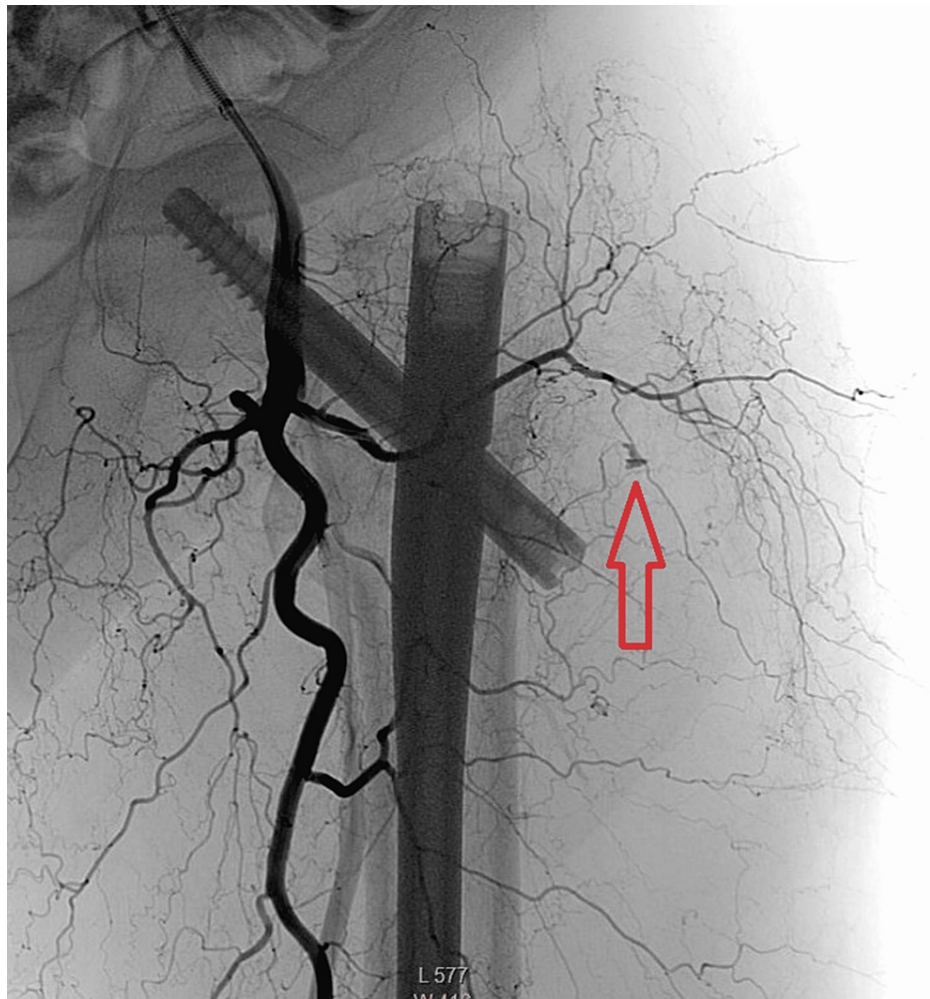


FIGURE 7: Coronal conventional angiography image of the left hip and proximal femur demonstrates the coil embolization and stoppage of bleeding (red arrow).

The edema of the thigh was resolved gradually, hemoglobin was stabilized to previous levels, and the patient returned to the rehabilitation unit three days after embolization. Apixaban administration was initiated 48 hours after coil embolization. The fracture was healed three months after the initial hip surgery and our patient returned to her daily routine six months later.

Discussion

Arterial damage during fixation of intertrochanteric hip fractures is a very rare complication [3], with a reported incidence of 0.2% [6]. However, if present, these complications can cause limb dysfunction or even become life-threatening. The most common vascular complication concerns the deep femoral artery, followed by superficial femoris, superior gluteal, and inferior epigastric arteries [3]. Vascular injuries can be hemorrhagic or thrombotic, acute with active bleeding, or delayed with pseudoaneurysm formation [6]. Neurovascular structures were susceptible to iatrogenic intraoperative injury during percutaneous insertion of implants such as pins, drill bits, screw tips, and blades, or by a displaced bone fragment at the time of fracture or during fixation.

The mechanisms of vascular injury are mainly iatrogenic due to the inappropriate use of surgical instruments. Iatrogenic vascular injury has also been observed due to forceful traction and during maneuvers to reduce lesser trochanter fractures. Most of the spontaneous non-iatrogenic vascular injury mechanisms concern the fragment of lesser trochanter [6].

The most common vascular injury during fixation of a hip fracture is the pseudoaneurysm formation of the profunda femoris artery [6], with many reports in the literature [4,5]. Pseudoaneurysms or false aneurysms are caused by partial arterial vessel damage with subsequent formation of a hematoma, which is in contact with the arterial lumen [4]. The first and historical case report was published in 1964 by Dameron [7]. The

treatment of choice for deep femoral artery pseudoaneurysm is the coil embolization or covered stent insertion, while other treatment options are ultrasound-guided compression, percutaneous ultrasound-guided thrombin injection, percutaneous ultrasound-guided collagen injection, and open surgery [6].

Damage to the profunda femoris artery or its perforating branches is usually reported due to their close relationship to the femur in the subtrochanteric region, while injury of the superficial femoral artery or its branches is much less frequent [4]. Even rarer is the injury of the lateral circumflex femoral artery and its branches. The literature review revealed only five cases with vascular injury of the lateral circumflex femoral artery. Four of them concern pseudoaneurysm formation after fixation of femoral neck fracture [8-11] and only one concerns an intertrochanteric fracture [12]. Vascular injury in the cases with femoral neck fracture was caused after the fracture fixation due to iatrogenic intervention, while in the intertrochanteric fracture case, the injury of the lateral circumflex femoral artery was caused by the lesser trochanter fragment.

To our knowledge, the lateral circumflex femoral artery has never been reported to complicate a nail fixation of an intertrochanteric fracture. We strongly believe that the damage to this small vessel was caused during the attempts for proper awl insertion by our young resident. We encourage young orthopedic surgeons to check the awl position with an image intensifier before insertion or alternatively to use a guidewire to identify the proper entry point and then insert the awl through the wire. Additionally, the apixaban re-administration three days after surgery probably worsened the bleeding and contributed to the hematoma formation.

The atherosclerotic, fragile and more rigid low-flow arteries of elderly patients are more susceptible to injury from surgical instruments or during intraoperative maneuvers [6].

Timely diagnosis is of paramount importance and can lead to proper treatment. Misdiagnosis can lead to limb ischemia and can be potentially life-threatening [6]. Compartment syndrome is another possible complication of subacute vascular injury and should also be considered [13]. There is debate in the current literature concerning the appropriate diagnostic algorithm and treatment of vascular injuries after internal fixation of proximal femur fractures [6]. The etiology of this debate is the wide spectrum of vascular injury, which varies from vessel laceration with massive bleeding to pseudoaneurysm formation accompanied by subacute bleeding and hematoma formation. In any case, if there is any fragment or implant that interferes with the injured vessel, it should be removed. Furthermore, minimally invasive intervention from radiologists or even extensive surgery from vascular surgeons is mandatory to restrict and stop bleeding. Despite the rarity of vascular injury after internal fixation of proximal femur fractures, the morbidity and mortality rates are 11.44% and 6.62%, respectively [6].

Conclusions

Orthopedic surgeons should be aware that vascular complications can occur even with late-onset presentation and even from small vessels, while administration of anticoagulants is an aggravating factor. During the postoperative period, a significant reduction of hemoglobin accompanied with massive operative site swelling should alert orthopedic surgeons to diagnose this rare condition. Elderly patients with proximal femur fractures are more susceptible to vascular injury due to the structure of their vessels and due to the vicinity of the fracture to the arterial supply of the hip.

Additional Information

Disclosures

Human subjects: Consent was obtained or waived by all participants in this study. **Conflicts of interest:** In compliance with the ICMJE uniform disclosure form, all authors declare the following: **Payment/services info:** All authors have declared that no financial support was received from any organization for the submitted work. **Financial relationships:** All authors have declared that they have no financial relationships at present or within the previous three years with any organizations that might have an interest in the submitted work. **Other relationships:** All authors have declared that there are no other relationships or activities that could appear to have influenced the submitted work.

References

1. Johnell O, Kanis JA: An estimate of the worldwide prevalence and disability associated with osteoporotic fractures. *Osteoporos Int*. 2006, 17:1726-33. [10.1007/s00198-006-0172-4](https://doi.org/10.1007/s00198-006-0172-4)
2. Sambandam SN, Chandrasekharan J, Mounasamy V, Mauffrey C: Intertrochanteric fractures: a review of fixation methods. *Eur J Orthop Surg Traumatol*. 2016, 26:339-53. [10.1007/s00590-016-1757-z](https://doi.org/10.1007/s00590-016-1757-z)
3. Mavrogenis AF, Panagopoulos GN, Megaloikonomos PD, et al.: Complications after hip nailing for fractures. *Orthopedics*. 2016, 39:e108-16. [10.3928/01477447-20151222-11](https://doi.org/10.3928/01477447-20151222-11)
4. Vande Voorde K, Dauwe J, Van Oost J: Late presentation of an iatrogenic pseudoaneurysm of the profunda femoris artery following intramedullary nailing. *Case Rep Orthop*. 2018, 2018:8270256. [10.1155/2018/8270256](https://doi.org/10.1155/2018/8270256)
5. Zhang BF, Cong YX, Wang PF, Huang H, Wang H, Zhuang Y: Deep femoral artery branch pseudoaneurysm

- formation and injury after hip fracture surgery: a case series and a literature review. *Medicine (Baltimore)*. 2018, 97:e9872. [10.1097/MD.00000000000009872](https://doi.org/10.1097/MD.00000000000009872)
6. Barquet A, Gelink A, Giannoudis PV: Proximal femoral fractures and vascular injuries in adults: incidence, aetiology and outcomes. *Injury*. 2015, 46:2297-313. [10.1016/j.injury.2015.10.021](https://doi.org/10.1016/j.injury.2015.10.021)
 7. Dameron TB Jr: False aneurysm of femoral profundus artery resulting from internal-fixation device (screw) . *J Bone Joint Surg Am*. 1964, 46:577-80.
 8. Carroll P, Flavin R: Pseudo-aneurysm of the lateral circumflex femoral artery after femoral neck fracture - a case report. *Trauma Case Rep*. 2020, 29:100351. [10.1016/j.tcr.2020.100351](https://doi.org/10.1016/j.tcr.2020.100351)
 9. Davda K, Pollard TC, Graham AJ: Delayed presentation of lateral femoral circumflex artery injury post cannulated hip screw surgery--a case report. *Ann R Coll Surg Engl*. 2009, 91:W3-5. [10.1308/147870809X401001](https://doi.org/10.1308/147870809X401001)
 10. Kantak A: Traumatic pseudoaneurysm of the lateral circumflex femoral artery presenting as anterior thigh compartment syndrome: a rare complication of intracapsular hip fracture fixation. *J Med Cases*. 2017, 8:211-4. [10.14740/jmc2807w](https://doi.org/10.14740/jmc2807w)
 11. Kakarala GK, Van Rensburg L, Parker M: Pseudo-aneurysm of the lateral circumflex femoral artery . *Eur J Trauma*. 2006, 32:480-1. [10.1007/s00068-006-5017-5](https://doi.org/10.1007/s00068-006-5017-5)
 12. Arbeloa-Gutierrez L, Arenas-Miquelez A, Muñoz L, Gordillo A, Eslava E, Insausti I, Martínez de Morentin J: Lateral circumflex femoral artery false aneurysm as a complication of intertrochanteric hip fracture with displaced lesser trochanter. *J Surg Case Rep*. 2019, 2019:rjz184. [10.1093/jscr/rjz184](https://doi.org/10.1093/jscr/rjz184)
 13. Burghardt RD, Siebenlist S, Döbele S, Lucke M, Stöckle U: Compartment syndrome of the thigh. A case report with delayed onset after stable pelvic ring fracture and chronic anticoagulation therapy. *BMC Geriatr*. 2010, 10:51. [10.1186/1471-2318-10-51](https://doi.org/10.1186/1471-2318-10-51)