

CASE REPORT

Video-assisted thoracoscopy in the management of intrapleural extravasation of cytotoxic chemotherapy

Victor J. Aguirre, Dylan Barnett, Nikki Burdett, Rohit Joshi & Fabiano F. Viana

Cardiothoracic Surgical Unit, Department of Cardiothoracic Surgery, Royal Adelaide Hospital, Adelaide, South Australia, Australia

Keywords

Anthracycline toxicity; chemotherapy complication; dexrazoxane; mal-positioned central line; video-assisted thoracoscopy.

Correspondence

Victor J. Aguirre, Department of Cardiothoracic Surgery, Level 4, East Wing, Royal Adelaide Hospital, North Terrace, Adelaide, SA 5000, Australia.
Tel: +61 4 2104 7532
Fax: +61 8 8222 5962
Email: australiapda@live.com.au

Received: 17 January 2017;

Accepted: 9 February 2017.

doi: 10.1111/1759-7714.12430

Thoracic Cancer 8 (2017) 363–364

Abstract

The extravasation of cytotoxic agents into subcutaneous tissue is a serious complication of chemotherapy. Unfortunately, if such extravasation occurs into the pleural space, limited data is available to guide appropriate management. We present the first report in the literature of video-assisted thoracoscopy combined with a topoisomerase II inhibitor and iron chelator, dexrazoxane, in the successful management of this complication.

Introduction

A 50-year-old woman with breast cancer required urgent thoracoscopy, following the iatrogenic infusion of doxorubicin into her pleural space through a mal-positioned central venous catheter.

Her only relevant medical history was high-risk invasive ductal carcinoma of the breast, for which a bilateral mastectomy and left axillary lymph node clearance had already been performed.

Case report

Prior to commencing the first cycle of adjuvant chemotherapy, long-term central venous access was gained through the insertion of the Powerport with Groshong Catheter (BARD, Inc., Murray Hill, NJ, USA) through the right subclavian vein. No complications were noted at the time of the procedure. The position of the line was confirmed with fluoroscopy and routine chest X-ray (Fig 1).

The first cycle of chemotherapy consisted of doxorubicin and cyclophosphamide. Following the infusion of doxorubicin, the patient soon complained of severe right side pleuritic chest

pain. A fluoroscopy contrast study showed that the central venous catheter was draining into the pleural space (Fig 2).

A right thoracoscopic-assisted pleural lavage was performed the same day. This visually confirmed that the tip of the central catheter was lodged in the pleural space but there was no frank pneumonitis or direct parenchymal injury to the lung (Fig 2). Ten liters of warmed normal saline were used to wash out the pleural space. Three chest drains were left for the purpose of administering 24 hours of saline irrigation.

Peri-procedural intravenous infusion of an initial dose of 1000 mg/m² dexrazoxane was administered immediately before the operation, followed by 500 mg/m² daily for two days postoperatively.

She recovered well from the incident.

Discussion

Anthracyclines, for example, daunorubicin, idarubicin, epirubicin, and doxorubicin, are widely used cytotoxic drugs in the treatment of hematological malignancies and solid tumors. These agents are especially prone to cause severe tissue damage on extravasation compared with other types of injectable antitumor drugs.¹

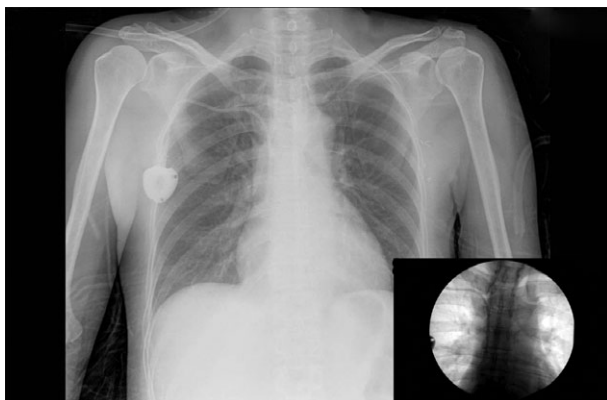

Figure 1 Chest X ray confirming the position of the central venous catheter.

Anthracyclines have the potential to cause the most damage or complications because they bind to the DNA of healthy tissue when they leak out of a vein. This process causes cell death and continues to do so as more of the drug is released into the surrounding tissue, causing pain, as in the described case.²

The topoisomerase II inhibitor and iron chelator, dexrazoxane, has been proven to prevent the potentially devastating effects of anthracycline extravasation. It is highly effective with minimal side effects and is well tolerated by patients.³ Dexrazoxane is approved by the Food and Drug Administration, but not the Therapeutic Goods Administration, and has limited availability in Australia.

Extravasation is caused by mal-positioning of central venous catheters, which can be classified as primary occurring at the time of placement, or secondary occurring sometime after placement. The causes of secondary mal-positioning are poorly understood, as in our case, where

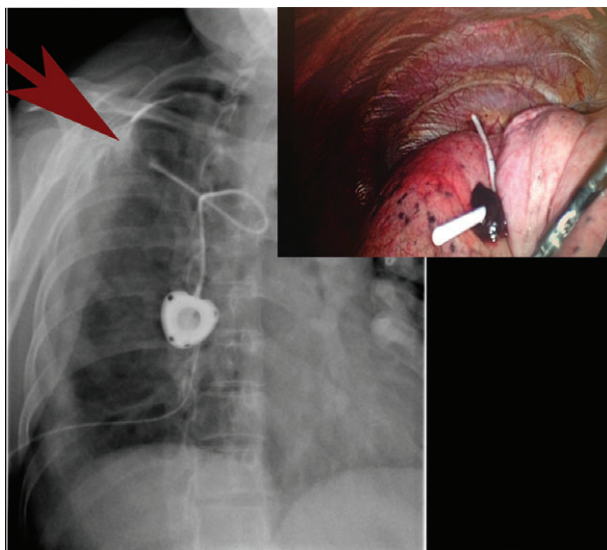


Figure 2 Fluoroscopy contrast study showing the tip of the catheter (arrow) draining into the pleural space and thoracoscopy image confirming the tip of the catheter lodged in the pleural space.

initial investigation seemed to confirm correct positioning (Fig 1). Fracture and distal embolization of the catheter as part of the “pinch-off” syndrome is far more common.⁴

Because of the small number of thoracic extravasation injuries, there is no consensus on the most appropriate treatment, which is extrapolated from experience with peripheral access.⁵ Surgical procedures with the objective of draining the remaining solution after discontinuation of the infusion, along with dexrazoxane, must be considered as soon as possible to prevent major complications.

Surgical options, such as percutaneous drainage, thoracoscopy, and open thoracotomy can be used. Unfortunately, the percutaneous option can cause subsequent complications because of the visual limitations of insertion, as in a case reported by Uges *et al.* where the percutaneous drainage was complicated by empyema.⁶

In our case, we decided to use video-assisted thoracoscopy to confirm the catheter position and to further assess the local tissue damage from doxorubicin. It also guided an accurate lavage of the cavity, the placement of the catheters that were used posteriorly for continuous irrigation, and helped to safely remove the mal-positioned catheter (Fig 2).

In conclusion, combined early medical and surgical management of pleural extravasation of cytotoxic drugs, such as anthracyclines, is essential. Video-assisted thoracoscopy can confirm tissue damage and aid drainage, lavage, and subsequent irrigation of the cavity. We recommend its use in combination with dexrazoxane, which is well tolerated and prevents short and long term toxicity.

Disclosure

No authors report any conflict of interest.

References

- 1 Curtit E, Chaigneau L, Pauchot J *et al.* Extravasation of liposomal doxorubicin induces irritant reaction without vesicant injury. *Anticancer Res* 2012; **32**: 1481–3.
- 2 Schrijvers DL. Extravasation: A dreaded complication of chemotherapy. *Ann Oncol* 2003; **14** (Suppl. 3): iii26–30.
- 3 Mouridsen HT, Langer SW, Buter J *et al.* Treatment of anthracycline extravasation with Savene (dexrazoxane): Results from two prospective clinical multicentre studies. *Ann Oncol* 2007; **18**: 546–50.
- 4 Viale PH. Complications associated with implantable vascular access devices in the patient with cancer. *J Infus Nurs* 2003; **26**: 97–102.
- 5 Thomas CJ, Butler CS. Delayed pneumothorax and hydrothorax with central venous catheter migration. *Anaesthesia* 1999; **54**: 987–90.
- 6 Uges JWF, Vollaard AM, Wilms EB, Brouwer RE. Intrapleural extravasation of epirubicin, 5-fluouracil, and cyclophosphamide, treated with dexrazoxane. *Int J Clin Oncol* 2006; **11**: 467–70.