

# Lung *Talaromyces marneffi* infection in an Indonesian papillary thyroid carcinoma patient

SAGE Open Medical Case Reports  
Volume 5: 1–5  
© The Author(s) 2017  
Reprints and permissions:  
sagepub.co.uk/journalsPermissions.nav  
DOI: 10.1177/2050313X17744918  
journals.sagepub.com/home/sco



Surya Darma<sup>1</sup>, Yusrizal Djam'an Saleh<sup>2</sup> and Tri Wibawa<sup>1</sup>

## Abstract

Talaromycosis, a disseminated and progressive infection caused by *Talaromyces marneffi*, is highly endemic in the tropical region of Asia. However, accumulated data show very low incidence in Indonesia. Here, we report a case of papillary thyroid carcinoma with pulmonary *T. marneffi* infection. Screening of *T. marneffi* in this immunocompromised Indonesian patient is recommended even though the reported incidence of this particular fungal infection in Indonesia is low.

## Keywords

*Talaromyces marneffi*, talaromycosis, lung, Indonesia

Date received: 24 February 2017; accepted: 1 November 2017

## Introduction

Talaromycosis is a disseminated and progressive infection caused by *Talaromyces marneffi*, a facultative intracellular pathogen and the only thermally dimorphic fungus of the genus *Talaromyces*. It is reported to be highly endemic in the tropical region of Asia, especially Southeast Asia, Northeastern India, China, Hong Kong, and Taiwan.<sup>1</sup> Talaromycosis is a common opportunistic infection in HIV-infected and non-HIV-infected patients<sup>2,3</sup> and may involve pulmonary symptoms and abnormal chest radiographs.<sup>4</sup>

*T. marneffi* is a dimorphic fungus. At temperatures below 37°C, the fungus grows as mold with the formation of septate hyphae, bearing conidiophores and conidia, while at 37°C on culture medium or in human tissue, the fungus grows in a yeast-like form.<sup>1</sup> The most important mechanism which enables the fungus to establish infection in a human being is the alteration of conidia to the yeast phase. It can survive and replicate inside the phagolysosome of professional phagocytes such as macrophages and then subsequently escape from the phagosome into the cytoplasm.<sup>5</sup> The inhibition of phagosome maturation contributes to intracellular survival.<sup>6</sup>

Thyroid cancer incidence has continuously and sharply increased all over the world. Thyroid cancer is dominated by differentiated carcinoma which includes papillary carcinoma, follicular carcinoma, and Hurthle cell cancer.<sup>7</sup> Fungal infections have emerged as significant problems among immunocompromised cancer patients. Fungal infections in

cancer patients can be caused by pathogenic fungi and by opportunistic fungi including *T. marneffi*.<sup>3</sup>

Despite several accumulated reports of *T. marneffi* infection in Southeast Asia, there is very limited data on talaromycosis in Indonesia. It may be under diagnosed because of a low index of suspicion by medical specialists or Indonesia may truly have a lower incidence of talaromycosis compared to neighboring countries in the region. Here, we report *T. marneffi* infection in a papillary thyroid carcinoma patient from Yogyakarta, Indonesia.

## Case report

A 58-year-old female clinically suspected to have an adenoma thyroid consulted our pulmonary clinic for progressive non-purulent cough, dyspnea, hemoptysis, and mild fever. The patient works in her own clothing stall. Possible

<sup>1</sup>Department of Microbiology, Faculty of Medicine, Universitas Gadjah Mada, Yogyakarta, Indonesia

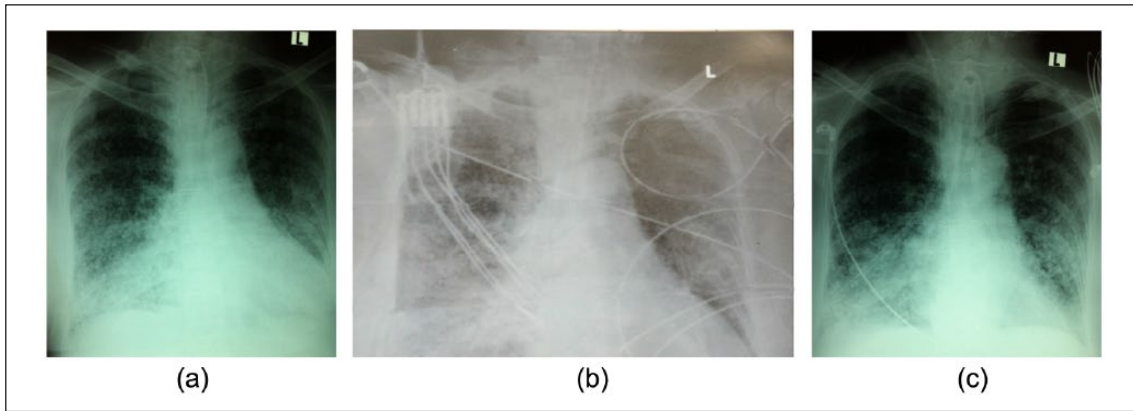
<sup>2</sup>Division of Pulmonology, Dr. Sardjito General Hospital, Yogyakarta, Indonesia

### Corresponding Author:

Tri Wibawa, Department of Microbiology, Faculty of Medicine, Universitas Gadjah Mada, Jl. Farmaco, Sekip Utara, Yogyakarta 55281, Indonesia.

Email: twibawa@ugm.ac.id





**Figure 1.** (a) Chest X-ray obtained on the second day of admission showed right thyroid gland enlargement with tracheal impingement, disseminated miliary shadows, and an enlarged heart. (b) Chest X-ray obtained on the sixth day of admission showed bilateral infiltration with disseminated miliary shadows as well as enlarged hilar lymph nodes. (c) Chest X-ray obtained on the 18th day of antifungal administration showed disseminated miliary shadows and an enlarged heart with absence of bilateral infiltration.

exposure to rats was not confirmed. There was no history of traveling to overseas or endemic areas of talaromycosis. A lump on her neck and bilateral sub-costal and inter-costal retractions were clinically observed. Inspection of the skin did not show any abnormality. Auscultation revealed bilateral rales, rhonchi, and wheezing. Chest X-ray showed disseminated miliary shadows (Figure 1(a)).

Laboratory workup showed normal complete blood count with slight decrease in total T3 (0.43  $\mu\text{g}/\text{m}$ ). Blood culture done for this patient had negative results. Neither bone marrow aspiration nor HIV infection screening was performed. Sputum specimen was obtained on the second day and was subjected to acid-fast bacilli (AFB) staining, as well as bacterial and fungal culture. AFB was not found in microscopic examination after Ziehl–Neelsen staining of the patient’s sputum. Furthermore, sputum culture on Lowenstein Jensen media did not grow any mycobacteria.

The routine sputum culture on Sabouraud’s dextrose agar medium incubated at 25°C showed growth of mold form of fungus with green mycelia. Notably, the medium became red-brown in color since the soluble red pigment diffused into the medium (Figure 2(a)). Microscopic examination showed the mycelia morphology as hyaline, septate-branched hyphae, with branched conidiophores (Figure 2(c)). The grown fungus showed dimorphism. At 37°C temperature, the yeast form grew on the brain heart infusion agar (Figure 2(b)) and the microscopic examination showed yeast-like appearance of the fungus (Figure 2(d)). Drug susceptibility testing was performed using the microdilution method according to the Clinical & Laboratory Standards Institute (CLSI) manual. Test results for ketoconazole, itraconazole, fluconazole, and terbinafine showed fungal susceptibility to terbinafine only.

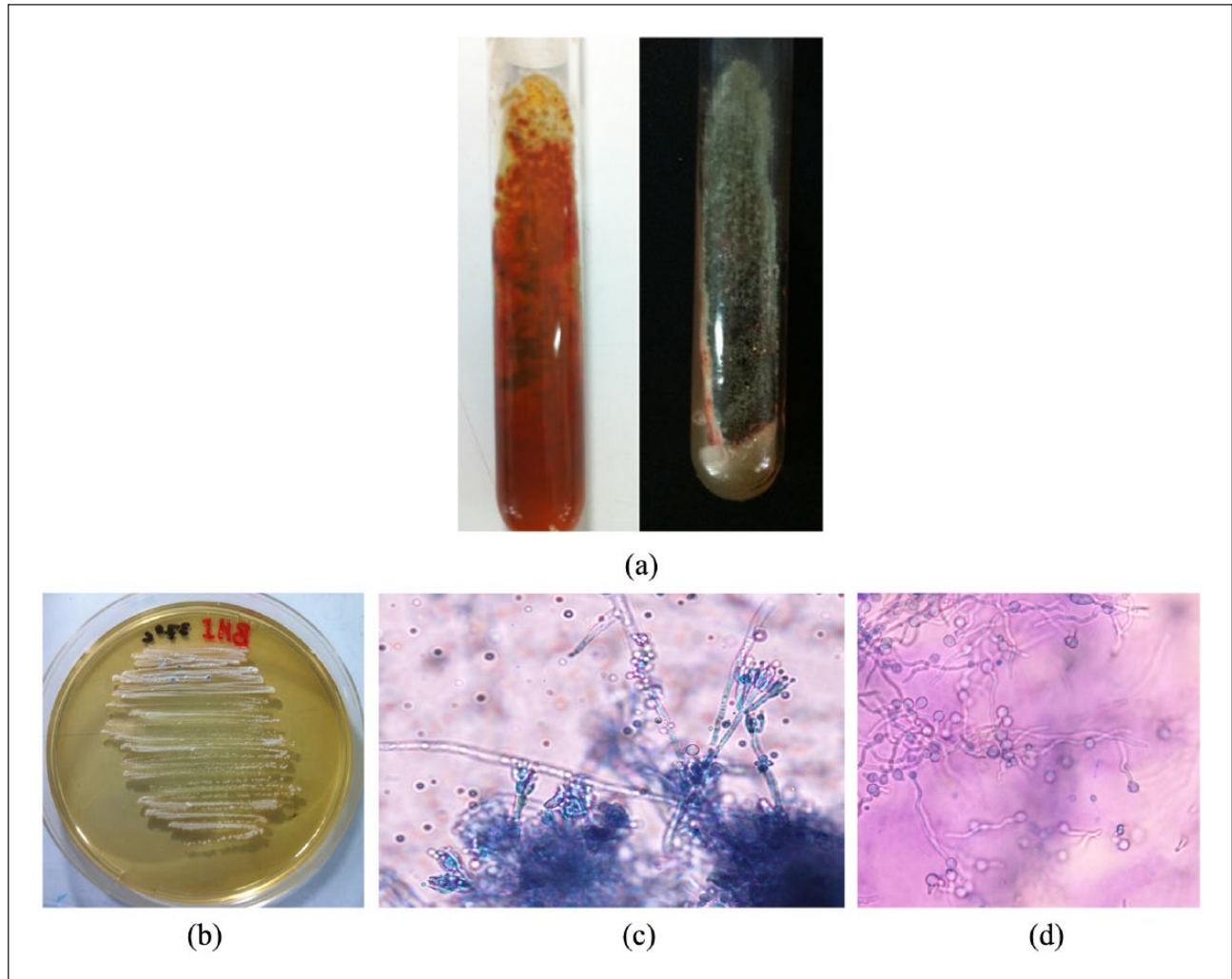
Fungal DNA extraction was performed using standard phenol-chloroform methods as described elsewhere. Polymerase chain reaction (PCR) amplification was performed using the

DreamTaq Green PCR Master Mix (Thermo Scientific). One primer set corresponding to the 18S ribosomal RNA (rRNA) consisted of a forward primer 18SF 5'-GCC AGC GAG TAT AAG CCT TG-3' and a reverse primer 18SR 5'-AGG CCT CAC TAA GCC ATT CA-3'.<sup>8</sup> The PCR profile consisted of a 4-min initial denaturation at 95°C, 35 cycles of amplification with denaturation at 95°C for 30 s, 30 s annealing at 51°C and elongation at 72°C for 1 min, and a final elongation at 72°C for 5 min. The expected 193-kb PCR product underwent sequencing of the partial 18S rRNA gene. The DNA sequence of amplified segment was 96%–98% similar with the 18S rRNA sequence of *Penicillium* sp. It was then confirmed that the patient was infected with *T. marneffeii*.

*Enterobacter cloacae* was also isolated from the sputum specimen. Antibiotic susceptibility test was performed using the Kirby–Bauer method according to the CLSI manual. The bacteria showed sensitivity to several antibiotics including amikacin, gentamicin, levofloxacin, chloramphenicol, meropenem, ceftriaxone, ciprofloxacin, cotrimoxazole, and cefuroxime.

On the fourth day, the patient underwent total thyroidectomy and because the patient suffered from respiratory failure, she was transferred to the intensive care unit (ICU). Chest X-ray examination, performed on the sixth hospital day, showed bilateral infiltration with disseminated miliary shadows and enlarged hilar lymph nodes (Figure 1(b)). Histopathology results confirmed the papillary thyroid carcinoma diagnosis.

The patient was treated with meropenem for a suspected lower respiratory tract bacterial infection. However, clinical improvement was not observed after the 7-day meropenem treatment. Soon after the patient was diagnosed as suffering from talaromycosis, micafungin treatment at 100 mg/iv/day was initiated. Micafungin was administered because of fungal resistance against the azole group and unavailability of amphotericin B. Evaluation of antifungal therapy was



**Figure 2.** (a) The fungus grew on Sabouraud's dextrose agar medium incubated at 25°C for 10 days. The mold form of fungus with mycelia was observed. Soluble red pigment was diffused into the medium. (b) The fungus grew on Brain Heart Infusion Agar incubated at 37°C for 6 days. The yeast form of fungus was observed. (c) Microscopic appearance after lacto phenol cotton blue staining. Mycelial morphology was obtained after a 10-day incubation on Sabouraud's dextrose agar medium at 25°C. It showed hyaline, septate, branched hyphae with branched conidiophores or penicilli. (d) Microscopic appearance after lacto phenol cotton blue staining. The yeast-like appearance was observed after inoculation on Brain Heart Infusion Agar and incubated at 37°C for 24 h.

performed on the 18th day of micafungin administration. It was observed that the patient showed significant clinical improvement (Figure 1(c)). Written and signed consent to publish the case report was obtained from the legal guardian of the patient who unfortunately passed away because of the malignancy.

## Discussion

Almost 80% of thyroid cancers are papillary cancers which are also called papillary carcinomas or papillary adenocarcinomas. Papillary thyroid carcinoma commonly grows slowly and usually develops in only one lobe of the thyroid gland.<sup>9</sup> However, the ability to metastasize has been reported. Lung metastases is the most frequent distant metastases of papillary

thyroid carcinoma. Lung metastases of papillary thyroid carcinomas typically cause a micronodular or miliary pattern in the lungs while metastases consisting of a solitary pulmonary nodule is rare.<sup>10,11</sup>

*E. cloacae*, a common nosocomial infection that is ubiquitously found in the environment, frequently involves the lower respiratory system.<sup>12</sup> Meropenem is the recommended antibiotic to eradicate lower respiratory tract infection caused by *E. cloacae*.<sup>13</sup> Meropenem administration in our patient did not produce clinical improvement, thus prompting the medical staff to consider another possible infection causing the progressive clinical deterioration of the patient.

*T. marneffeii* is notorious for its propensity to infect the lungs and the reticuloendothelial system and to proliferate within histiocytes.<sup>4</sup> The most common clinical manifestations

of *T. marneffeii* infection in HIV-infected or patients with malignancies are fever, malaise, anemia, weight loss, lymphadenopathy, cough, hepatosplenomegaly, skin lesions, and diarrhea.<sup>14,15</sup> Lung involvement as seen on chest radiographic findings showed diffuse reticulonodular infiltration, localized interstitial infiltration, and discrete interstitial infiltrates in the lung base or bilateral interstitial infiltration with disseminated miliary shadows. Radiographic findings often observed were found to be similar to tuberculosis and/or other opportunistic infections.<sup>4</sup>

Diagnosis of *T. marneffeii* infection needs appropriate clinical specimens obtained from bone marrow aspirates, blood, lymph node biopsies, skin biopsies, skin scrapings, sputum, bronchoalveolar lavage pellet, pleural fluid, liver biopsies, cerebrospinal fluid, pharyngeal ulcer scrapings, palatal papule scrapings, urine, stool samples, and tissue samples from the kidney, pericardium, stomach, or intestine.<sup>4</sup> Diagnosis of *T. marneffeii* infection is commonly performed by identifying the fungus in clinical specimens by microscopy and culture. Other available laboratory examinations include serology to detect the specific antibody and antigen and detection via PCR amplification.<sup>1,4</sup>

For this patient, chest X-ray and routine imaging for thoracic symptoms were not able to differentiate tuberculosis, lung metastasis, or a yeast infection. The confirmatory diagnosis in this patient was obtained using routine microbiological examination, that is, bacterial and fungal culture. Identification of the mold was done via microscopic examination, cultivation, and PCR confirmation. Although identification of the fungus was not 100% confirmed by 18S rRNA sequencing data, *T. marneffeii* was the most plausible causative agent of our case. Furthermore, administration of the antifungal medication was able to alter the patient's clinical condition on the 18th hospital day.

## Conclusion

A case of talaromycosis secondary to pulmonary metastasis of papillary thyroid carcinoma was presented. Although the clinical features of *T. marneffeii* infection are not specific, conditions such as HIV infection or malignancies, living in Southeast Asia, fever, lung abnormalities, and cervical lymphadenopathies should prompt the clinician to test for *T. marneffeii* infection. Early diagnosis is crucial because the infection is fatal if untreated. This very interesting case emphasizes the importance of screening for *T. marneffeii* infection via routine simple sputum cultures in immunocompromised cases. Fungal cultivation is therefore recommended in lung metastatic neoplasm cases. This approach may be applicable in hospitals in developing countries wherein resources are limited.

## Acknowledgements

The authors thank the doctors and nurses who clinically managed the patient during her hospitalization. The authors also thank to Dr

Catherine Lynn T. Silao of the University of Philippines College of Medicine for her critical review of the manuscript.

## Declaration of conflicting interests

The author(s) declared no potential conflicts of interest with respect to the research, authorship, and/or publication of this article.

## Ethical approval

Our institution does not require ethical approval for reporting individual cases or case series.

## Funding

The author(s) received no financial support for the research, authorship, and/or publication of this article.

## Informed consent

Written informed consent was obtained from a legally authorized representative(s) for anonymized patient information to be published in this article.

## References

1. Vanittanakom N, Cooper CR Jr, Fisher MC, et al. *Penicillium marneffeii* infection and recent advances in the epidemiology and molecular biology aspects. *Clin Microbiol Rev* 2006; 19: 95–110.
2. Le T, Wolbers M, Chi NH, et al. Epidemiology, seasonality, and predictors of outcome of AIDS-associated *Penicillium marneffeii* infection in Ho Chi Minh City, Viet Nam. *Clin Infect Dis* 2011; 52: 945–952.
3. Chan JFW, Lau SKP, Yuen KY, et al. *Talaromyces (Penicillium) marneffeii* infection in non-HIV-infected patients. *Emerg Microbes Infec* 2016; 5: e19.
4. Kang Y, Feitelson M, de Hoog S, et al. *Penicillium marneffeii* and its pulmonary involvements. *Curr Respir Med Rev* 2012; 8: 356–364.
5. Pongpom M, Vanittanakom P, Nimmanee P, et al. Adaptation to macrophage killing by *Talaromyces marneffeii*. *Future Sci OA* 2017; 3: FSO215.
6. Lu S, Hu Y, Lu C, et al. Development of in vitro macrophage system to evaluate phagocytosis and intracellular fate of *Penicillium marneffeii* conidia. *Mycopathologia* 2013; 176: 11–22.
7. Pellegriti G, Frasca F, Regalbuto C, et al. Worldwide increasing incidence of thyroid cancer: update on epidemiology and risk factors. *J Canc Epidemiol* 2013; 12: 9652.
8. Rogers PD and Barker KS. Evaluation of differential gene expression in fluconazole-susceptible and -resistant isolates of *Candida albicans* by cDNA microarray analysis. *Antimicrob Agents Chemother* 2002; 46: 3412–3417.
9. American Cancer Society. *Thyroid cancer*. Atlanta, GA: American Cancer Society, 2016.
10. Gkoutouvas A, Chatjimarkou F, Thomas D, et al. Miliary lung metastasis due to papillary thyroid carcinoma. *BMJ Case Rep*. Epub ahead of print 20 February 2009. DOI: 10.1136/bcr.06.2008.0322.
11. Kaseda K, Watanabe K, Sakamaki H, et al. Solitary pulmonary metastasis from occult papillary thyroid carcinoma. *Thorac Cancer* 2016; 7: 261–263.

12. Davin-Regli A and Pagès JM. *Enterobacter aerogenes* and *Enterobacter cloacae*; versatile bacterial pathogens confronting antibiotic treatment. *Front Microbiol* 2015; 6: 392.
13. Lee CC, Lee NY and Yan JY. Bacteremia due to extended-spectrum- $\beta$ -lactamase-producing *Enterobacter cloacae*: role of carbapenem therapy. *Antimicrob Agents Chemother* 2010; 54: 3551–3556.
14. Wu TC, Chan JWM, Ng CK, et al. Clinical presentations and outcomes of *Penicillium marneffe* infections: a series from 1994 to 2004. *Hong Kong Med J* 2008; 14: 104–109.
15. Larsson M, Nguyen LHT, Wertheim HFL, et al. Clinical characteristics and outcome of *Penicillium marneffe* infection among HIV-infected patients in northern Vietnam. *AIDS Res Ther* 2012; 9: 24.