

Surgical management of a perforated ‘black oesophagus’

A 74-year-old male with a history of rheumatoid arthritis, alcohol abuse and heavy smoking presented with malaise, abdominal pain and weight loss. Subsequent gastroscopy revealed evidence of a ‘black oesophagus’ with a clear demarcation to normal mucosa evident at the gastroesophageal junction (Fig. 1a,b). A diagnosis of acute oesophageal necrosis (AON) was made, and the patient was admitted for observation, fasted and commenced on proton-pump inhibitors. Following a period of hypoxia, a CT pulmonary angiogram (CTPA) was performed in order to exclude pulmonary emboli. Results revealed diffuse mesenteric, mediastinal, para-aortic and supraclavicular lymphadenopathy. After a 13-day stay, the patient was discharged.

Two weeks following discharge, the patient re-presented with a 1-day history of abdominal pain and vomiting with computed tomography evidence of pneumomediastinum surrounding the distal oesophagus (Fig. 2). Following resuscitation and the initiation of broad-spectrum antibiotics, an urgent endoscopy was performed. This revealed blackened oesophageal mucosa and diffuse ulceration commencing at 25 cm, as well as a large perforation at 38 cm from the incisors (Fig. 3a). An immediate laparoscopy was performed which demonstrated a large mediastinal collection that was causing the peritoneum between the right crus and the oesophagus to bulge (Fig. 3b). After opening the hiatus, more than 500 cc of bile drained from the mediastinum. Bilateral chest tubes were placed in order to drain the contamination within both pleural cavities. Due to continuous hemodynamic instability, a minimally invasive, non-oncological, transhiatal oesophageal resection and cervical oesophagostomy was performed without reconstruction of the intestinal tract. A feeding jejunostomy was placed for nutritional support. The previously pathologically enlarged mesenteric lymph nodes were biopsied.

On the fifth postoperative day, after the patient had been weaned from vasopressive support, gastrointestinal continuity was restored using a gastric conduit via the posterior mediastinal tract. An early reconstruction was performed in order to avoid the possible adhesions that may obliterate the native oesophageal tract. Analysis of the biopsied lymph node revealed a metastatic grade two neuroendocrine tumour (NET), histologically suggestive for a pancreatic NET, which was later confirmed with a Ga-68-DOTATOC PET/CT-scan. The patient was discharged home 35 days after the first operation on a liquid diet with additional tube feeding.

Black oesophagus, or AON, is a rare disease with an incidence of up to 0.28%.^{1,2} The condition is characterized by the endoscopic finding of black and friable oesophageal mucosa, which is typically located in the distal oesophagus and stops abruptly at the gastroesophageal junction. The aetiology is unknown, but the pathophysiology of AON is likely to be multifactorial, resulting from a combination of tissue hypoperfusion, impaired local mucosal protection and reflux of gastric contents overwhelming the oesophageal mucosa. AON has a high overall mortality of 31.8% and can be complicated by oesophageal perforation. Perforation occurs in cases involving full-thickness necrosis of the oesophageal tissue. A full-thickness lysis is associated with vascular thrombosis, extrinsic oesophageal compression by hematoma, gastric volvulus and photodynamic therapy.³ With a mortality rate of 10–40%, oesophageal perforation is a lethal complication requiring surgical intervention.^{3,4} To date, only eight cases of perforation in the setting of AON have been described.^{3,5–7}

The management of AON at the time of diagnosis includes hemodynamic stabilization, glycaemic control, fasting and aggressive acid suppression.⁸ After treatment, a repeat endoscopy allows

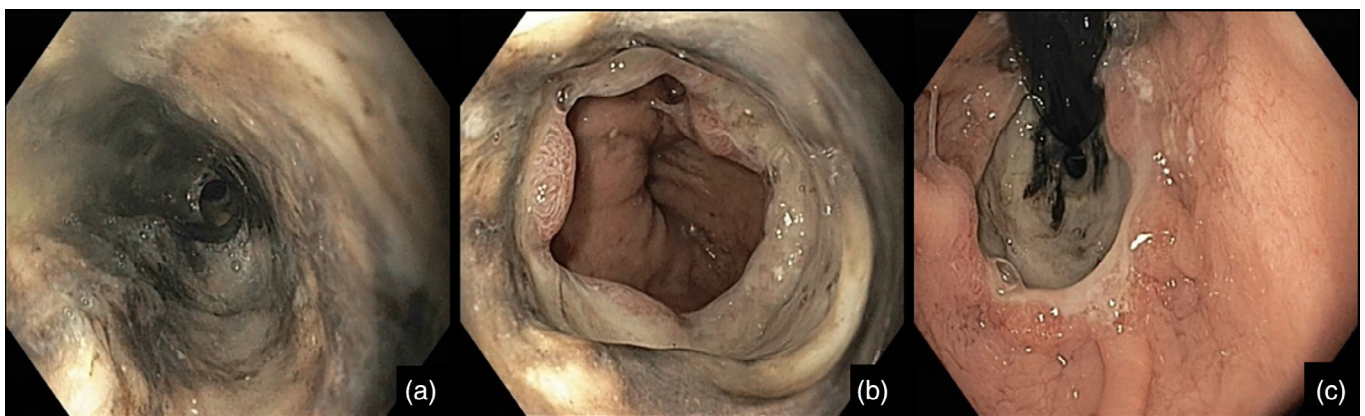


Fig 1. Initial endoscopic findings of acute oesophageal necrosis. Diffuse blackening of mucosa is evident (a,b) with demarcation of the mucosal ischemia at the gastroesophageal junction (c,d).

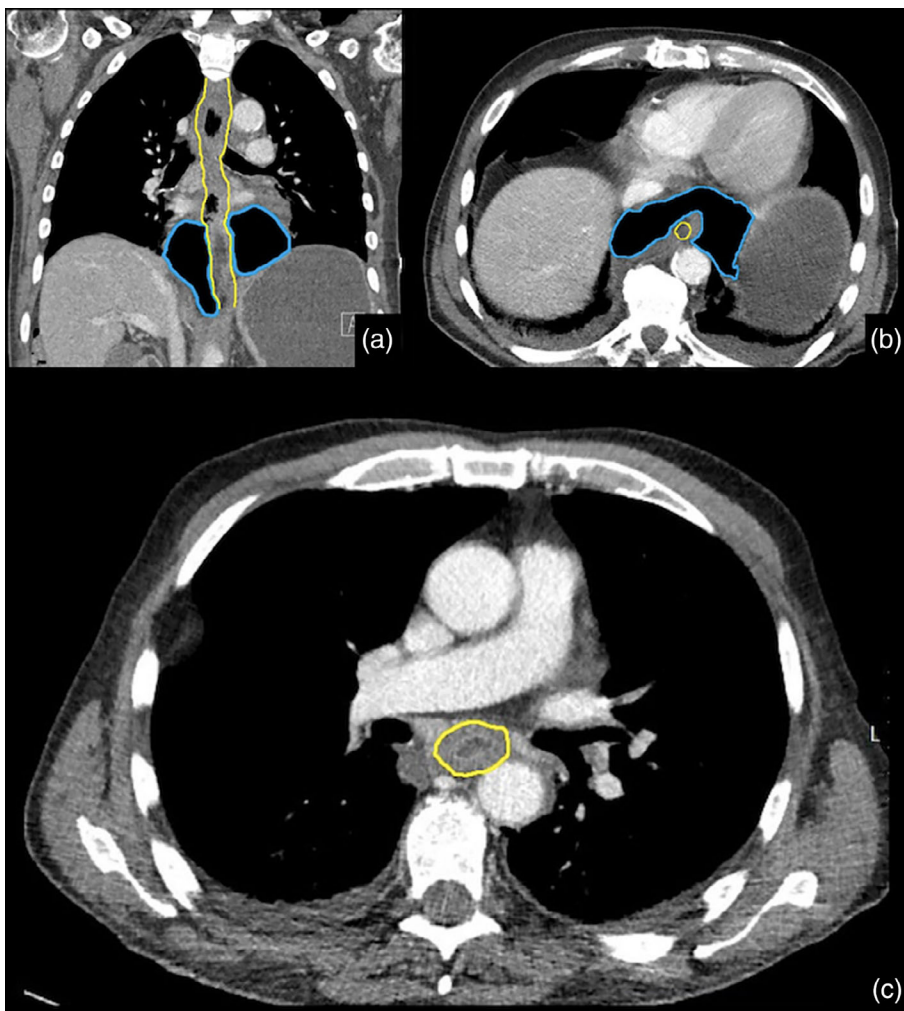


Fig 2. Computed tomography imaging with coronal (a) and axial view (b,c) revealing massive pneumomediastinum surrounding the distal oesophagus. Blue marking: Pneumomediastinum. Yellow marking: Oesophagus.

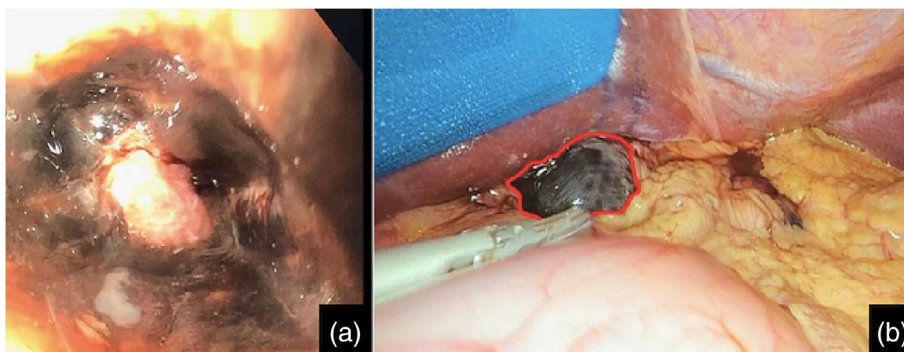


Fig 3. An endoscopic image obtained immediately prior to surgery demonstrating a perforation of the distal oesophagus (a) and a laparoscopic image demonstrating bulging peritoneum between the right crus and oesophagus due to hydropneumomediastinum (b).

for documentation of oesophageal recovery. As the oesophageal mucosa commonly takes less than a month to recover, a repeat endoscopy is recommended approximately 1 month after initial presentation.^{8,9}

To our knowledge, with 26 days between the presentation of AON and perforation of the oesophagus, this is the first report on delayed oesophageal perforation in the setting of this disease. This is also the first report of a synchronous NET; however, the

significance of this as a risk factor is difficult to establish, as the patient also had two other classic risk factors associated with AON – alcohol abuse and smoking.^{9,10}

In this case, a minimally invasive oesophagectomy was performed, without direct reconstruction. This decision was made due to the risk of performing an anastomosis in the setting of severe sepsis and inflammation. Given the time span in which the native oesophageal route remains traversable for a gastric conduit following

oesophagectomy is unknown, reconstruction was planned as soon as hemodynamic and respiratory independence was demonstrated.

Acknowledgements

MDR is supported by the Senior Lecturer Fellowship from the Royal Australasian College of Surgeons.

Author contributions

Writing-original draft; writing-review and editing. **Michiel de Maat:** Writing-original draft; writing-review and editing. Writing-original draft; writing-review and editing. **Lodewijk Brosens:** Supervision; writing-original draft; writing-review and editing. **Sebastiaan van Tuyl:** Supervision; writing-review and editing. **Jelle Ruurda:** Supervision; writing-original draft; writing-review and editing. **Richard van Hillegersberg:** Supervision; writing-original draft; writing-review and editing.

References

1. Augusto F, Fernandes V, Cremers MI *et al.* Acute necrotizing esophagitis: a large retrospective case series. *Endoscopy* 2004; **36**: 411–5.
2. Panesar D, Schauer C, Raj A, Wilkins J, Wagener J. Acute oesophageal necrosis following septic cellulitis. *ANZ J. Surg.* 2020; **90**: 1491–2.
3. Gurvits GE, Shapsis A, Lau N, Gualtieri N, Robilotti JG. Acute esophageal necrosis: a rare syndrome. *J. Gastroenterol.* 2007; **42**: 29–38.
4. Vogel SB, Rout WR, Martin TD, Abbitt PL. Esophageal perforation in adults: aggressive, conservative treatment lowers morbidity and mortality. *Ann. Surg.* 2005; **241**: 1016–21.
5. Akaishi R, Taniyama Y, Sakurai T *et al.* Acute esophageal necrosis with esophagus perforation treated by thoracoscopic subtotal esophagectomy and reconstructive surgery on a secondary esophageal stricture: a case report. *Surg. Case Rep.* 2019; **5**: 73.
6. Harner A, Mitchell A, Kilbourne M. Acute esophageal necrosis resulting in esophageal perforation. *Am. Surg.* 2019; **85**: e339–41.
7. Groenveld RL, Bijlsma A, Steenvoorde P, Ozdemir A. A black perforated esophagus treated with surgery: report of a case. *World J. Gastrointest. Surg.* 2013; **5**: 199–201.
8. Gurvits GE. Black esophagus: acute esophageal necrosis syndrome. *World J. Gastroenterol.* 2010; **16**: 3219–25.
9. Dias E, Santos-Antunes J, Macedo G. Diagnosis and management of acute esophageal necrosis. *Ann. Gastroenterol.* 2019; **32**: 529–40.
10. Watanabe Y, Fujiwara Y, Shiba M *et al.* Cigarette smoking and alcohol consumption associated with gastro-oesophageal reflux disease in Japanese men. *Scand. J. Gastroenterol.* 2003; **38**: 807–11.

Gino M. Kuiper,* BSc

Michiel F. G. de Maat,* MD, PhD

Matthew D. Read,*† MBBS, FRACS, PhD

Lodewijk A. A. Brosens,‡ MD, PhD

Sebastiaan A. van Tuyl,§ MD, PhD

Jelle P. Ruurda,* MD, PhD

Richard van Hillegersberg,* MD, PhD

*Department of Surgery, University Medical Center Utrecht, Utrecht, The Netherlands, †Department of Surgery, The University of Melbourne, St Vincent's Hospital, Melbourne, Australia,

‡Department of Pathology, University Medical Center Utrecht, Utrecht, The Netherlands and §Department of Gastroenterology, Diakonessenhuis, Utrecht, The Netherlands

doi: 10.1111/ans.16565