

# Arthroscopic Bone and Cartilage Grafting of Acetabular Cysts With Autologous Tissue

Andrew W. Alwood, D.O., and Brian D. Giordano, M.D.



**Abstract:** Repair of acetabular cysts and cartilage defects presents a challenge for the hip-preservation surgeon. Currently, most techniques involve allograft sources or open surgery. We present an arthroscopic technique using autologous graft sources for both bone and cartilage to repair subchondral acetabular cysts and the overlying cartilage defect. This technique uses new technology in combination with familiar arthroscopic instruments to decrease morbidity, hasten rehabilitation, and possibly improve the prognosis of these difficult to treat lesions.

Acetabular chondral lesions frequently are encountered during arthroscopic hip surgeries.<sup>1</sup> The presence of these lesions is highly correlated to poor outcomes and conversion to total hip arthroplasty.<sup>2</sup> Many lesions coincide with poor subchondral bone structure or subchondral cysts, which further limits the available treatment options. Goals in treating these lesions include filling the subchondral structural defect, creating a chondral scaffold, and providing a stabilized biologic to support osseous and chondral healing. An arthroscopic treatment that can create this biologic environment without the morbidity of an open procedure or a graft donor site will have considerable advantage in repairing these lesions. We present our technique for arthroscopic treatment of an acetabular subchondral cyst with associated chondral loss (Figs 1 and 2) using a combination of autologous bone and cartilage grafts.

## Surgical Technique (With Video Illustration)

### Patient Positioning and Portal Sites

The patient is placed supine on a hip distraction table with the feet in padded surgical boots (Breg, Carlsbad, CA). With standard arthroscopic setup, procedure is initiated and anterolateral and mid-anterior portals are established via safe techniques.<sup>3</sup>

### Diagnostic Arthroscopy and Chondral Lesion Preparation

Diagnostic arthroscopy is completed, including assessing the status of the cartilage overlying the cyst, which is then probed to estimate depth of the defect (Figs 3-5). Unstable chondral flaps are debrided to a stable base using biters. The goal is to create stable walls of cartilage to contain graft material. Chondral flaps can be harvested using proprietary material capture systems (GraftNet; Arthrex, Naples, FL). Evolving literature has demonstrated that substantial cell viability is present within these flaps and may

From the Department of Orthopaedics and Rehabilitation, University of Rochester Medical Center (A.W.A.); and Department of Orthopaedics, Sports Medicine and Hip Preservation, University of Rochester (B.D.G.), Rochester, New York, U.S.A.

The authors report the following potential conflicts of interest or sources of funding: B.D.G. reports personal fees from Arthrex, outside the submitted work. Full ICMJE author disclosure forms are available for this article online, as [supplementary material](#).

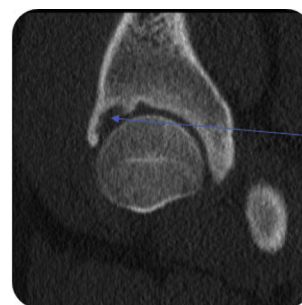Received June 24, 2020; accepted October 20, 2020.

Address correspondence to Brian D. Giordano, M.D., 601 Elmwood Ave, Box 665, Rochester, NY 14642. E-mail: [brian\\_giordano@urmc.rochester.edu](mailto:brian_giordano@urmc.rochester.edu)

© 2020 by the Arthroscopy Association of North America. Published by Elsevier. This is an open access article under the CC BY-NC-ND license (<http://creativecommons.org/licenses/by-nc-nd/4.0/>).

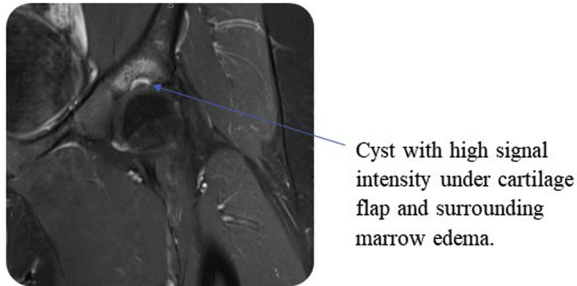
2212-6287/201190

<https://doi.org/10.1016/j.eats.2020.10.041>



Large subchondral cyst in the acetabular dome.

**Fig 1.** Preoperative coronal computed tomography scan of a left hip demonstrating a large anterior subchondral acetabular cyst.

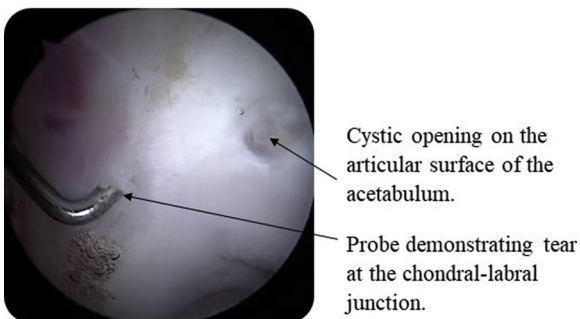


**Fig 2.** Preoperative coronal fat-saturated magnetic resonance imaging of a left hip demonstrating an unstable chondral defect covering an acetabular cyst with high intensity signal behind the cartilage lesion.

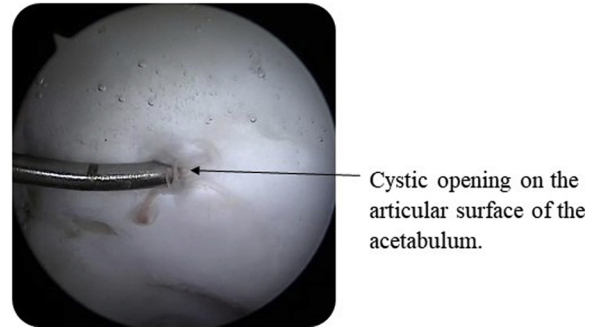
represent a more bioactivated form of chondrocyte than in healthy articular surfaces.<sup>4</sup> Subchondral bone exposed around the cyst is prepared with a curette to remove the calcified cartilage layer. Marrow stimulation may be used at the discretion of the surgeon.

### Acetabular Cyst Preparation

The acetabular rim is prepared for labral repair (Fig 6). The labral attachment to the rim is left intact, if possible. The rim is shaped with a motorized burr and is prepared to a large bed to accept a cannulated drilling system to access the acetabular cyst in an outside-in fashion (Fig 7). Provisional labral repair is performed around the cyst, with care taken to preserve bone around and prevent drill tunnel perforation into the cyst (Figs 8-10). Suture anchors for labral repair are placed on either side of the proposed site for cyst access. If the labrum is unstable in the region of the cyst, a suture anchor can be added after the cyst is filled by placing it medial/superior to the cyst and suspending the sutures over the access hole. We avoid burring the acetabular bone to locate the cyst, as this can remove excess bone from the acetabulum. Frequently, the cyst may be accessed via the mid-anterior portal. An 8-ga delivery cannula (Intra- Osseous BioPlasty kit; Arthrex) is used as a drill sleeve



**Fig 3.** Arthroscopic view in the central compartment of a supine left hip position from the anterolateral portal demonstrating a labral tear with associated cartilage defect in the adjacent weight-bearing portion of the acetabulum.

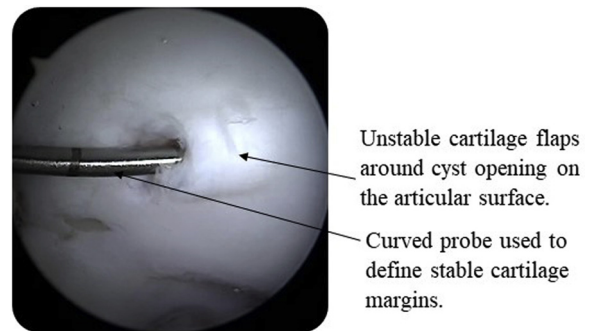


**Fig 4.** Arthroscopic view in the central compartment of a supine left hip shows a probe being placed into the cartilage defect to reveal a subchondral cyst. This helps to remove loculations and cystic fluid as well as measure the depth of the cavity.

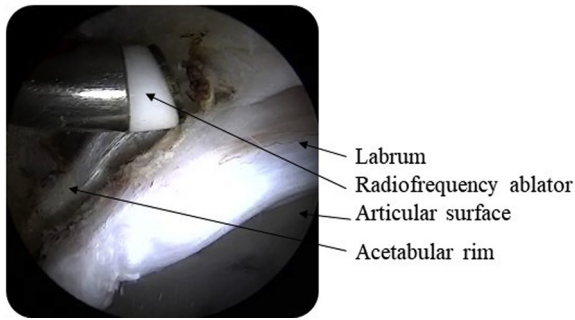
allowing a 2.4-mm guide pin to be advanced into the acetabular rim directed at the subchondral lesion (Fig 11). Depending on the size and orientation of the cyst, the surgeon may directly visualize the guide pin entering the cyst cavity or notice cyst contents extruding from the articular side of the cyst opening. Fluoroscopy may be used to confirm positioning. A 7-mm low-profile cannulated reamer (IntraOsseous Bio-plasty kit; Arthrex) is then placed over the guide pin and reamed until the cyst is accessed. This depth may be estimated based upon preoperative imaging as well as intraoperative assessment. Once the access hole has been created in the acetabular rim, a curved probe may be used to further delineate the depth of the cystic cavity (Fig 12).

### Harvesting of the Autologous Tissue

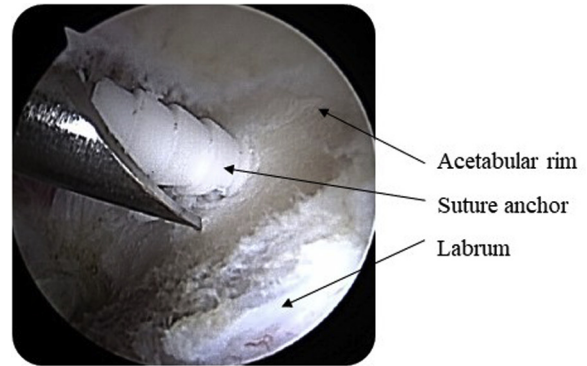
Traction is released on the operative extremity (Fig 13). With a bone marrow aspiration needle introduced through a proximal peritrochanteric incision, bone marrow aspirate is harvested from the femoral metaphysis. This aspirate is handed off to a perfusionist to be concentrated. The arthroscope is placed in the standard anterolateral portal, visualizing the peripheral



**Fig 5.** Arthroscopic view of the central compartment of a supine left hip showing a probe being used to evaluate the stability of the margins of the cartilage lesion. Note, the probe easily slides underneath an area of delaminated cartilage.



**Fig 6.** Arthroscopic view of a supine left hip the acetabular rim from the anterolateral portal. The acetabulum is prepared for labral repair and cyst localization. Here, a radiofrequency ablator is used to remove soft tissue from the bony acetabulum, preserving capsule and labrum.

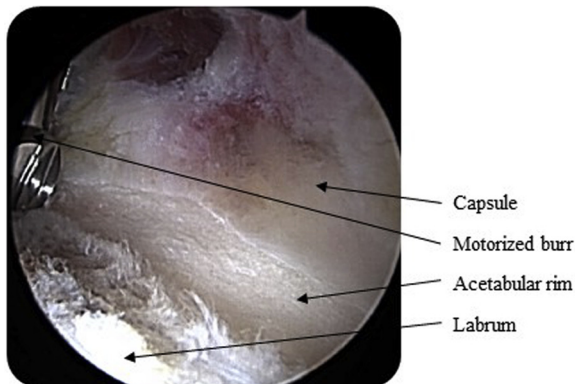


**Fig 8.** Arthroscopic view of a supine left hip viewing the acetabular rim from the anterolateral portal. Suture anchors are placed in the acetabular rim in preparation for labral repair. Care is taken to avoid the rim overlying the cystic cavity.

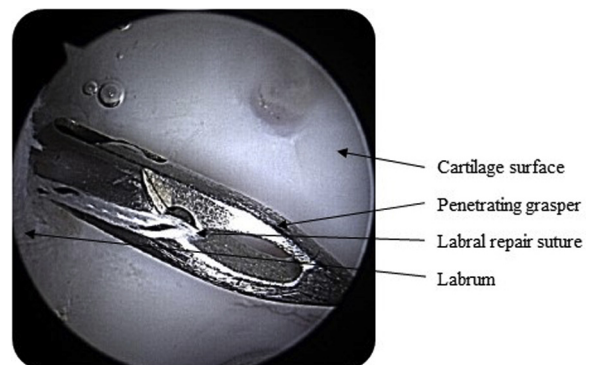
compartment, and attention is turned to the femoral head–neck junction. An autologous tissue collector (GraftNet; Arthrex) is attached to the motorized shaver and standard suction tubing. With the use of a bone cutting shaver, hyaline cartilage is harvested from the nonweight-bearing portion of the anterolateral head–neck junction (Fig 14), with care taken to leave a rim of intact cartilage to maintain a suction seal of the hip when flexed and rotated. The cartilage is automatically morcellated by the action of the shaver and collected into a sterile chamber in the tissue collector. This chamber may be emptied and reused or a new container can be swapped in its place when switching between autologous donor materials. The shaver or a motorized burr may then be used to harvest bone from the same region which is generally the site of cam femoroplasty (Fig 15). The chamber of bone shavings also is removed from the suction device. Remainder of the femoroplasty is performed as needed.

### Preparation of Osseous and Cartilaginous Graft

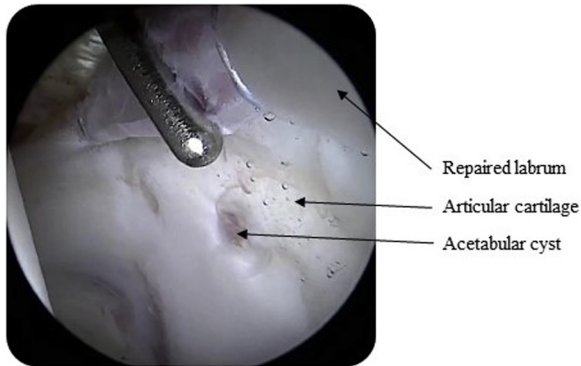
The bone graft is mixed on the back table with the bone marrow aspirate concentrate. The ratio of marrow concentrate to morcellated bone can be tailored to specific needs. A general ratio of 2:1 (bone:bone marrow aspirate concentrate) will give a viscous mixture that will have enough structural integrity to be injected into the acetabular defect. Additional demineralized bone matrix (Allosync/Allosync Pure; Arthrex) is incorporated into the autogenous bone mixture to expand the volume of the graft as needed. More bone marrow aspirate can be added as needed to decrease viscosity and improve the ease of application. This process is repeated for the cartilage-derived graft, with the exception of adding additional allogeneic cartilage and platelet-rich plasma (Arthrex Angel plus Biocartilage; Arthrex) to expand the total volume of the graft. These mixtures are taken up into a syringe to facilitate ease of mixing and eventual application.



**Fig 7.** Arthroscopic view of a supine left hip from the anterolateral portal showing the final preparation of the acetabular rim with a motorized burr, contouring the bone to accept suture anchors and improve surface area for drilling a guide pin into the acetabular rim.



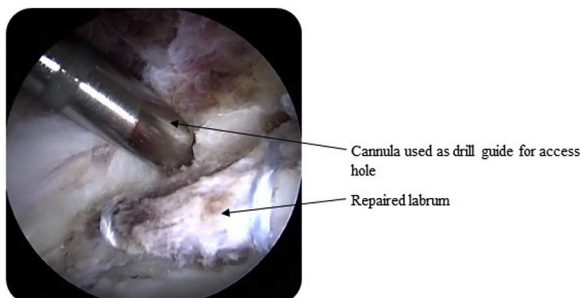
**Fig 9.** Arthroscopic view of a supine left hip in the central compartment showing labral repair sutures being passed through the chondral-labral junction with an arthroscopic penetrating grasper.



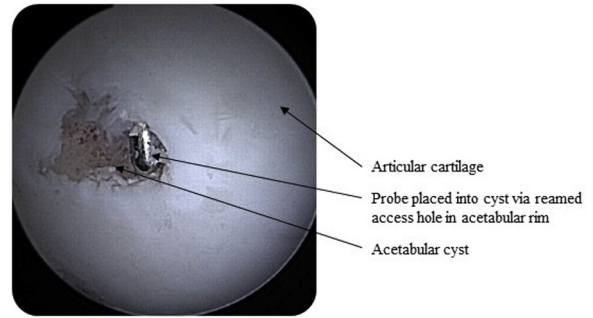
**Fig 10.** Arthroscopic view of a supine left hip from the anterolateral portal in the central compartment demonstrating the final repair construct with knotless suture anchors straddling the area of the cyst.

### Injection of the Defect Sites

Traction is initiated once again to allow visualization of the defect from inside the joint while the defect is grafted with an outside-in technique. The 8-ga delivery cannula is placed into the acetabular access hole via the same portal with which it was drilled. The syringe loaded with the osseous mixture is attached to the cannula and the acetabular cyst is filled with the graft while viewing the central compartment to watch for extrusion out of the chondral defect. An elevator or probe is used to help contain the mixture as it is injected (Fig 16). The delivery cannula is backed out slowly and more graft is injected to continue filling the drilled access hole in the acetabular rim. Once the cyst has been filled, excess graft or debris in the joint should be removed with a motorized shaver. Arthroscopic fluid is turned off and suctioned out of the joint. The osseous graft is tamped in gently with an elevator to reduce air pockets and improve the density of the subchondral foundation (Figs 17 and 18). The cartilage-based mixture is then applied to the chondral defect via a curve-tipped delivery needle (Fig 19). An elevator is used to spread and tamp down the mixture to a smooth, even layer (Fig 20). Care is taken to not



**Fig 11.** Arthroscopic view from the anterolateral portal of a supine left hip as the delivery cannula is placed onto acetabular rim to guide a pin into the cystic cavity. Pin is placed using direct visualization and fluoroscopic guidance.



**Fig 12.** Arthroscopic view of a supine left hip in the central compartment after reaming an access hole in the acetabulum, a probe can be placed into the cyst for further estimation of the cyst's dimensions. Note, unstable cartilage margins have now been resected.

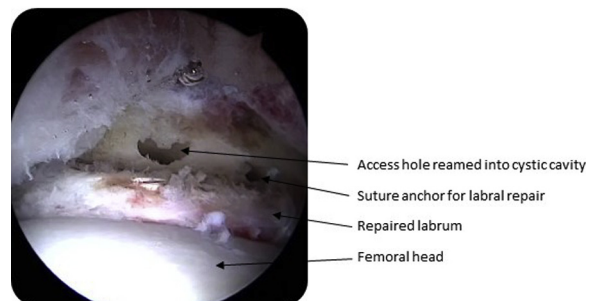
overlap with healthy cartilage. Once satisfied with the layer of cartilage-based graft, a fibrin sealant (Tisseel; Baxter, Deerfield, IL) is applied over the cartilage scaffold, overlapping with the native cartilage walls and labrum to create a sealed layer over the graft (Figs 21 and 22). Once the fibrin sealant has stabilized, traction is released and the hip joint is reduced (see Video 1 for demonstration of technique).

### Rehabilitation

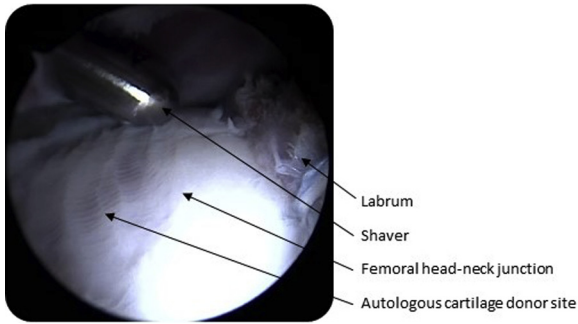
The patient is instructed to use flat-foot touch-down weight-bearing with crutches for 6 weeks. Gradual progression to full weight-bearing without crutches when pain is controlled and patient exhibits normal pelvic-femoral mechanics, generally around 8 weeks. Rehabilitation focuses on pain control, gentle muscle activation and preventing hip flexor tightness. The gradual introduction of strengthening exercises are based on individual progress and patient activity goals.

### Discussion

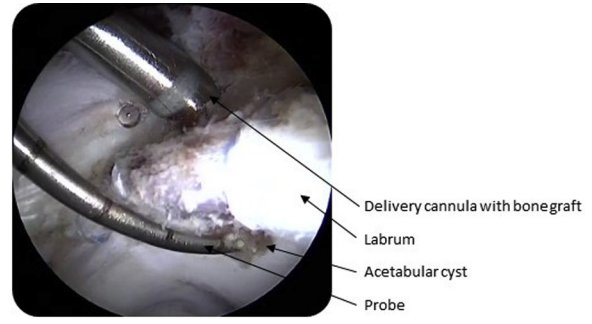
Using modern biologic techniques, acetabular defects of both the cartilage and subchondral bone may be



**Fig 13.** Arthroscopic view of a supine left hip from the peripheral compartment after acetabular preparation and labral repair. With the access hole, cyst and cartilage defects all prepared, traction may now be released and the hip reduced into the acetabulum.



**Fig 14.** Arthroscopic view of a supine left hip showing the head-neck junction from the peripheral compartment with the hip reduced. A motorized shaver is used to harvest healthy cartilage from the femoral head-neck junction. An autologous tissue collector (GraftNet; Arthrex) is attached to the suction tubing to collect the cartilage. The chamber containing the cartilage graft is then set on the back table.

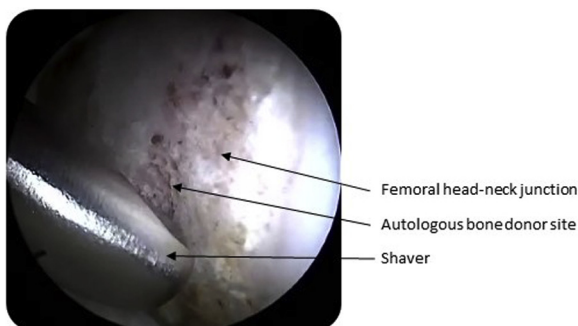


**Fig 16.** Arthroscopic view of a supine left hip in the central compartment showing the labrum and articular surface after re-establishing traction. The harvested bone graft mixed with bone marrow aspirate concentrate is injected via the delivery cannula and the access hole in the acetabular rim. Note, a probe is used to help impact the mixture as it fills the cavity and remove any air or fluid pockets that remain.

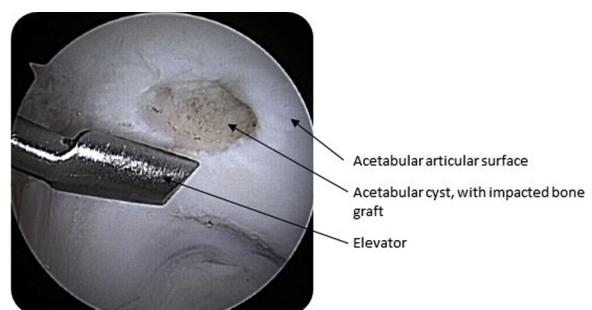
addressed arthroscopically and with autologous bone and cartilage. These techniques build on previously established methods of using allogeneic sources to restore cartilage defects.<sup>5-8</sup> Previously, these arthroscopic techniques have used allograft or commercial products. By using a particulate graft for both cartilage and bone defects, a scaffold can be created to whichever consistency is desired. This scaffold, mixed with bone marrow aspirate concentrate or autologous blood solution, has necessary porosity for a patient's own cellular interaction with high surface area yet uncompromised structural integrity. In addition, moldable graft substrates are better able to meet the situational demands of the procedure and may be adjusted to surgeon preference.

There are many advantages to this method. Using autologous tissue has the added benefit of the hosts' own cells without the risk of disease transmission. Accessing the acetabular defect with an outside-in

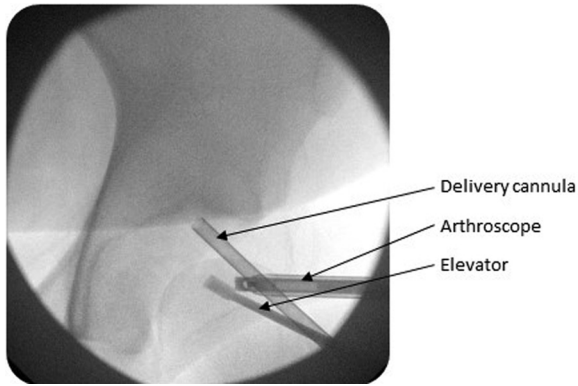
technique can minimize the disruption of articular cartilage at the cyst aperture. Jamali et al.<sup>5</sup> presented a similar technique for bone grafting of acetabular and femoral head bone cysts with use of bone substitute or demineralized bone matrix. However, our technique avoids burring into the cyst, maintaining osseous integrity near the weight-bearing dome. Garabekyan et al.<sup>6</sup> described the use of a curved shaver as a cannula to deliver bone graft into a cyst via the articular surface. This technique prevents graft extrusion out of a secondary egress in the cyst but may limit access to hard-to-reach cysts and adds the risk of iatrogenic cartilage damage. Field et al.<sup>7</sup> described an outside-in technique using a synthetic osteochondral plug placed by drilling through the ilium. This arthroscopic-assisted technique provides structural support but removes significantly more bone. Our described autologous mixture, using a combination of straight and curved cannulated applicators, can be delivered with minimal bone reaming. Finally, this technique has the added benefit of simplicity for the surgeon and technologist in the



**Fig 15.** Arthroscopic view of a supine left hip in the peripheral compartment demonstrating a bone-cutting shaver collecting bone from the femoral head-neck junction with an empty collection chamber to keep the harvested cartilage and bone separate. Any further osteochondroplasty for a cam lesion is performed at this time with a motorized burr.



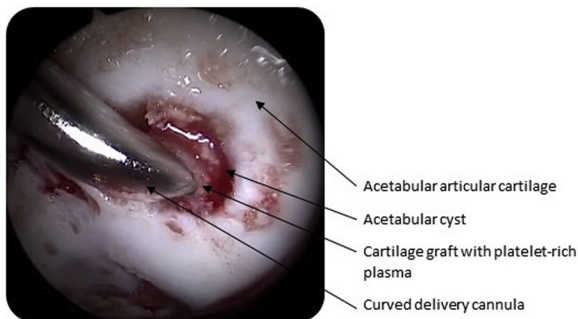
**Fig 17.** Arthroscopic view in the central compartment of a supine left hip showing the acetabular articular surface after filling the subchondral cyst with bone graft. An arthroscopic elevator can be used to shape or flatten the bone graft at the cartilage defect site.



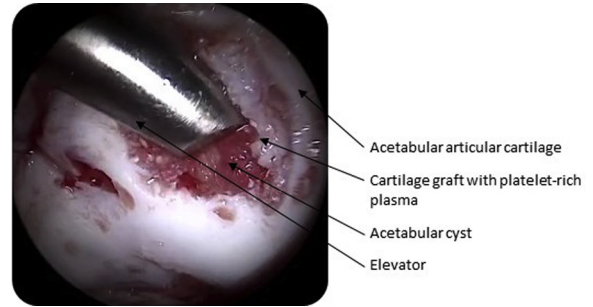
**Fig 18.** Intraoperative fluoroscopic image of the left hip joint in the supine position with delivery cannula in the access hole on the acetabular rim and an elevator in the central compartment to manage any graft extrusion.

operating room. The steps involved are similar to many established osteochondral repair techniques. These steps can be added to a comprehensive arthroscopic approach to concomitantly address labral pathology, synovitis and femoroacetabular impingement without the additional morbidity of an open procedure.

There are disadvantages to our described technique. Drilling a second opening into a cyst as an access hole may limit the ability to impact bone graft without graft extrusion, though this has not been an issue for us. Also, localizing cysts about the acetabulum may prove difficult and fluoroscopy is frequently needed to assist. This adds radiation to the pelvic region which is always a concern as these cysts are often found in younger populations. Although we use autologous tissues, this matrix is not a mature scaffold as can be provided by 2-stage techniques. Our single-stage procedure is less cost prohibitive and can provide an autologous scaffold for cartilage regeneration without the morbidity of a second procedure. Other limitations of this technique include time management as well as traction-related



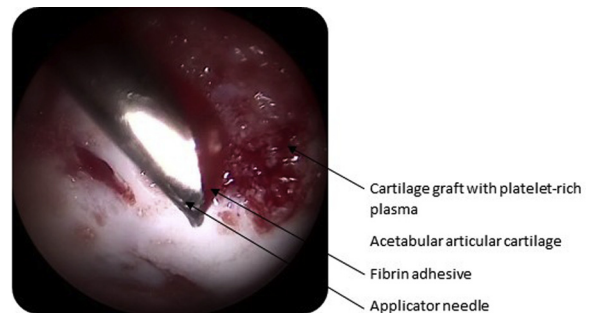
**Fig 19.** Arthroscopic view of a supine left hip showing the acetabular articular surface with arthroscopic fluid suctioned out of the joint. A curved delivery cannula is used to inject a mixture of autologous cartilage graft and platelet-rich plasma into the cartilage defect on top of the bone graft that has filled an acetabular cyst.



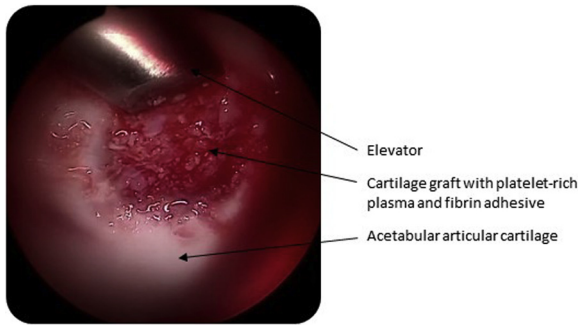
**Fig 20.** Arthroscopic view of a supine left hip in the central compartment showing the acetabular articular surface while an elevator is used to flatten and shape the cartilage graft to fill the chondral defect and remove any excess graft from adjacent cartilage.

complications during the learning curve of these arthroscopic techniques. Also, as with many cartilage restoration procedures, this technique requires specialized equipment and personnel which may be cost-prohibitive in some facilities. The pearls and pitfalls of this technique are shown in [Table 1](#), and the advantages and disadvantages are shown in [Table 2](#).

Acetabular cysts are an increasingly recognized finding during hip arthroscopy and may correlate to overall outcome. Krych et al.<sup>9</sup> found preoperative magnetic resonance imaging findings of acetabular edema or cystic changes correlated with grade IV cartilage lesions in 91% of their cohort at the time of arthroscopy. Hartigan et al.<sup>10</sup> performed a retrospective review of a case series of patients with subchondral cysts and found 59% of acetabular cysts had an associated grade III or IV chondral defect at the time of arthroscopy. Although these patients still had improvement in outcomes scores postoperatively, the authors noted those patients with subchondral cysts had a greater likelihood of converting to total hip.<sup>10</sup> Filling and covering a cyst in the weight-bearing



**Fig 21.** Arthroscopic view of a supine left hip in the central compartment showing the acetabular articular surface with a grafted acetabular cyst. An applicator needle is used to coat the cartilage graft with fibrin adhesive. This is placed generously over the cartilage defect, overlapping the adhesive onto adjacent cartilage and labrum to create a continuous biological layer.



**Fig 22.** Arthroscopic view in the central compartment of a supine left hip showing the articular surface of the acetabulum, the repaired cartilage defect is shown overlying a filled cystic cavity.

region of the acetabulum may allow a distribution of forces as well as provide a biological environment favorable to cyst resolution. Changing the anatomic features of a cyst to create a more structurally favorable lesion may improve symptoms and long-term outcomes. This technique builds on previous publications by utilizing both autologous bone and cartilage grafting from local sources to treat the structural and physiologic defects associated with acetabular cysts.

In conclusion, this autologous bone and cartilage grafting technique for acetabular defects has the flexibility to be adopted by many arthroscopic hip surgeons. It represents a comprehensive and anatomic solution to address the multifactorial nature of complex hip pathology. Painful cysts with chondral wear can be addressed at the time of primary surgery with minimal additional instrumentation. This procedure builds upon previously established techniques for cartilage and bone restoration and uses methods familiar to the

**Table 1.** Pearls and Pitfalls

Pearls	Pitfalls
All-arthroscopic technique to minimize morbidity	Prolonged operating time can lead to traction and swelling complications
Uses equipment familiar to surgeons such as bone marrow aspiration cannulas and cannulated reamers	Preoperative planning and advanced imaging are imperative to localize cyst
Potential to avoid use of allograft by using autologous tissue collecting	Patient must have adequate donor cartilage and bone to use autologous technique
Avoids a 2-stage cartilage restoration procedure	Allograft may be needed to increase bulk of graft material
Graft can be expanded with allograft for large defects	Creating appropriate viscosity of graft material for smooth application may require tailoring and adjustment

**Table 2.** Advantages and Disadvantages

Advantages	Disadvantages
Avoids open hip dislocation and removing excess bone around acetabulum as with other techniques	Cost of equipment and extra personnel may be cost-prohibitive
Can be added to a comprehensive arthroscopic procedure to address labral, synovial, impingement and other pathologies	Uses percutaneous techniques and instruments which may not be familiar to some surgeons
Ease of harvesting autologous tissue with minimal donor-site morbidity	Ability to tamp graft material may be limited by angle of approach and secondary egress hole
Autologous graft may have improved cellular interaction with host and decreased resorption/rejection	Must avoid placing suture anchors for labral repair in planned site of access hole, which may make repair difficult

arthroscopic surgeon to provide a safe and simple treatment for debilitating lesions.

**References**

- Bhatia S, Nowak DD, Briggs KK, Patterson DC, Philippon MJ. Outerbridge grade IV cartilage lesions in the hip identified at arthroscopy. *Arthroscopy* 2016;32:814-819.
- McCarthy JC, Jarrett BT, Ojeifo O, Lee JA, Bragdon CR. What factors influence long-term survivorship after hip arthroscopy? *Clin Orthop Relat Res* 2011;469:362-371.
- Maldonado DR, Rosinsky PJ, Shapira J, Domb BG. Stepwise safe access in hip arthroscopy in the supine position: Tips and pearls from A to Z. *J Am Acad Orthop Surg* 2020;28:651-659.
- Wright VJ, McCrum CL, Li H, Tranovich MJ, Huard J. Significant chondrocyte viability is present in acetabular chondral flaps associated with femoroacetabular impingement. *Am J Sports Med* 2018;46:149-152.
- Jamali AA, Fritz AT, Reddy D, Meehan JP. Minimally invasive bone grafting of cysts of the femoral head and acetabulum in femoroacetabular impingement: Arthroscopic technique and case presentation. *Arthroscopy* 2010;26:279-285.
- Garabekyan T, Chadayammuri V, Pascual-Garrido C, Meidan O. Arthroscopic bone grafting of deep acetabular cysts using a curved delivery device. *Arthrosc Tech* 2016;5:e113-e119.
- Field RE, Rajakulendran K, Strambi F. Arthroscopic grafting of chondral defects and subchondral cysts of the acetabulum. *Hip Int* 2011;21:479-486.
- Krych AJ, Lorch DG, Kelly BT. Treatment of focal osteochondral defects of the acetabulum with osteochondral allograft transplantation. *Orthopedics* 2011;34:e307-e311.
- Krych AJ, King AH, Berardelli RL, Sousa PL, Levy BA. Is subchondral acetabular edema or cystic change on MRI a contraindication for hip arthroscopy in patients with femoroacetabular impingement? *Hip Int* 2016;44:454-459.
- Hartigan DE, Perets I, Yuen LC, Domb BG. Results of hip arthroscopy in patients with MRI diagnosis of subchondral cysts—a case series. *J Hip Pres Surg* 2017;4:324-331.