

THE EFFECT OF SECONDARY INFECTIONS ON EXPERIMENTAL TRACHOMA*

By P. K. OLITSKY, M.D., R. E. KNUTTI, M.D., AND J. R. TYLER

(From the Laboratories of The Rockefeller Institute for Medical Research)

PLATES 25 AND 26

(Received for publication, January 30, 1931)

If it were possible to produce in monkeys the florid type of human trachoma commonly seen in practice, the evidence of the relation of experimental conjunctivitis to trachoma would be more convincing. The experiments to be reported here concern the rôle played by secondary infections in the experimental disease and particularly in the reproduction of the florid type of the disease in animals.

In this connection, we may cite an early observation by Muttermilch (1) (1909), based on clinical experience. He believes that trachoma is a mild disease and not dangerous to eyesight if the affection remains uncomplicated; that follicle and pannus formation are only complications and are not related to the causal agent; and that these distressing sequelae result from infection by many different bacteria.

Noguchi (2) and others (3, 4, 5, 6) have described the conjunctival lesions induced in *Macacus rhesus* monkeys and chimpanzees by the inoculation of *Bacterium granulosis* as closely resembling those of trachoma in man. These authors have also shown that tissues derived from cases of human trachoma or from monkeys having the experimental disease induce, on conjunctival inoculation in animals essentially the same clinical and pathological effects as do cultures of *Bacterium granulosis*. The early or acute aspect of human trachoma, illustrated by Noguchi on Plate 1 of his Supplement (2), was used as a standard for comparison with the clinical appearance of the experimental conjunctivitis. Observations of animals with lesions enduring for a period of 1 to over 3 years reveal that the experimentally induced conjunctivitis retains indefinitely its characteristic resemblance ordinarily to the early stage and only occasionally to the beginning of the florid stage of human trachoma. In terms of MacCallan's (7) comprehensive classifi-

* Presented before the American Association of Pathologists and Bacteriologists at Cleveland, Ohio, April 2, 1931.

cation of the clinical forms of the disease, the stages in the experimental conditions correspond to Type I and Type II a .

MacCallan's classification of conjunctival involvement, based on extensive experience with trachoma in Egypt and in England, is as follows:

Type I, usually seen soon after infection, is characterized by the presence in the conjunctiva of follicles chiefly of the tiny, grey, pin-head type, sparsely scattered, and more prominent on the upper membrane.

Type II is a later development and has three subtypes. In (*a*) there is predominance of enlarged follicles. In (*b*) papillary hypertrophy may exist with the follicles. Red, raspberry-like papillae, or elevations, mask the typical gelatinous follicles and occur more markedly on the upper conjunctiva. In still another subtype (*c*), also known as florid trachoma, the disease is characterized by a dark red, tumefied, velvety appearance of the conjunctiva, accompanied by mucopurulent discharges. In some cases the individual follicles can no longer be distinguished, becoming merged into a general infiltration. The condition may subside spontaneously or persist for several months if untreated.

Type III represents the stage in which cicatrization has begun and Type IV, also known as "cured trachoma," that in which scarring is complete.

Inasmuch as in the experimental disease, no corneal lesions have as yet been produced, those changes which deal with corneal involvement are not here described.

Through the cooperation of several ophthalmologists,¹ nine patients with trachoma have been available for study. The excised conjunctival tissue or expressed follicles or secretions of these patients showed by culture and in stained film preparations a large number and variety of bacteria. *Staphylococcus albus*, diphtheroids, *Bacillus xerosis*, and a Gram-negative chromogenic bacillus predominated.

In only seven of the nine cases did we obtain material sufficient in amount and fresh enough for cultivation experiments to disclose the presence of *Bacterium granulosis*. Of the seven, four yielded pathogenic cultures of *Bacterium granulosis* and the conjunctival tissue of these four, inoculated into monkeys, produced in each instance characteristic experimental granular conjunctivitis. Cultures were made in turn from the conjunctival tissue of two of the monkeys so affected and *Bacterium granulosis* was recovered in both instances. The conjunctival tissue from three patients, which failed to yield growths of the microorganism, was also injected into two or three monkeys in each instance. The tissue from one of these patients induced the characteristic granular conjunctivitis; cultures from one of the monkeys thus affected yielded no growth of *Bacterium granulosis*.

¹ We are deeply indebted for material to Drs. Martin Cohen, Arnold Knapp, Ervin Torok, and Julius Wolff, all of New York City.

Various bacteria have been mentioned (7) as occurring during the florid stage of trachoma in man—bacteria which may be regarded as secondary, in view of the fact that Noguchi (2) and ourselves have found them to be devoid of pathogenicity for monkeys and to be indiscriminately associated with the pathogenic *Bacterium granulosis*. As yet, however, no definite evidence has been obtained as to their significance in human trachoma and in the experimental disease.

Materials and Methods

Test Animals.—There were available nine *Macacus rhesus* monkeys showing lesions resembling Type I or Type IIa human trachoma as a result in two instances of subconjunctival inoculation with human trachomatous tissue, and in the other seven of inoculation with cultures of *Bacterium granulosis*. In all, the disease had been progressing over a period of from 2 to 7 months before secondary organisms were implanted experimentally upon the diseased conjunctivae. In addition, five normal monkeys with clear conjunctivae were used as controls for determining the effects of inoculation of the secondary bacteria alone.

Microorganisms for Secondary Inoculation.—The bacteria selected to produce secondary infection consisted of some of those usually encountered in the cultivation of conjunctival tissue from trachoma or other conjunctival affections of man and monkey. They were a Gram-positive diphtheroid, *Staphylococcus albus*, *Bacillus xerosis*, a chromogenic and a spore-bearing bacillus, both Gram-negative, and a non-hemolytic streptococcus.

*Method of Inoculation.*²—The growths were suspended in the condensation water of the tubes, and the turbid fluids were removed by means of pipettes and pooled. To the mixture an equal volume of 0.9 per cent salt solution was added. The application of the culture mixtures to the conjunctivae by daily swabbing over long periods yielded no results in either the monkeys with *granulosis* lesions or the controls, and even the subconjunctival inoculation of 0.2 cc. of the mixtures failed, in most instances, to induce infection.

We then turned to the use of testicular extract (8) for the purpose of enhancing the pathogenic action of the bacteria (9). To suspensions of organisms like those employed previously was added an equal amount of testicular extract (8) and 0.2 cc. of the mixture was forthwith injected subconjunctivally into the animals. The inoculation was repeated twice or thrice at intervals of 3 to 4 weeks. Infection promptly resulted.

Results of Secondary Infection

Clinical Effects.—Immediately after the injection of the mixture of bacteria and testicular extract, a marked, acute conjunctivitis de-

² All operations were done under full ether anesthesia.

veloped. The eyelid became so edematous and thickened that its eversion for the purpose of examining the conjunctiva was extremely difficult. The skin of the lid sometimes became discolored from subcuticular hemorrhage and localized abscess formation occasionally supervened. After a week the inflammation subsided, and the upper lid and conjunctiva showed, in place of the granular type of reaction, certain marked changes of another kind.

On examining the eyes at this time, a slight greyish yellow discharge was noted, which dried in small flakes on the eyelashes and margins of the lids. At times there was definite ptosis of the upper lid. The upper tarsal conjunctiva was deep red in color, edematous, and thickened, and as a consequence the individual follicles were less prominent than in the granular stage. The edema, thickening, the gelatinous follicles buried in the infiltrated mass of conjunctiva which added a peculiar lustre to the tissue gave rise to a distinct velvety appearance of the tarsal mucosa. Here and there were slight projections of the mucosa which were the result of papillary hypertrophy. The vascular structure, which is seen normally and in certain cases of the granular type of conjunctivitis, was completely obscured. In the upper cul-de-sac, the mucosa was thickened and hyperemic, and the enlarged follicles appeared as slight, rounded elevations, somewhat paler than the surrounding deep red coloration. Expression of these follicles, which appeared like sago grain, yielded a small amount of grumous, greyish, soft material. In the lower lid changes were usually not pronounced: the original granular condition was slightly exaggerated and was accompanied by moderate edema of the tissues. In two of the monkeys, however, changes similar to those occurring in the upper mucosa were noted in the uninoculated eye 2 months after secondary infection was induced, thus indicating a natural extension of this infection. Pannus and lid deformities due to scar tissue formation have not as yet been observed.

In general, the clinical appearance of the animals closely resembled that of Type II*b* and *c* (MacCallan (7)) of human trachoma and agreed with the description given by Morax (10) and others of the florid type of the disease. Two instances of the florid type of the experimental affection are shown in Figs. 1 and 2, and, by way of contrast, a drawing of characteristic, uncomplicated, granular conjunctivitis induced by *Bacterium granulosis* is reproduced in Fig 3.

The condition produced by implantation of secondary infection upon experimental granular conjunctivitis continued with only slight remissions from 3 to 7 months, when it was terminated in three monkeys by removal of tissue for study by means of tarsectomy. Four other animals died at periods from 3 to 7 months from tuberculosis and two are still under observation.

In control monkeys the injection of the bacterial mixture was followed by an acute inflammatory reaction consisting of edema and thickening of the eyelids, with an occasional subcuticular hemorrhage and localized abscess formation. The inflammation subsided within a week, leaving the upper and lower conjunctivae somewhat thickener by edema and infiltration. The vascular structure of the mucosa then appeared sharply defined and apart from slight roughness of its surface no papillary or follicular hypertrophy was noticeable (Fig. 4).

Bacteriological Findings.—At the termination of the observations, cultivation tests were made with the conjunctival tissue removed from six of the nine test animals and from one of the controls. With the exception of the Gram-negative spore-bearing bacillus and the streptococcus, bacteria similar to the secondary microorganisms which had been inoculated were recovered from the monkeys. Three of the nine animals yielded *Bacterium granulosis* in culture—a result which was not surprising in view of the fact that the lesions induced by the original inoculation of *Bacterium granulosis* had been present for several months before the secondary infection. One of three monkeys yielding the microorganism had shown lesions for 14 months and two for 11 months. That *Bacterium granulosis* can be recovered from chronic experimental conjunctivitis of long standing (3 years) has already been demonstrated by Tilden and Tyler (4, 11), a finding correlated with the presence of the bacterium in chronic human cases of trachoma of several years' duration (2, 6, 11, 12, 13).

Pathological Changes.—The histopathology of chronic, uncomplicated, granular conjunctivitis induced in monkeys by inoculation of *Bacterium granulosis* has already been described by Noguchi (2). Its resemblance to the microscopic changes resulting from injection of human trachomatous tissues in monkeys has recently been reported (12).

The conjunctival tissue of six monkeys with the florid type of trachomatous conjunctivitis, after secondary infection, was examined microscopically and the changes, mainly follicular and papillary, were found to be strikingly similar to those occurring in florid, Type II*b* and *c* human trachoma (Figs. 5 and 6).

In certain areas, particularly in the cul-de-sac, the epithelium was thickened, the cells were swollen and pale, and huge goblet cells were seen. Infrequent mitotic figures were present. Occasional lymphocytes were buried among the epithelial cells, but in the subepithelial layer there was well marked lymphocytic infiltration. Other areas, especially over the follicles, revealed a thinning or a denudation of the epithelium. Here polymorphonuclear leucocytes invaded the remains of necrotic epithelial cells, and the subepithelial structure. Microorganisms of different species could be seen, singly or in an agglomeration, intra- and extracellularly. Many lymphocytes and a few large mononuclear phagocytic cells were scattered about. Numerous connective tissue cells occurred beneath the surface, among which could be found many lymphocytes.

The follicles, similar to those of human trachoma, consisted of large focal collections of tightly packed lymphocytes, some surrounded by a very thin, fibrous tissue capsule. Few mitotic figures were seen, and the number of large mononuclear cells in the center was much less than in the uncomplicated experimental disease. In some of the follicles connective tissue cells could be observed extending inward among the lymphoid cells, while in others there occurred almost complete replacement by scar tissue.

While the deforming effects on the eyelids and their appendages of scar tissue replacement have not as yet been observed in the experimental animals, microscopic examination revealed a considerable degree of fibrosis.

In the control monkeys, those in which secondary microorganisms were injected into the clear conjunctivae, the reaction was one of acute exudative inflammation. The superficial epithelium was denuded, or if attached showed degeneration of the nucleus and cytoplasm to the degree of complete necrosis. In the subepithelial tissue, an exudation of cells, chiefly polymorphonuclear leucocytes and a few large mononuclear cells, occurred. The capillaries were distended, and here and there a small hemorrhage could be seen. Many of the polymorphonuclear and large mononuclear cells contained bacteria. There was no lymphocytic reaction and no scar tissue or follicle formation. The lesion was therefore distinct from that found in the test monkeys (Fig. 7).

The evidence is clear that the predominant reactions in the experimental disease, like those in human trachoma, are lymphoid and papillary hyperplasias associated with processes of definite scar tissue replacement. The pathological changes may therefore be considered

as those of the florid or Type IIb and c trachoma of MacCallan's terminology.³

In another series of tests a culture of *Bacterium granulosis* was inoculated into the smooth conjunctivae of two monkeys, and the same culture plus an equal amount of the testicular extract suspension of the secondary microorganisms into two other animals. Two additional monkeys served as controls to the action of the secondary bacteria alone. The latter animals revealed the acute inflammatory reaction already described. All four monkeys receiving *Bacterium granulosis* with or without secondary microorganisms developed the conjunctivitis characteristic of *granulosis* alone, without any distinctive differences in the two pairs of animals.

It appears from the foregoing experiment that the florid type of trachoma can be produced experimentally by secondarily infecting conjunctivae which show follicular lesions. The simple mixture of *Bacterium granulosis* and other microorganisms may induce only the effects of the pathogenic constituent, namely, the *granulosis* organism, and the process is comparable to the action in the conjunctiva of affected tissues from man or monkey, in which there is usually an admixture of the pathogenic microorganism with different bacteria. The procedure can be likened to that of injecting pneumonia (pneumococcus) sputum into the susceptible mouse.

SUMMARY

The possibility suggested itself, in view of the theories already advanced with regard to the rôle of secondary infections in the later manifestations of trachoma (1), that the implantation of common

³ It has been implied recently (14) that atropine can induce follicular conjunctivitis and that this condition should not be confused with trachoma. We have injected subconjunctivally two monkeys with 0.2 cc. of 0.5 per cent solution of atropine sulfate. Both monkeys showed, after 24 hours, considerable edema of the eyelids and acute hemorrhagic conjunctivitis. After 5 days the inflammation subsided, except for the persistence of retrotarsal hemorrhages, and after 3 weeks the eyes were practically normal. A week later both monkeys were reinoculated subconjunctivally, this time with a *Bacterium granulosis* culture. From 20 to 30 days thereafter, they developed characteristic experimental granular conjunctivitis. The atropine effect was therefore wholly unlike the experimental disease induced by the microorganism.

bacteria on the conjunctivae of monkeys already having well marked characteristic *granulosis* lesions might give rise to a condition showing less predominance of the follicular reaction and more of the hyperemic granulopapillary effect. We believe we have succeeded, by a suitable technique, in doing this and in producing thereby in the experimental animals a condition closely resembling the florid type of human trachoma (Type II*b* and *c* of MacCallan). The organisms used were some of those which are found in the conjunctival sac of monkey and man with different types of granular conjunctivitis. Of themselves, they produced only a transient reaction or none, as Noguchi had already shown and as we ourselves had observed in control animals. When inoculated together with material containing *Bacterium granulosis*, they did not affect the usual action of this organism, but when introduced into a conjunctiva in which *granulosis* lesions were already well developed, they induced more of the characteristics of the florid stage of trachoma than have been hitherto observed in animals, notably increased hyperemia, edema and thickening, papillary hypertrophy, obscurity of blood vessels, and masking of the follicles. Microscopically these changes were accompanied by increased scar tissue formation, lymphoid infiltration, and papillary hyperplasia.

CONCLUSIONS

By introducing secondary infections in monkeys already showing characteristic granular conjunctivitis following inoculation of human trachomatous tissues or cultures of *Bacterium granulosis*, it is possible to bring about a condition in which the clinical appearance closely resembles that of florid human trachoma.

Secondary infection appears to be important in the pathogenesis of the experimental disease, since by it a reaction which is mainly follicular can be converted into a still more severe and destructive hyperemic, granulopapillary type. In this respect an analogue may be found to trachoma in man.

We wish to express our gratitude to Dr. Martin Cohen, without whose active cooperation these studies could not have been made.

BIBLIOGRAPHY

1. Muttermilch, J., *Arch. Ophthalm.*, Leipsic, 1909-1910, **73**, 384.
2. Noguchi, H., *J. Exp. Med.*, 1928, **48**, suppl. 2, 1-53.
3. Tyler, J. R., *Science*, 1929, **70**, 612.
4. Tilden, E. B., and Tyler, J. R., *Science*, 1930, **71**, 186; *J. Exp. Med.*, 1930, **52**, 617.
5. Olitsky, P. K., and Tyler, J. R., *Science*, 1930, **71**, 263, 564.
6. Olitsky, P. K., *Rev. Internat. Trachome*, 1930, **7**, 173.
7. MacCallan, A. F., *Lancet*, 1926, **211**, 919; Trachoma and its complications in Egypt, Cambridge University Press, London, 1913, 1-74.
8. Duran-Reynals, F., *Compt. rend. Soc. biol.*, 1928, **99**, 6; *J. Exp. Med.*, 1929, **50**, 327.
9. Pijoan, M., *J. Exp. Med.*, 1931, **53**, 37.
10. Morax, V., and Petit, P. J., *Le trachome*, Jean Morax, Paris, 1929.
11. Tilden, E. B., and Tyler, J. R., *J. Exp. Med.*, 1929, **52**, 617.
12. Olitsky, P. K., *Proc. Am. Acad. Ophthalm. and Otolaryngol.*, in press; *Gior. Batt. e. Immunol.*, 1931, in press.
13. Finnoff, W. C., and Thygeson, P., *Am. J. Ophthalm.*, St. Louis, 1929, **12**, 651.
14. McCartney, J. E., and Mayou, M. S., System of bacteriology, Medical Research Council, London, 1930, **7**, 244.

EXPLANATION OF PLATES

PLATE 25

FIGS. 1 to 4. Conjunctivae of *Macacus rhesus* monkeys enlarged to twice natural size.

FIG. 1. Secondary infection of chronic granular conjunctivitis following subconjunctival inoculation (January 9, 1930) of a culture of *Bacterium granulosis* derived from a case of trachoma in New York City. Duration of secondary infection 5 months.

FIG. 2. Conjunctiva of another monkey treated in the same way. The sago-like follicles mentioned in the text should be noted. Duration of secondary infection 6 months.

FIG. 3. Uncomplicated chronic granular conjunctivitis resulting from subconjunctival inoculation of *Bacterium granulosis* derived from a case of human trachoma. The drawing was made 65 days after inoculation. To be compared with Figs. 1 and 2 which show the results of secondary infection produced in monkeys having originally lesions similar to those of Fig. 3.

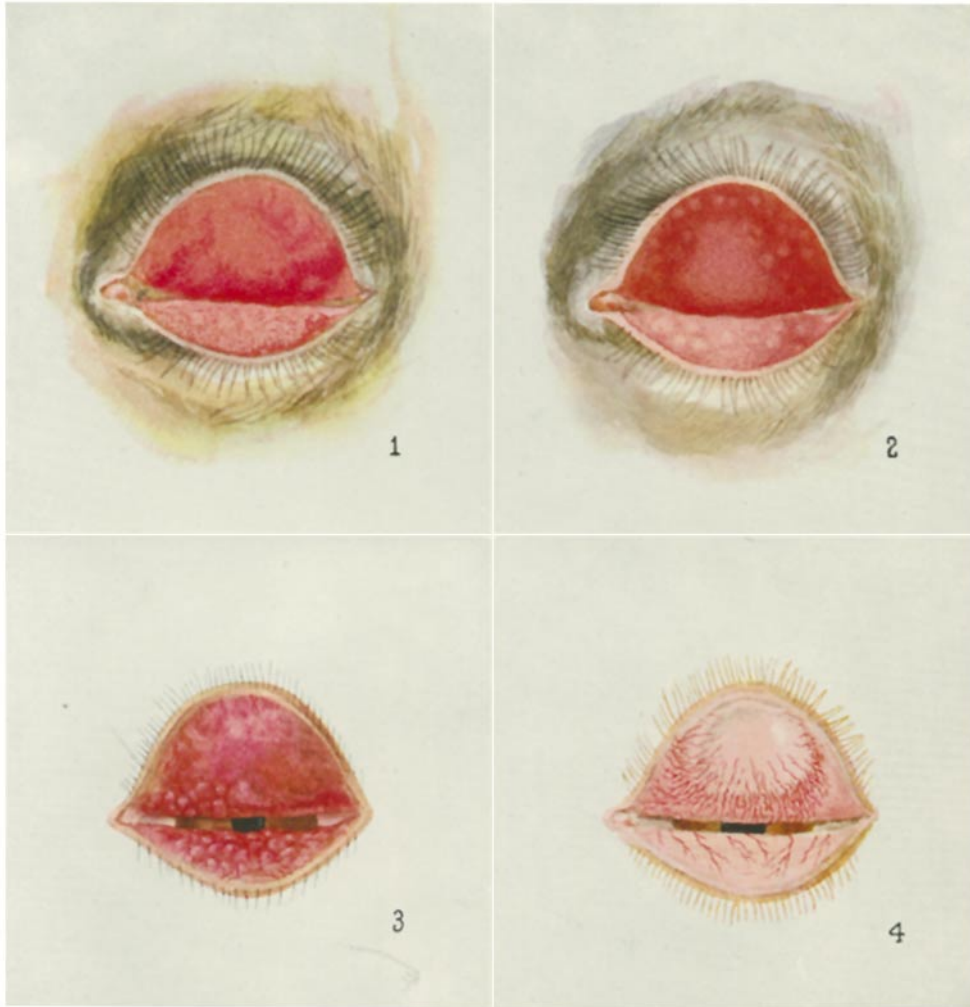FIG. 4. The effect of subconjunctival inoculation of the ordinary bacteria found in the conjunctiva of man and the monkey. Control animal to those of the series represented in Figs. 1 and 2.

PLATE 26

FIG. 5. Histopathological changes in conjunctiva of a monkey with secondary infection of chronic granular conjunctivitis. To be noted are two follicles and the changes described in the text. Duration of secondary infection 5 months. Hematoxylin-eosin stain. $\times 125$.

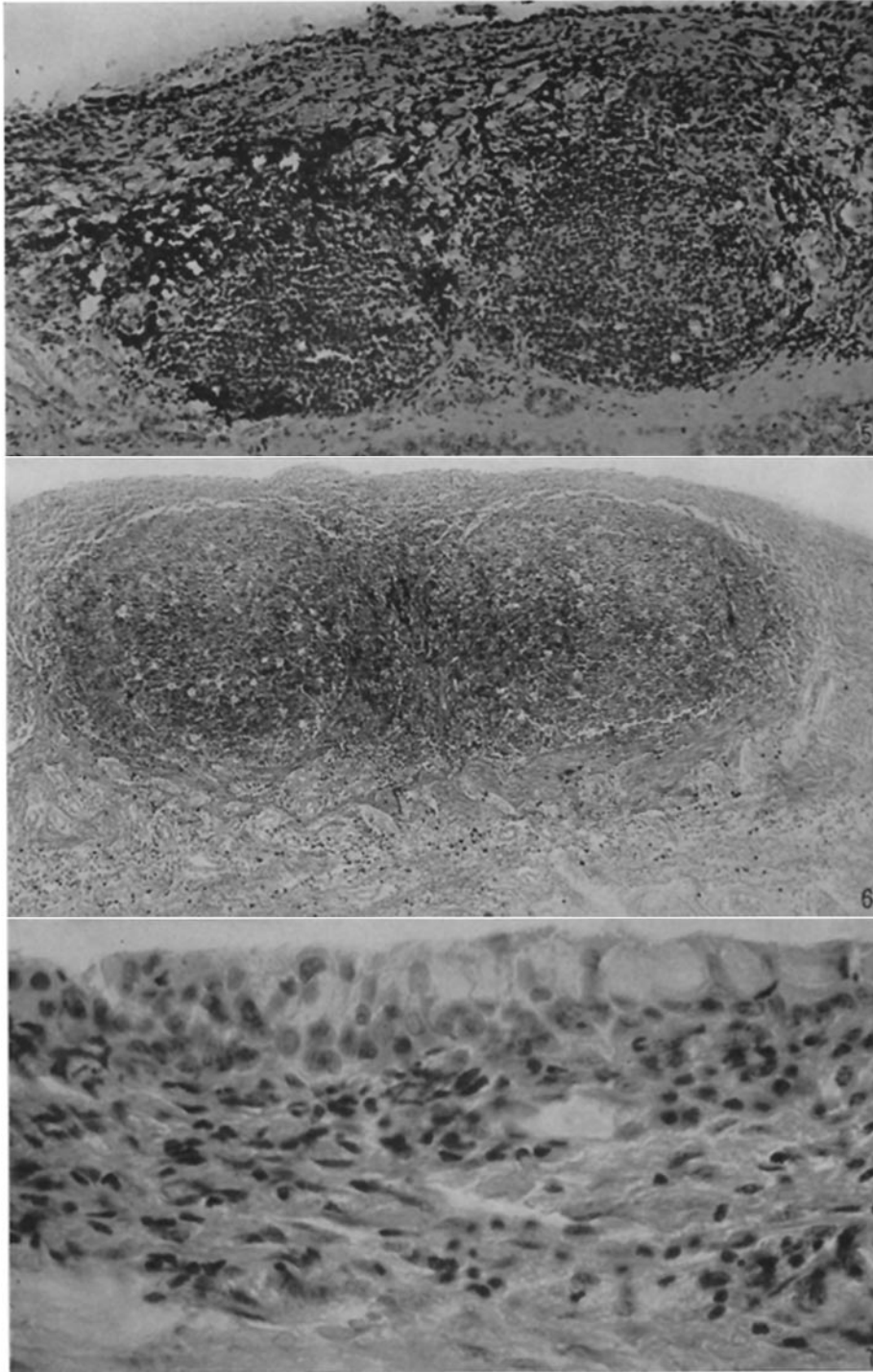
FIG. 6. Similarly, from a case of florid human trachoma, of about 2 years' duration. Same stain. $\times 60$. To be compared with Fig. 5.

FIG. 7. Conjunctiva of a control monkey similar to that shown in Fig. 4. There was no evidence of follicle formation. Conjunctiva removed 7 months after the initial, and 34 days after the last injection of secondary microorganisms. Same stain. $\times 500$.



Painted by L. Schmidt and M. L. Hedge

(Olitsky *et al.* : Secondary infections and trachoma)



(Olitsky *et al.*: Secondary infections and trachoma)