

Bioptic prostatic inflammation correlates with false positive rates of multiparametric magnetic resonance imaging in detecting clinically significant prostate cancer

Ugo Giovanni Falagarino^{1,2}, Marco Recchia¹, Giovanni Silecchia³, Paola Milillo⁴, Alessia Francavilla⁴, Salvatore Mariano Bruno¹, Oscar Selvaggio¹, Gian Maria Busetto¹, Francesca Sanguedolce⁵, Luca Macarini⁴, Giuseppe Carrieri¹, Luigi Cormio^{1,3}

¹Department of Urology and Organ Transplantation, University of Foggia, Foggia, Italy

²Department of Urology, Icahn School of Medicine at Mount Sinai, New York, USA

³Department of Urology, Bonomo Teaching Hospital, Andria (BAT), Italy

⁴Department of Radiology, University of Foggia, Foggia, Italy

⁵Department of Pathology, University of Foggia, Foggia, Italy

Citation: Falagarino UG, Recchia M, Silecchia G, et al. Bioptic prostatic inflammation correlates with false positive rates of multiparametric magnetic resonance imaging in detecting clinically significant prostate cancer. Cent European J Urol. 2021; 74: 308-314.

Article history

Submitted: March 13, 2021

Accepted: May 25, 2021

Published online: July 7, 2021

Corresponding author

Ugo Giovanni Falagarino
Department of Urology
and Renal Transplantation
University of Foggia,
Foggia, Italy
1 viale Pinto
71100 Foggia, Italy
fax: +39 0881 732111
ugofalagarino@gmail.com

Introduction The aim of this article was to determine the impact of bioptic prostatic inflammation (PI) on the false positive rate of multiparametric magnetic resonance imaging (mp-MRI) in detecting clinically significant prostate cancer (csPCa).

Material and methods Our prostate biopsy database was queried to identify patients who underwent mp-MRI before PB at our institution. A dedicated uropathologist prospectively assessed bioptic PI using the Irani scores. We evaluated the association between mp-MRI findings, bioptic Gleason grade (GG) and aggressiveness of PI, and PCa detection.

Results In total, 366 men were included. In patients with Prostate Imaging Reporting and Data System (PIRADS) 4-5 lesions, the csPCa (GG ≥ 2) rate was significantly higher in those with low-grade than in those with high-grade PI (36% vs 29.7%; $p = 0.002$), and in those with low-aggressive than in those with high-aggressive PI (37.7% vs 30.1%; $p = 0.0003$). The false positive rates of PIRADS 4-5 lesions for any PCa were 34.2% and 57.8% for low- and high-grade PI, respectively ($p = 0.002$); similarly, they were 29.5% and 59.4% for mildly and highly-aggressive PI ($p = 0.0003$). Potential study limitations include its retrospective analysis and single-center study and lack of assessment of the type of PI.

Conclusions Bioptic PI directly correlates with false positive rates of mp-MRI in detecting csPCa. Clinicians should be aware that PI remains the most common pitfall of mp-MRI.

Key Words: prostate cancer \leftrightarrow prostatic inflammation \leftrightarrow multiparametric magnetic resonance imaging \leftrightarrow prostate biopsy

INTRODUCTION

Prostate cancer (PCa) screening using prostate-specific antigen (PSA), has been shown to reduce PCa mortality [1] but PSA is not specific for PCa. Indeed, benign conditions such as prostatic inflammation (PI) and benign prostatic hyperplasia (BPH) can increase PSA levels leading to a large number of negative prostate biopsies (PBs) or to overdiagno-

sis of indolent cancers that may result in overtreatment with significant morbidity [2].

To reduce the rate of negative PBs as well as the risk of overdiagnosis and overtreatment of indolent PCa, current guidelines recommend using pre-biopsy multiparametric magnetic resonance imaging (mpMRI) [3].

Although level 1 evidence is now available supporting the use of mpMRI target biopsy to improve the

detection of clinically significant PCa (csPCa), defined as Gleason grade (GG) ≥ 2 according to International Society of Urological Pathology (ISUP) recommendations [4], in biopsy-naive and repeat-biopsy settings, mpMRI has some limitations. First, in a recent Cochrane meta-analysis which compared mpMRI to template biopsies (>20 cores) in biopsy-naive and repeat-biopsy settings, mpMRI had a pooled sensitivity of 0.91 (95% CI: 0.83–0.95) but a low pooled specificity of 0.37 (95% CI: 0.29–0.46) for ISUP grade ≥ 2 cancers with up to 44% (95% CI: 38 to 50%) of the patients being false positive [5]. Second, despite technological advances in MRI scanner technology, and the effort of the Prostate Imaging Reporting and Data System (PI-RADS) Steering Committee to standardize parameters for image acquisition and radiology reports [6], mpMRI's inter-reader reproducibility remains moderate at best, which currently limits its broad use by non-dedicated radiologists [7].

The intrinsic physical properties of the image formation process using mpMRI can explain some of the limitations of this technique. Because the mpMRI image is dependent upon the cellular distribution and the mobility of the water molecules, it can be easily understood that certain non-neoplastic conditions may be misdiagnosed as neoplastic lesions when they are characterized by sufficiently large accumulations of isolated cells in a liquid medium as occurs in inflammatory processes or glandular atrophy [8].

The present study therefore aimed to determine whether grade and aggressiveness of PI, as histologically assessed by the Irani score [9], correlate with false positive rates of mpMRI in detecting csPCa at PB.

MATERIAL AND METHODS

Study population

After Institutional Review Board approval, we queried our prospectively maintained prostate biopsy database to identify patients who underwent mpMRI, PB, and Irani Scores assessment between April 2017 and February 2020. The study was part of a wider prospective, single center, observational study evaluating the role of intraprostatic inflammation in prostate cancer screening and treatment. The protocol was carried out in agreement with the provisions of the Declaration of Helsinki. Written informed consent to take part was given by all participants.

mpMRI protocol and biopsy technique

Prostate mpMRI was performed in patients with PSA higher than 3.0 ng/ml and/or suspicious digital rectal examination (DRE). All exams were per-

formed with a 1.5 Tesla MR scanner (Achieva, Philips Healthcare, Best, The Netherlands) using either a surface array coil (SENSE Flex surface), or an endorectal coil combined with a 16-channel surface coil (TORSO-XL coil). The mp-MRI protocol consisted of: A. T2-weighted images in axial, coronal and sagittal planes; B. T1-weighted images in axial plane; C. diffusion-weighted images in the axial plane (b-values 0–500–1000–1500/2000 sec/mm²); D. dynamic contrast enhanced prostate MRI performed using a T1-weighted high resolution isotropic volume examination (THRIVE) on the axial plane with injection of 0.1 ml/kg of gadobutrol.

Two dedicated radiologists reported all the images according to PIRADS v2.0 recommendations [10].

PIRADS 1 and 2 lesions were considered to be negative. In these patients, a transrectal ultrasound guided standard PB was performed using our 18-core template [11].

Patients with a positive mpMRI (PIRADS 3,4,5 lesions) received additional three target cores from each mpMRI-suspicious lesion using an electromagnetic-tracked MRI/US fusion system (Navigo, UC-CARE, Yokneam, ISR) [12] followed by standard 18-core biopsy. All procedures were carried out by urologists using local non-infiltrative anesthesia [13, 14]. Additional information on mpMRI protocol and PB technique have been previously reported [15].

Pathology examination

A senior uropathologist (FS) prospectively reported all PB specimens according to the 2014 ISUP recommendations [4] and diagnostic criteria for high-grade prostatic intraepithelial neoplasia and atypical small acinar proliferation of prostat [16]. ISUP Gleason-grade groups (GG) were reported per each core. Additionally, PI was assessed using the Irani Scores subsequently validated by Sciarra et al. [9, 17]. Specifically, the inflammatory infiltration grade was scored as 'G0' = no inflammatory cells, 'G1' = scattered inflammatory cell infiltrate within the stroma without lymphoid nodules, 'G2' = nonconfluent lymphoid nodules and 'G3' = large inflammatory areas with confluence of infiltrate. Inflammatory aggressiveness was graded as 'A0' = no contact between inflammatory cells and glandular epithelium (epithelium cells lining acini and ducts), 'A1' = contact between inflammatory cell infiltrate and glandular epithelium, 'A2' = interstitial inflammatory infiltrate associated with a clear but limited (less than 25% of the examined material) glandular epithelium disruption and 'A3' = glandular epithelium disruption on more than 25% of the examined material. Grading did not include the types of inflammatory cells (polymorpho-

Table 1. Clinical characteristics of the study population

Variable	Overall N = 366	Benign N = 203	GG 1 N = 84	GG ≥ 2 N = 79	P value
Age	67 (61, 71)	65 (59, 70)	68 (62, 71)	69 (64, 73)	0.0002
PSA	5.9 (4.5, 9.0)	5.9 (4.7, 8.8)	5.2 (4.1, 8.2)	6.9 (4.9, 13.4)	0.005
Biopsy history, n (%)					
Biopsy naive	206 (56.3%)	98 (48.3%)	55 (65.5%)	53 (67.1%)	0.003
Previous negative	160 (43.7%)	105 (51.7%)	29 (34.5%)	26 (32.9%)	
DRE, n (%)					
Negative	221 (60.4%)	138 (68.0%)	55 (65.5%)	28 (35.4%)	<0.0001
Suspicious	145 (39.6%)	65 (32.0%)	29 (34.5%)	51 (64.6%)	
Prostate volume	57 (40, 76)	64 (50, 87)	50 (39, 67)	41 (33, 58)	<0.0001
Irani G, n (%)					
0–1	251 (68.6%)	125 (61.6%)	67 (79.8%)	59 (74.7%)	0.004
2–3	115 (31.4%)	78 (38.4%)	17 (20.2%)	20 (25.3%)	
Irani A, n (%)					
0	189 (51.6%)	88 (43.3%)	54 (64.3%)	47 (59.5%)	0.002
≥ 1	177 (48.4%)	115 (56.7%)	30 (35.7%)	32 (40.5%)	

N – number; GG – Gleason grade; PSA – prostate-specific antigen; DRE – digital rectal examination

nuclear leukocytes, lymphocytes, monocytes or plasma cells). For the analysis, scores G 0–1 (low-grade inflammation) and G 2–3 (high-grade inflammation) were grouped whereas inflammatory aggressiveness was categorized as present (A ≥ 1) or absent (A 0).

Statistical analysis

The primary objective of the present study was to compare any PCa (GG ≥ 1) and csPC (GG ≥ 2) detection rates of mpMRI in patients with and without PI. Descriptive statistics was reported for the overall population and according to PB results. Continuous variables are reported as median and interquartile range and tested by the Mann-Whitney U-test, whereas categorical variables are reported as rates and tested by the Fisher's exact test or the chi-square test, as appropriate.

PCa detection rates were then reported according to PI-RADS score in the overall population and in patients with and without PI according to the IRANI A and G scores.

Statistical analyses were performed using Stata-SE 14 (StataCorp LP, College Station, TX, USA). All tests were 2-sided with a significance level set at $p < 0.05$.

RESULTS

A total of 366 men were eligible for the present analysis; 84 (23%) were diagnosed with GG 1 PCa and 79 (21.6%) with csPCa (GG ≥ 2). Their clinical characteristics are summarized in Table 1. Overall, patients with csPCa were older, had greater PSA and smaller prostate volume than those with benign prostate. In agreement with our previous findings [18], high-

Table 2. Biopsy results according to PI-RADS score

Pathology n (%)	PI-RADS 1-2 (N = 57)	PI-RADS 3 (N = 84)	PI-RADS 4 (N = 182)	PI-RADS 5 (N = 43)
Benign	48 (84.2%)	63 (75.0%)	75 (41.2%)	17 (39.5%)
GG 1	8 (14.0%)	20 (23.8%)	48 (26.4%)	8 (18.6%)
GG ≥ 2	1 (1.8%)	1 (1.2%)	59 (32.4%)	18 (41.9%)

PIRADS – Prostate Imaging Reporting and Data System; N – number;
GG – Gleason grade

grade inflammation was significantly more common in patients with benign prostate than in those with ISUP 1 and ISUP ≥ 2 PCa (38%, 20% and 25% respectively; $p = 0.004$). Highly aggressive inflammation was significantly more common in patients with benign prostate than in those with GG 1 and GG ≥ 2 PCa (57%, 36% and 40% respectively; $p = 0.002$).

The association between mpMRI findings and PB outcome is summarized in Table 2. Since the rates of csPCa were 32% and 42% for PIRADS 4 and 5, respectively, mpMRI was falsely positive in 68% and 58% of PIRADS 4 and 5 cases, respectively.

Figures 1 and 2 show the association between grade and aggressiveness of PI, mp-MRI findings and PB results. In patients with PIRADS 4 and 5 lesions, the csPCa rate was significantly higher in those with low-grade than in those with high-grade PI (36% vs 29.7%; $p = 0.002$), and in those with mildly aggressive than in those with highly aggressive PI (37.7% vs 30.1%; $p = 0.0003$). The false positive rates of PIRADS 4 and 5 lesions for any PCa were 34.2% and 57.8% for low- and high-grade PI, respectively ($p = 0.002$); similarly, they were 29.5% and 59.4% for mildly and highly aggressive PI ($p = 0.0003$).

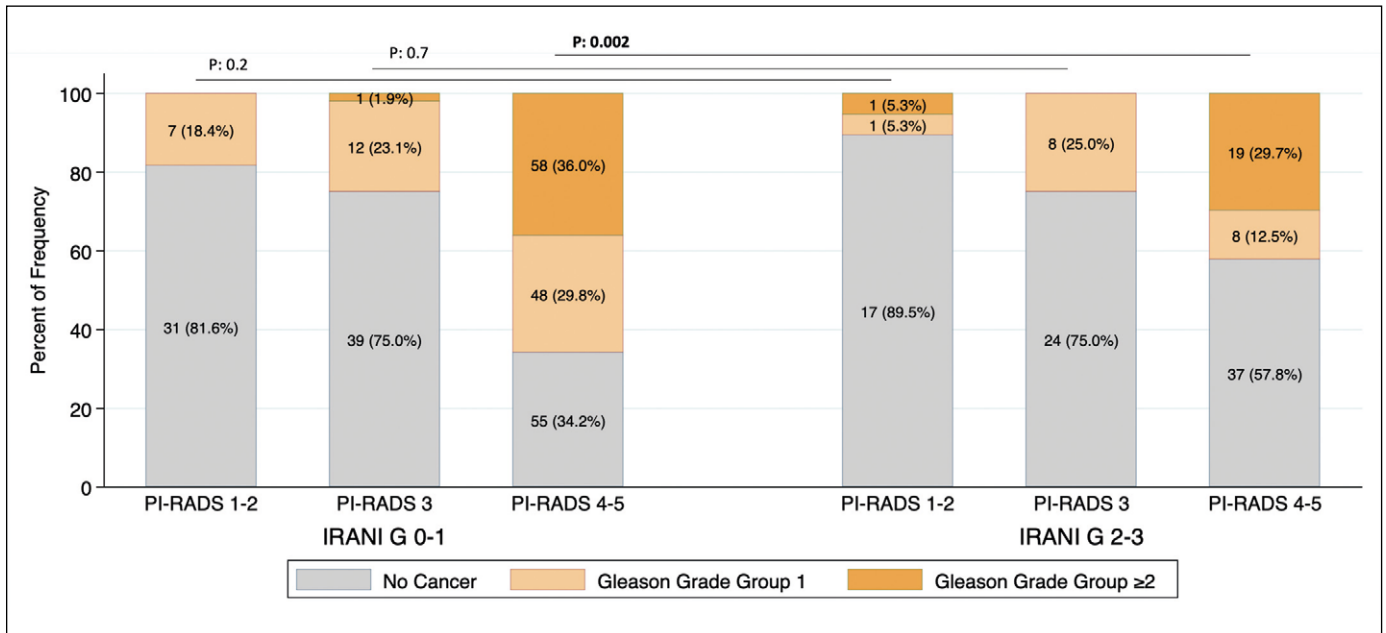


Figure 1. Prostate cancer detection rates according to PI-RADS score and inflammation grade (Irani G score).

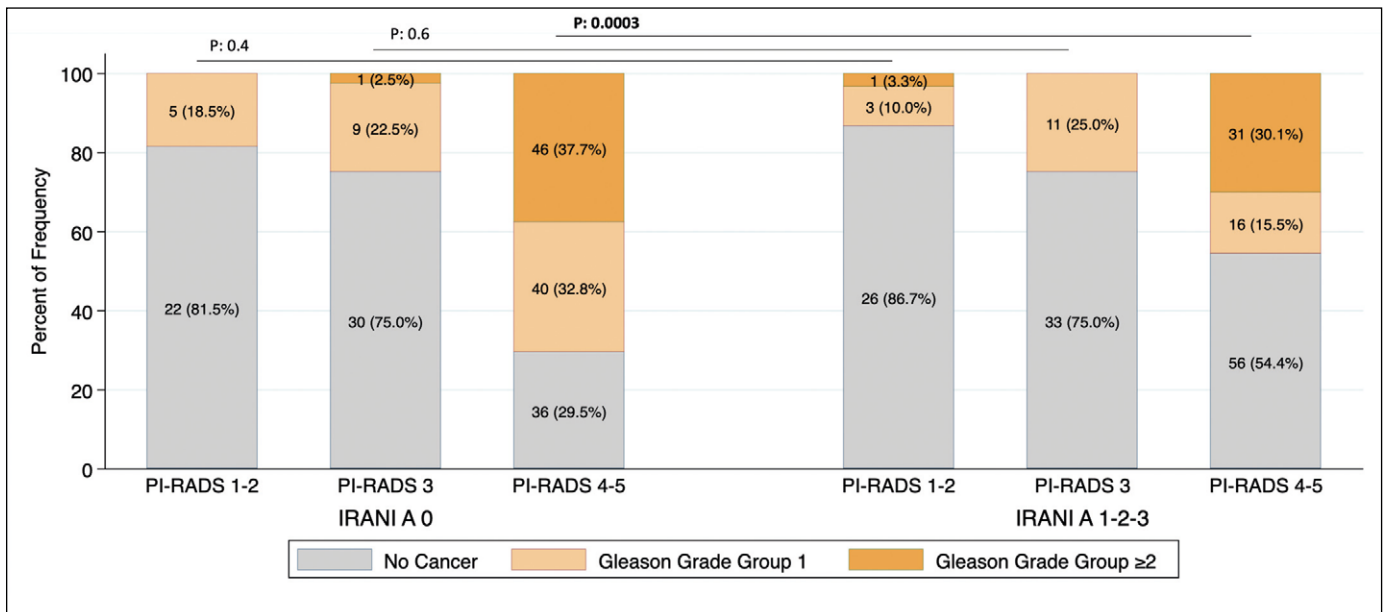


Figure 2. Prostate cancer detection rates according to PI-RADS score and inflammation aggressiveness (Irani A score).

PI-RADS- Prostate Imaging Reporting and Data System

DISCUSSION

Over the last years, mpMRI has gained popularity as the most efficient tool in predicting csPCa at PB [19]. Based on the results of the Cochrane metanalysis, the risk of missing csPCa in patients with a negative mp-MRI is very low [2.7% (95% CI: 1.5% to 5.1%)] [5]. If such a high sensitivity and negative predictive value (NPV) should allow clinicians to safely avoid

or postpone PB in patients with a negative mp-MRI, its low specificity, nearly 44% (95% CI: 38 to 50%) of PIRADS 4 and 5 lesions are falsely positive, leads to a large number of unnecessary PBs [5]. There are two possible explanations for the latter finding. First, predictive values of a diagnostic test depend on disease prevalence; thus, mp-MRI in very low-risk patients would result in an inflation of false-positive findings and subsequent unnecessary biop-

sies. Second, concomitant conditions can mimic the presence of cancer, again leading to false-positive findings. Specifically, PI has been reported to be associated with both a lower prevalence of csPCa and with a histological phenotype that might appear suspicious on MRI scans [20].

The present study demonstrated a strong direct association between grade and aggressiveness of PI and false positive rates of PIRADS 4 and 5 lesions at mp-MRI in detecting csPCa. To the best of our knowledge this is the largest study testing this issue and the first using the Irani scores, which are the only validated scores for PI. Indeed, available literature provides little information regarding the association between mp-MRI and histological findings in terms of PCa and PI.

Rourke et al. retrospectively evaluated data of 43 patients who underwent MRI/US target biopsy, showing that 70% of 61 MRI targetable lesions were false positive with more than 50% showing inflammation on prostate biopsy pathology examination [21]. Jyoti et al. evaluated 143 patients who underwent in-bore MRI target PB. Non-specific PI was present in 27% of all biopsied lesions and was more frequent in PIRADS 3 (58%) than in PIRADS 4 (39%) and 5 (3%) lesions [22].

Rosenkrantz and Taneja described PI as one of the most common pitfalls of prostate MRI causing signal abnormalities on any of the sequences included in a multiparametric MRI examination. Moreover, they suggested that the morphology of a peripheral zone lesion may be useful to stratify the level of suspicion that the lesion represents tumor rather than a benign inflammatory process [23]. For instance, a well-defined lesion with a nodular appearance should be considered of greater suspicion for tumor [24]. On the other hand, inflammatory lesions are generally less mass-like in morphology, exhibiting margins that are ill defined or linear rather than rounded in appearance. In addition, prostatitis may have a lobar distribution or involve the peripheral zone diffusely [24] and low apparent diffusion coefficient (ADC) values [25]. Accordingly, Merat et al. pointed out that mean ADC values were the best marker to differentiate between csPCa/non csPCa in severe prostatitis [26].

While our study provides a strong evidence for a direct association between PI and false positive rates of PIRADS 4 and 5 mp-MRI lesions in detecting PCa, questions remain on how we can predict and thus possibly reduce such diagnostic pitfalls. Current European Association of Urology (EAU) guidelines [3] highlight the increasing potential relevance of biomarkers and risk calculators (RC). The 4kscore, STHLM3 test and PHI test proved to be useful

in screening those men at risk of PCa, thus reducing the risk of false positive results at mp-MRI [27, 28, 29]. Similar findings apply to the ERSPC-RC and the PBCG-RC [27]. Moreover, since PI has been linked to the presence and severity of BPH and lower urinary tract symptoms [18], PSA density and novel risk calculators including BPH-related parameters [30, 31] might help to select candidates for mp-MRI. Future studies should focus on the development of specific biomarkers for prostatic inflammation.

At least 2 potential limitations of our study need to be acknowledged and possibly addressed in future research. First, this is a single-center retrospective study carried out at a tertiary referral center; therefore, our findings need to be prospectively and externally validated. Second, PI was assessed by a single pathologist using hematoxylin and eosin stained PB cores. Although the validated Irani scores were used, grading did not include the types of inflammatory cells (polymorphonuclear leukocytes, lymphocytes, monocytes or plasma cells).

CONCLUSIONS

This study first pointed out that PI directly correlates with false positive rates of mp-MRI in detecting PCa, particularly of PIRADS 4 and 5 lesions resulting into csPCa. Clinicians should be aware that PI remains the most common pitfall of mp-MRI and should make efforts to identify biomarkers or other tools such as risk calculators that, by predicting PI, may reduce false positive findings at mp-MRI, and thus the number of unnecessary PBs.

FUNDING

This research did not receive any specific grant from funding agencies in the public, commercial, or non-profit sectors.

CONFLICTS OF INTEREST

The authors declare that there are no conflicts of interest regarding the publication of this article.

AVAILABILITY OF DATA AND MATERIAL

Data from the present study are available upon request.

RESEARCH INVOLVING HUMAN PARTICIPANTS AND/OR ANIMALS

The present study that involved human participants data was approved by University of Foggia ethical committee (143/CE/2020, 30.11.2020). The study protocol was carried out in agreement with the provisions of the Declaration of Helsinki.

INFORMED CONSENT

Written informed consent to take part was given by all participants.

References

1. Schroder FH, Hugosson J, Roobol MJ, et al. Screening and prostate cancer mortality: results of the European Randomised Study of Screening for Prostate Cancer (ERSPC) at 13 years of follow-up. *Lancet*. 2014; 384: 2027-2035.
2. Loeb S, Carter HB, Berndt SI, Ricker W, Schaeffer EM. Complications after prostate biopsy: data from SEER-Medicare. *J Urol*. 2011; 186: 1830-1834.
3. Mottet N, van den Bergh RCN, et al. EAU-ESTRO-ESUR-SIOG Guidelines on Prostate Cancer 2020. European Association of Urology Guidelines 2020 Edition. presented at the EAU Annual Congress Amsterdam 2020. Arnhem, The Netherlands: European Association of Urology Guidelines Office; 2020.
4. Epstein JI, Egevad L, Amin MB, et al. The 2014 International Society of Urological Pathology (ISUP) Consensus Conference on Gleason Grading of Prostatic Carcinoma: Definition of Grading Patterns and Proposal for a New Grading System. *Am J Surg Pathol*. 2016; 40: 244-252.
5. Drost FJH, Osses DF, Nieboer D, et al. Prostate MRI, with or without MRI-targeted biopsy, and systematic biopsy for detecting prostate cancer. *Cochrane Syst Rev*. 2019; 4: CD012633.
6. Weinreb JC, Barentsz JO, Choyke PL, et al. PI-RADS Prostate Imaging-Reporting and Data System: 2015, Version 2. *Eur Urol*. 2016; 69: 16-40.
7. Rosenkrantz AB, Ginocchio LA, Cornfeld D, et al. Interobserver Reproducibility of the PI-RADS Version 2 Lexicon: A Multicenter Study of Six Experienced Prostate Radiologists. *Radiology*. 2016; 280: 793-804.
8. Truong M, Hollenberg G, Weinberg E, Messing EM, Miyamoto H, Frye TP. Impact of Gleason Subtype on Prostate Cancer Detection Using Multiparametric Magnetic Resonance Imaging: Correlation with Final Histopathology. *J Urol*. 2017; 198: 316-321.
9. Irani J, Levillain P, Goujon JM, Bon D, Dore B, Aubert J. Inflammation in benign prostatic hyperplasia: correlation with prostate specific antigen value. *J Urol*. 1997; 157: 1301-1303.
10. Muller BG, Shih JH, Sankineni S, et al. Prostate Cancer: Interobserver Agreement and Accuracy with the Revised Prostate Imaging Reporting and Data System at Multiparametric MR Imaging. *Radiology*. 2015; 277: 741-750.
11. Cormio L, Scattoni V, Lorusso F, et al. Prostate cancer detection rates in different biopsy schemes. Which cores for which patients? *World J Urol*. 2014; 32: 341-346.
12. Silecchia G, Falagario U, Sanguedolce F, Macarini L, Autorino R, Cormio L. Multiparametric magnetic resonance imaging/transrectal ultrasound fusion-guided prostate biopsy: A comparison with systematic transrectal ultrasound-guided prostate biopsy. *J Gerontol Geriatr*. 2018; 2018: 200-204.
13. Cormio L, Pagliarulo V, Lorusso F, et al. Combined perianal-intrarectal (PI) lidocaine-prilocaine (LP) cream and lidocaine-ketorolac gel provide better pain relief than combined PI LP cream and periprostatic nerve block during transrectal prostate biopsy. *BJU Int*. 2012; 109: 1776-1780.
14. Cormio L, Lorusso F, Selvaggio O, et al. Noninfiltrative anesthesia for transrectal prostate biopsy: a randomized prospective study comparing lidocaine-prilocaine cream and lidocaine-ketorolac gel. *Urol Oncol*. 2013; 31: 68-73.
15. Falagario UG, Silecchia G, Bruno SM, et al. Does Multiparametric Magnetic Resonance of Prostate Outperform Risk Calculators in Predicting Prostate Cancer in Biopsy Naive Patients? *Front Oncol*. 2020; 10: 603384.
16. Sanguedolce F, Cormio A, Musci G, et al. Typing the atypical: Diagnostic issues and predictive markers in suspicious prostate lesions. *Crit Rev Clin Lab Sci*. 2017; 54: 309-325.
17. Sciarra A, Di Silverio F, Salciccia S, et al. Inflammation and chronic prostatic diseases: evidence for a link? *Eur Urol*. 2007; 52: 964-972.
18. Falagario U, Selvaggio O, Carrieri G, Barret E, Sanguedolce F, Cormio L. Prostatic inflammation is associated with benign prostatic hyperplasia rather than prostate cancer. *JGG*. 2018; 2018: 178-182.
19. Wajswol E, Winoker JS, Anastos H, et al. A cohort of transperineal electromagnetically tracked magnetic resonance imaging/ultrasonography fusion-guided biopsy: assessing the impact of inter-reader variability on cancer detection. *BJU Int*. 2020; 125: 531-540.
20. Panebianco V, Giganti F, Kitzing YX, et al. An update of pitfalls in prostate mpMRI: a practical approach through the lens of PI-RADS v. 2 guidelines. *Insights Imaging*. 2018; 9: 87-101.
21. Rourke E, Sunnapwar A, Mais D, et al. Inflammation appears as high Prostate Imaging-Reporting and Data System scores on prostate magnetic resonance imaging (MRI) leading to false positive MRI fusion biopsy. *Investig Clin Urol*. 2019; 60: 388-395.
22. Jyoti R, Jina NH, Haxhimolla HZ. In-gantry MRI guided prostate biopsy diagnosis of prostatitis and its relationship with PIRADS V.2 based score. *J Med Imaging Radiat Oncol*. 2017; 61: 212-215.
23. Rosenkrantz AB, Taneja SS. Radiologist, be aware: ten pitfalls that confound the interpretation of multiparametric prostate MRI. *AJR Am J Roentgenol*. 2014; 202: 109-120.
24. Shukla-Dave A, Hricak H, Eberhardt SC, et al. Chronic prostatitis: MR imaging and 1H MR spectroscopic imaging findings--initial observations. *Radiology*. 2004; 231: 717-724.
25. Watanabe Y, Nagayama M, Araki T, et al. Targeted biopsy based on ADC map in the detection and localization of prostate cancer: a feasibility study. *J Magn Reson Imaging*. 2013; 37: 1168-1177.
26. Merat S, Blumlein T, Klarhofer M, et al. Impact of Chronic Prostatitis on the PI-RADS Score 3: Proposal for the Addition of a Novel Binary Suffix. *Diagnostics (Basel)*. 2021; 11: 623.
27. Falagario UG, Martini A, Wajswol E, et al. Avoiding Unnecessary Magnetic Resonance Imaging (MRI) and Biopsies: Negative and Positive Predictive Value of MRI According to Prostate-specific Antigen Density, 4Kscore and Risk Calculators. *Eur Urol Oncol*. 2019.
28. Gronberg H, Eklund M, Picker W, et al. Prostate Cancer Diagnostics Using

- a Combination of the Stockholm3 Blood Test and Multiparametric Magnetic Resonance Imaging. *Eur Urol.* 2018; 74: 722-728.
29. Gnanapragasam VJ, Burling K, George A, et al. The Prostate Health Index adds predictive value to multi-parametric MRI in detecting significant prostate cancers in a repeat biopsy population. *Sci Rep.* 2016; 6: 35364.
30. Cormio L, Cindolo L, Troiano F, et al. Development and Internal Validation of Novel Nomograms Based on Benign Prostatic Obstruction-Related Parameters to Predict the Risk of Prostate Cancer at First Prostate Biopsy. *Front Oncol.* 2018; 8: 438.
31. Falagario UG, Jambor I, Lantz A, et al. Combined Use of Prostate-specific Antigen Density and Magnetic Resonance Imaging for Prostate Biopsy Decision Planning: A Retrospective Multi-institutional Study Using the Prostate Magnetic Resonance Imaging Outcome Database (PROMOD). *Eur Urol Oncol* 202; S2588-9311(20)30142. ■