

# Untreatable Surgical Site Infection: Consider Pyoderma Gangrenosum

Ilan Berlinrut, MD\*†  
 Nitasha Bhatia, MD\*†  
 Jonathan M. Josse, MD,  
 MSc†§  
 David de Vinck, DO†§  
 Sanjeev Kaul, MD†§

**Summary:** Pyoderma gangrenosum (PG) is an inflammatory disease characterized by sterile infiltration of the skin by neutrophils. We describe a case of a 63-year-old woman who developed PG following an abdominal wall reconstruction. Her initial presentation was thought to be consistent with a surgical site infection. Antibiotic therapy was initiated, and the patient was taken for multiple irrigation/lavage of her abdomen and debridement of necrotic tissue. Wound cultures remained negative, and maximal antibiotic coverage did not halt tissue breakdown. A trial of steroids was initiated, and the patient's condition subsequently improved. Tissue biopsy results were compatible with the diagnosis of PG. (*Plast Reconstr Surg Glob Open* 2014;2:e166; doi: 10.1097/GOX.0000000000000114; Published online 10 June 2014.)

**P**yoderma gangrenosum (PG) occurs in approximately 1 in 100,000 people each year.<sup>1</sup> PG primarily occurs between ages of 40 and 60 years. PG is often coincident in patients with systemic inflammatory disease (eg, arthritis, inflammatory bowel disease, and hematologic malignancies). PG is not a manifestation or complication of these diseases, rather it is a separate entity. The severity and duration of PG are not related to activity of the comorbid diseases.<sup>2</sup>

PG is considered a reactive neutrophilic dermatosis. It is believed that PG is caused by lymphocytic antigen activation resulting in cytokine release and

neutrophil recruitment. This results in marked soft-tissue necrosis.<sup>2</sup>

Lesions of PG are classified morphologically into 4 types: ulcerative (most common), bullous, pustular, and vegetative. Lesions can appear on normal skin or at sites of trauma (eg, pathergy). Pathergy complicates wound healing and surgical interventions by forming satellite lesions at skin manipulation sites. PG's hallmark violaceous lesions are progressive and may demonstrate central ulceration.<sup>2</sup> Histologically, lesions show neutrophilic infiltration, with abscess formation in the mid to deep dermis.<sup>2</sup> Tissue at the ulcer edge predominantly shows lymphocytic infiltrate. Lymphocytes may be seen infiltrating blood vessel walls with intramural or intravascular fibrin deposition.<sup>3</sup>

We present a case of PG following abdominal wall reconstruction. This case details the diagnosis and management of PG from what was previously believed to be a surgical site infection.

## CASE REPORT

The patient was a 63-year-old woman with a medical history significant for uterine carcinoma, status-post hysterectomy, and radiation therapy. Her condition was complicated by a 4 cm × 4 cm incision-

From the \*Department of Medical Education, St. George's University, Great River, N.Y.; †Department of General Surgery and ‡Department of Pathology, Hackensack University Medical Center, Hackensack, N.J.; and §Department of General Surgery, University of Medicine and Dentistry of New Jersey, Newark, N.J.

Received for publication March 4, 2014; accepted April 11, 2014.

Copyright © 2014 The Authors. Published by Lippincott Williams & Wilkins on behalf of The American Society of Plastic Surgeons. PRS Global Open is a publication of the American Society of Plastic Surgeons. This is an open-access article distributed under the terms of the Creative Commons Attribution-NonCommercial-NoDerivatives 3.0 License, where it is permissible to download and share the work provided it is properly cited. The work cannot be changed in any way or used commercially.

DOI: 10.1097/GOX.0000000000000114

**Disclosure:** The authors have no financial interest to declare in relation to the content of this article. The Article Processing Charge was paid for by the authors.

al hernia and radiation enteritis. She underwent a complex abdominal wall reconstruction using component separation technique and underlying porcine mesh. This operation involved extensive lysis of adhesions, cholecystectomy (due to incidental gallstones), and prophylactic appendectomy. Abdominal wall flaps were managed with Blake drain placement in each abdominal quadrant.

The patient tolerated the operation well and was transferred to an intermediate care, surgical unit. She had a smooth postoperative course until postoperative day (POD) 6 when erythema without discharge was noted around the incision. She was started on IV antibiotics, and appropriate sepsis workup was obtained. CT scanning demonstrated no significant fluid collections within the flap space or intra-abdominally.

On POD 7, purulent drainage appeared from the incision. She was taken to the operating room for exploration of the abdominal flaps with pulse irrigation, lavage, and placement of a negative pressure dressing. Intraoperative findings revealed necrotic dermis, viable adipose tissue, and intact abdominal fascia. Debrided tissue specimens were sent for culture and pathological analysis.

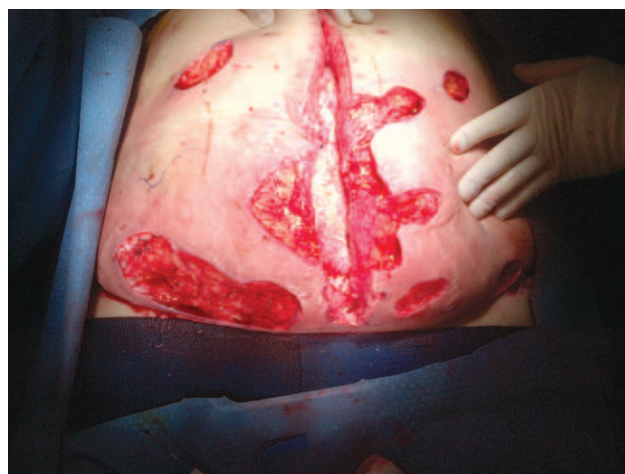The following day she continued to have high fevers with elevation of the white blood cell count. Tissue culture showed no organisms. Antibiotic coverage was broadened to include multiagent coverage.

Despite broad-spectrum antibiotics and multiple debridements, the abdominal wall necrosis continued to progress (Fig. 1). Additional diagnoses presenting with progressive skin necrosis were entertained, among them being PG. Steroid therapy for PG containment was considered alongside the option of complete resection of the abdominal wall. Ultimately, steroid therapy was initiated, and after 12 hours of IV glucocorticoid therapy, containment of erythema was noted. Surgical exploration revealed no progression of skin necrosis. Tissue biopsy results were compatible with the diagnosis of PG (Fig. 2).

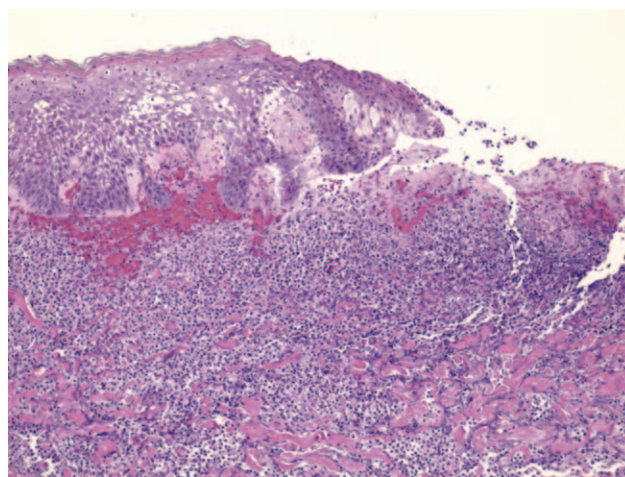
The patient continued to respond favorably to steroids and improved over the following 3 weeks. Before discharge, she received skin grafting of the residual skin defects and was discharged on POD 34 (Fig. 3).

## DISCUSSION

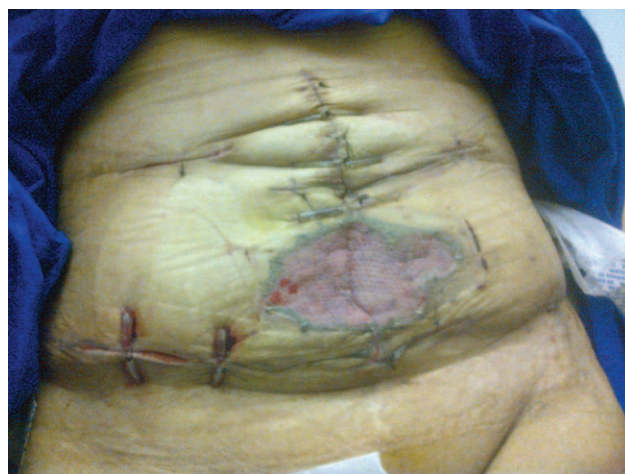The case represents an unusual etiology of postoperative fever and wound breakdown. The presentation of PG mimics an infectious process and is often misdiagnosed.<sup>4,5</sup> The suggested diagnostic criteria for PG are listed in Table 1.<sup>2</sup> The prognosis of PG is generally favorable.<sup>6</sup>



**Fig. 1.** The patient status post incision and drain site debridement. A large amount of erythema surrounding the wounds is also shown.



**Fig. 2.** Slide demonstrates epithelial necrosis and extensive infiltration of the dermis with neutrophils.



**Fig. 3.** Patient following steroid therapy and skin grafting.

**Table 1. Suggestive Diagnostic Criteria for pyoderma gangrenosum**

Major Criteria	Minor Criteria
1. Acute onset of painful lesion fitting morphological description of bullous, pustular, ulcerative, or vegetative PG. Patient typically afebrile, without toxemia	1. Lesions are localized at characteristic sites: bullous on upper limbs, pustular on trunk or face, ulcerative on lower extremities, and vegetative on the trunk. Lesions can also appear at sites of cutaneous trauma
2. On histology: The findings are often nonspecific or that of a neutrophilic dermatosis. Leukocytoclasia may be seen; however, well-developed vasculitis should be absent. Early lesions may show perivascular or perifollicular neutrophils that with time progress to ulceration with abundant neutrophils and tissue necrosis. Malignancy and infectious processes must be excluded	2. Quickly progressing inflammatory lesion with increasing severity of pain. Finding not typical in vegetative PG
3. Absence of vascular stasis, occlusion, or vasculitis as per diagnostic studies	3. Often coincidental in patients with systemic inflammatory disease (arthritis, inflammatory bowel disease, or hematologic dyscrasias). This association is not common in vegetative PG
	4. Administration of systemic steroid therapy provides rapid reduction of pain and inflammation

In a case by Bisarya et al,<sup>4</sup> PG on a patient's right leg was initially diagnosed as necrotizing fasciitis. With failure of antibiotic therapy and surgical control, PG was suspected. Further, Bennett et al<sup>5</sup> describe a patient with pustular lesions at the site of surgical release of tarsal tunnel syndrome misdiagnosed as cellulitis and abscess formation. A diagnosis of PG was suspected when pustular lesions developed at a separate skin graft donor site (ie, pathergy).

In our case, there was a similar emphasis on an infectious etiology. However, several findings should have led us away from this suspicion. On inspection of the wound, the pattern of tissue necrosis never extended beyond the dermis. The presence of satellite lesions at the Blake drain sites and continued local recurrence were suggestive of the pathergy phenomenon.<sup>7</sup> Surgical debridement in suspected PG is contraindicated. Pathergy is observed in approximately 25–50% of patients with PG.<sup>8</sup> We aggravated our patient's lesions through repeated debridement.

Another major detractor from an infectious etiology was that powerful antimicrobial agents had no effect on retarding the progression of the lesions. Furthermore, repeated negative wound cultures should have prompted a reexamination of our diagnosis.

A review of literature demonstrated no uniform therapy for PG.<sup>1,2,7</sup> The most commonly used protocol involves use of high-dose systemic corticosteroids; Prednisolone, 60 and 120 mg IV, is the initial treatment of choice.<sup>1,2,7</sup> We administered hydrocortisone 100 mg IV every 6 hours, with good effect. Additionally, cyclosporine can be used as an adjunct to steroids or, alternatively, if steroids fail. A dose of 3–5 mg/kg/d is usually used for 3 weeks.<sup>1,2,7</sup> However, 66% and 70% recurrence rates have been reported

in patients treated with cyclosporine and prednisolone, respectively.<sup>6</sup> PG has also been successfully treated with infliximab and combinations of corticosteroids and cytotoxic agents such as azathioprine.<sup>9,10</sup>

## CONCLUSIONS

PG is a rare inflammatory skin condition. The view that an infectious etiology was responsible delayed the diagnosis of PG. In patients with irregular, progressive surgical site lesions, yielding no organism on culture, unresponsive to antibiotics and source control measures, alternatives to infectious agents should be considered. Rapid patient improvement, in concert with confirmatory histological findings, established the diagnosis of PG. As there is no accurate assay for diagnosis of PG currently, the future development of such tests can possibly alleviate diagnostic delays and inappropriate surgical intervention.

**Ilan Berlinrut, MD**

St. George's University

3500 Sunrise Highway

Building 300, Great River, NY 11739

E-mail: iberlinr@sgu.edu

## REFERENCES

1. Jackson M. Pyoderma gangrenosum. Available at: <http://emedicine.medscape.com/article/1123821-overview>. Accessed June 17, 2013.
2. Powell FC, Hackett BC, Wallach D. Chapter 33: Pyoderma gangrenosum. In: Goldsmith LA, Katz SI, Gilchrist BA, et al, eds. *Fitzpatrick's Dermatology in General Medicine*. 8th ed. New York: McGraw-Hill; 2012. Available at: <http://www.accessmedicine.com/content.aspx?aID=56031301>. Accessed May 26, 2013.
3. Su WP, Schroeter AL, Perry HO, et al. Histopathologic and immunopathologic study of pyoderma gangrenosum. *J Cutan Pathol*. 1986;13:323–330.



4. Bisarya K, Azzopardi S, Lye G, et al. Necrotizing fasciitis versus pyoderma gangrenosum: securing the correct diagnosis! A case report and literature review. *Eplasty* 2011;11:e24.
5. Bennett CR, Brage ME, Mass DP. Pyoderma gangrenosum mimicking postoperative infection in the extremities. A report of two cases. *J Bone Joint Surg Am.* 1999;81:1013–1018.
6. Uwe W. Pyoderma gangrenosum—a review. *Orphanet J Rare Dis.* 2007;2:19.
7. Brooklyn T, Brooklyn T, Dunnill G, et al. Diagnosis and treatment of pyoderma gangrenosum. *BMJ* 2006;333:181–184.
8. Bennett ML, Jackson JM, Jorizzo JL, et al. Pyoderma gangrenosum. A comparison of typical and atypical forms with an emphasis on time to remission. Case review of 86 patients from 2 institutions. *Medicine (Baltimore)* 2000;79:37–46.
9. Ueda M, Katoh M, Tanizaki H, et al. Refractory pyoderma gangrenosum associated with ulcerative colitis successfully treated with infliximab. *Dermatol Online J.* 2012;18:12.
10. Rozin AP, Balbir-Gurman A, Gilead L, et al. Combined therapy for pyoderma gangrenosum. *Ann Rheum Dis.* 2004;63:888–889.