

Chromovitrectomy: an Update

Flora Hernández, MD; Natalia Alpizar-Alvarez, MD; Lihteh Wu, MD

Instituto de Cirugia Ocular, San José, Costa Rica

Adequate visualization and identification of the posterior hyaloid, epiretinal membranes and the internal limiting membrane are of paramount importance in modern vitreoretinal surgery. "Chromovitrectomy" is a term used for describing the vital dyes use in order to stain these transparent tissues and facilitate their manipulation during vitreous surgery. This article reviews the indications, applications and characteristics of vital dyes in vitreoretinal surgery. Various dyes are currently being used in routine clinical procedures, however the ideal staining agent has not yet been found. Any dye which is injected intravitreally has the potential to become toxic. Triamcinolone acetonide is used to highlight the vitreous and is particularly beneficial in determining the attachment of the posterior hyaloid to the underlying retina. Trypan blue stains epiretinal membranes and facilitates their complete removal. Both indocyanine green and brilliant blue G stain the internal limiting membrane properly, however concerns over indocyanine green toxicity have made surgeons switch to brilliant blue G as a safer alternative.

Keywords: Chromovitrectomy; Trypan Blue; Indocyanine Green; Brilliant Blue G; Internal Limiting Membrane; Posterior Hyaloid; Epiretinal Membrane

J Ophthalmic Vis Res 2014; 9 (2): 251-259.

Correspondence to: Lihteh Wu, MD. Calle 28 Avenida 2, Diagonal Sala Garbo, San José P.O. Box 144-1225 Plaza Mayor, San José, Costa Rica; Tel: +50 6 2256 2134, Fax: +50 6 2220 3502; e-mail: lw65@cornell.edu

Received: July 17, 2013

Accepted: August 18, 2013

The vitreous is composed of 98% water with the remainder consisting of macromolecules such as collagen fibrils and hyaluronan. Through aging, the vitreous undergoes several biochemical changes leading to progressive liquefaction of the vitreous gel which eventually results in a posterior vitreous detachment (PVD). An anomalous PVD may occur when there is no clean separation along the vitreoretinal interface.¹ Surgical, histopathological and imaging advances over the past two decades have demonstrated that traction along the vitreoretinal interface induced by an anomalous PVD plays an important role in several diseases. Depending on the position of the strongest vitreoretinal adhesion, an anomalous PVD may evolve into several clinical conditions.¹ For instance, a tear or detachment ensues from

the strongest adhesions in the retinal periphery. Epiretinal membranes (ERMs), macular holes (MHs) and vitreomacular traction syndrome (VMTS) may develop if strong adhesions are present in the macula.^{1,2} Release of this traction by removal of the offending tissues has been advocated as a solution for these conditions. The posterior hyaloid, ERM and internal limiting membrane (ILM) are three tissues which vitreoretinal surgeons encounter major difficulties in dealing with, since these tissues are usually thin, transparent and difficult to visualize.

Staining of these transparent tissues with vital dyes during vitrectomy greatly simplifies the procedure. "Chromovitrectomy" is a term employed to describe the use of vital dyes in order to stain transparent tissues and facilitate

their manipulation during vitreous surgery.³ Over the past decade, substances such as indocyanine green (ICG), trypan blue (TB) and brilliant blue G (BBG) have been used in vitrectomy with confirmed staining capabilities, but concerns over their retinal toxicity still remain.⁴

The toxic effects of any vital dye depends on its concentration, the osmolarity of the solution, dye exposure time and illumination time. To avoid toxicity a number of recommendations should be considered: the lowest concentration that will achieve staining should be used and dilutions with physiological osmolarities must rigorously be attained. The light pipe should remain far from the macula to avoid light toxicity and the photodynamic effect of the dye.⁴ Since the bare retinal pigment epithelium (RPE) in the floor of an MH may get in contact with the dye and sustain potential RPE toxicity, covering the hole with blood, viscoelastic or perfluorocarbon liquid is suggested.

Posterior Hyaloid

Traction exerted by the posterior hyaloid has been implicated in the pathogenesis of several conditions such as proliferative vitreoretinopathy (PVR), proliferative diabetic retinopathy (PDR), penetrating eye trauma and macular holes. Therefore the surgical goal of any vitrectomy should be posterior hyaloid separation and removal of the vitreous as much as possible. Despite the development of surgical techniques, at times the surgeon may not be confident that the posterior hyaloid has actually been removed.

In conditions characterized by breakdown of the blood retinal barrier such as PVR, uveitis, retinal vein occlusions and diabetic retinopathy, an intravenous injection of fluorescein sodium 1 to 2 days prior to the scheduled vitrectomy stains the vitreous green facilitating its identification.⁵

Blood in the vitreous cavity coats the vitreous by adhering to its collagen fibrils making the normally transparent vitreous opaque and easier to visualize for removal. In eyes with no pre-existing vitreous hemorrhage, a small amount of autologous blood may be injected into the vitreous cavity to coat the vitreous.⁶

Triamcinolone acetonide (TA) is a well-tolerated corticosteroid used for the treatment of diseases such as uveitis, diabetic macular edema (DME) and retinal vein occlusions. Once TA is injected into the vitreous cavity, its particles adhere to the vitreous gel facilitating visualization and identification (Figures 1 and 2).⁷ In addition, using TA may improve vitrectomy outcomes by reducing blood retinal barrier breakdown and preretinal fibrosis. Currently this is the most widely used technique to visualize the posterior hyaloid.^{4,6} A comparative study of fluorescein,

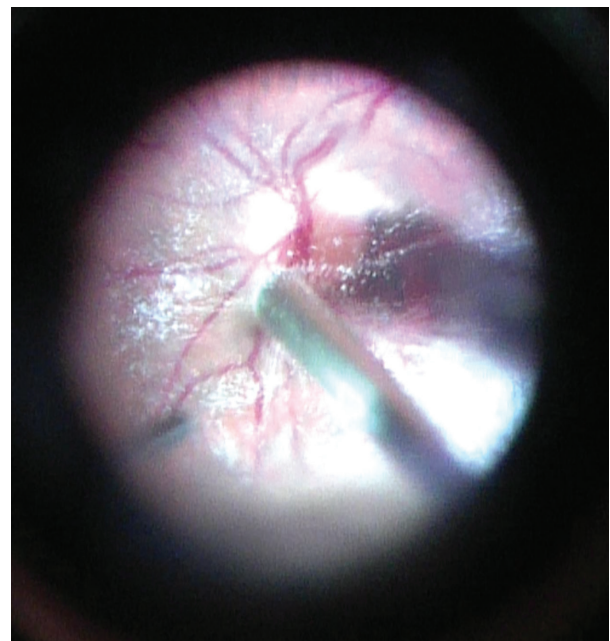


Figure 1. Triamcinolone acetonide particles adhere to the vitreous gel making its visualization and identification easy.

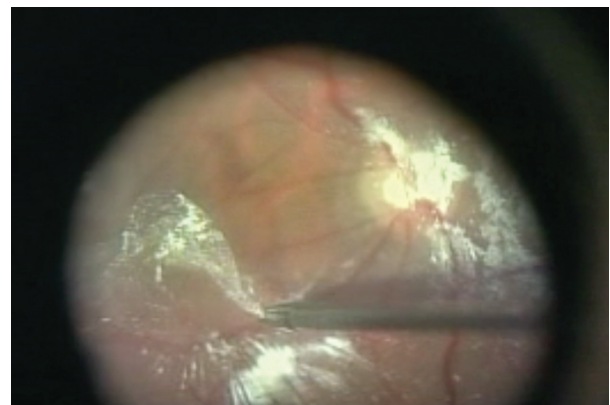


Figure 2. The adherence of triamcinolone acetonide particles demonstrates that the posterior hyaloid is still attached at the posterior pole.

ICG, TA and TB concluded that the vitreous was best highlighted by TA.⁸

A recent study demonstrated that a 20% solution containing the natural dyes lutein and zeaxanthin, precipitates on the vitreous surface staining it orange.⁹

Epiretinal Membranes

Over the past two decades owing to refinements in instrumentation and surgical techniques, ERM removal has been the typical indication for macular surgery. Clinically significant ERMs range from dense opaque tissues to fine transparent membranes. The transparent ERMs pose a challenge even to experienced surgeons since incomplete removal of the ERM is implicated in post-surgical recurrences¹⁰ which have been reported in up to 21% of cases.¹¹⁻¹³ Staining of the transparent ERM allows identification of its entire extent and facilitates its visualization and complete removal.

ERMs may also occur in the context of PVR. Surgical success depends on complete removal of the ERMs. Staining of these ERMs facilitates surgery by improving visualization, characterization of the ERM as diffuse or focal, and confirmation that the tissue requiring to be peeled is indeed an ERM and not swollen nerve fiber layer.¹⁴

Among the commercially available agents, TB is the dye of choice for ERM peeling.^{4,15} This dye binds to degenerated cell elements and does not stain live cells or tissues with intact cell membranes since there is no uptake of the dye. As ERMs are mostly composed of dead glial cells, TB exhibits strong affinity for them (Figure 3). Cataract surgeons have long used TB to stain the anterior capsule during phacoemulsification.¹⁶ ERMs stain prominently with 0.15% TB which is a relatively safe concentration.¹⁵ Histopathological analysis of excised ERM showed no retinal cells on the retinal side of the ERM and no signs of apoptosis. No RPE defects or signs of retinal toxicity have been reported in most studies as well.^{15,17,18} Nevertheless, animal and *in vitro* studies show that dose dependent toxicity may appear with concentrations above 0.3%.¹⁵

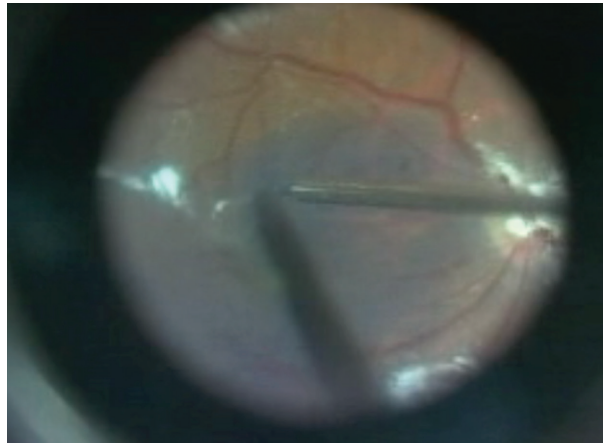


Figure 3. Intraoperative photograph of an epiretinal membrane stained with trypan blue. (Courtesy of Mauricio Maia, MD)

Internal Limiting Membrane

The ILM is made of the basement membrane of Müller cells representing an interface between the retina and the vitreous. The significance of ILM peeling is in achieving closure of large and chronic idiopathic MHs.¹⁹ Tangential traction from the ILM plays a key role in the pathogenesis of MH. In a post-mortem examination, the eye with successful MH closure was characterized by an area of absent ILM surrounding the sealed MH.²⁰ In contrast in another patient that had a re-opened MH, histopathological examination revealed an ERM with ILM surrounding the open MH suggesting that traction from the ILM was partly responsible for recurrence.²¹

In other conditions such as DME and ERM, ILM peeling has remained controversial. Surgical specimens often show fragments of the ILM interspersed among the ERM.²²⁻²⁴ Breaks in the ILM may provide access to the macular surface for cellular elements, thus ILM peeling may reduce the risk of recurrence following ERM removal. Even in cases with complete ERM removal, recurrences may occur. Therefore by removing the ILM as well, the surgeon can be assured that the ERM has been entirely removed. Thus ILM peeling has been proposed as a means to ensure complete removal of the ERM and to deter recurrence.^{13,25}

Visual improvement in 65% to 90% of eyes following ERM removal and a low recurrence rate of 5% with even fewer re-operations were

reported and these results were achieved without any ILM peeling.²⁶⁻²⁸ Sivalingam et al²³ reported that long segments of ILM removal led to a worse visual outcome compared to less ILM removal. In contrast, more recently Bovey et al²⁹ reported that the visual outcome of eyes in which the ERM had ILM remnants were significantly more satisfactory than eyes without ILM remnants in ERM.

Since the ILM consists of footplates of Müller cells, it is reasonable to assume that its removal may result in some type of injury. Electron microscopic evaluation of surgically removed ILM specimens revealed degenerated and necrotic Müller cell processes.³⁰ Mild damage to the vitreoretinal interface following ICG stained ILM removal has also been documented with electron microscopy.³¹ Given that ICG has been reported to cause retinal toxicity, it remains unclear whether this mild damage to the vitreoretinal interface is due to ICG or mechanical peeling of the ILM.⁴ ILM peeling causes a selective delay in the recovery of focal macular ERG b wave even 6 months after operation³² suggesting that some type of injury to the macular Müller cells occurs after ILM peeling, since these cells are responsible for generating the b wave in the electroretinogram. Tadayoni et al³³ coined the term "dissociated optic nerve fiber layer" to describe a peculiar fundus appearance following ERM stripping. In their series out of 100 eyes, 43% manifested numerous arcuate striae slightly darker than the surrounding retina in the direction of optic nerve fibers appearing 1 to 3 months postoperatively. They attributed these findings to ILM peeling. Mitamura et al^{34,35} used optical coherence tomography (OCT) to further characterize these findings as dimples limited to the retinal nerve fiber layer. More recently Clark and colleagues³⁶ described 3 to 5 dark striae radiating from the papilla to the macula in an arcuate fashion as early as 1 week to 1 month postoperatively on blue light autofluorescence and infrared reflectance imaging. Simultaneous OCT through the striae revealed focal areas of swelling in the arcuate retinal nerve fiber layer. These changes resolved spontaneously after a mean period of 2 months not resulting in worse

post-operative visual acuity as compared to eyes without such changes.³⁶ In some eyes, swelling of the arcuate retinal nerve fiber layer evolved into characteristic dimples of dissociated optic nerve fiber layer suggesting that both of these findings represent different time points on the same spectrum.³⁶ It appears that both dissociated optic nerve fiber layer and the arcuate swelling of the nerve fiber layer do not affect visual function. The exact cause of these phenomena is currently unclear. A number of factors including direct trauma by the surgical forceps as they grasp the ILM, subclinical trauma to the inner retina from Müller cell damage, and Müller cell degeneration have been speculated.^{36,37} More longitudinal studies are required to assess the clinical implications of these changes.

Park et al¹³ showed that ILM peeling did not have a detrimental effect on visual acuity. They compared the outcomes between 24 eyes that underwent pars plana vitrectomy with ERM peeling but not ILM peeling, with 20 eyes that had undergone pars plana vitrectomy with both ERM and ILM peeling. Of note, no ILM staining agent was used in their study. They reported that visual outcomes were similar between the two groups but that recurrence rate was much higher in eyes without ILM peeling. More recent studies have shown that ILM removal does not improve or worsen postoperative visual acuity.^{12,38} However, recurrence was reduced by ILM peeling.¹² Another purported advantage of ILM peeling is a higher likelihood of resolution of retinal striae.³⁹

Selective stains such as ICG and BBG have a high affinity for basal membranes such as the ILM and a low affinity for collagen tissues such as ERMs. When either dye is used to stain both layers before removing any tissue during surgery, the unstained ERM is clearly depicted against the ILM, which is stained blue or green (Figure 4). After ERM removal, accurate visualization of the ILM during macular surgery is difficult. Some surgeons re-stain the macula to visualize the remaining ILM but others do not. Even with a single BBG staining, up to two thirds of eyes will have residual ILM remnants after ERM.^{12,40,41} In a recent prospective study conducted by the Pan American Collaborative

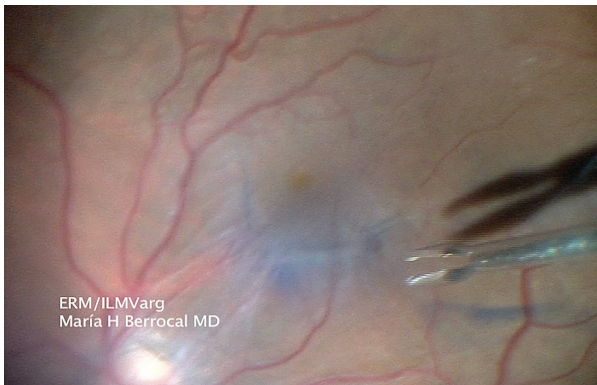


Figure 4. Use of brilliant blue G (BBG) during epiretinal membrane (ERM) removal. BBG only stains the internal limiting membrane (ILM) blue, but the unstained ERM is clearly depicted against the ILM. (Courtesy of María H Berrocal, MD)

Retina Study Group, there was little correlation between the surgeon's un-aided observation and the BBG stained observation of the ILM. Thus, if the surgeon believes in the significance of ILM peeling in ERM operation, staining should be strongly encouraged.⁴²

The first vital dye used for ILM staining was ICG.⁴³ Since ICG binds to the ILM, biomechanical stiffness of the ILM increases thus facilitating its peeling (Figure 5).⁴⁴ However the initial enthusiasm for the use of ICG has tempered following numerous reports of toxicity.^{4,45} A meta-analysis of chromovitrectomy with ICG compared to peeling of the ILM without staining in MH surgery showed similar anatomic

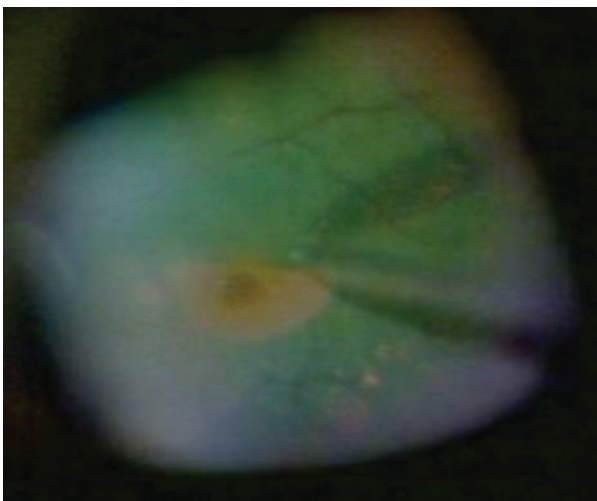


Figure 5. Intraoperative photograph of indocyanine green assisted peeling of the internal limiting membrane in an eye with idiopathic macular hole. (Courtesy of Mauricio Maia, MD)

outcomes in both groups. However the functional results in eyes in which the ILM was stained by ICG were much worse.⁴⁶

Several strategies can be used to minimize potential ICG toxicity. The lowest concentration of ICG which provides adequate visualization of the ILM should be used; concentrations of 0.5% or less are relatively safe. To avoid leaving excess ICG in the eye is of high importance to limit the area of ICG staining to the ILM that will be peeled. To protect the bare RPE of the MH floor, a small bubble of heavy perfluorocarbon liquid or viscoelastic is placed over the MH. Following partial fluid-air exchange, 1 to 2 drops of the ICG solution are placed over the macula for 30 to 60 seconds. Then the ICG is washed out and ILM peeling can be performed.

An alternative to ICG is infracyanine green which, unlike ICG, does not contain sodium iodide allowing it to be dissolved in 5% glucose and to generate an iso-osmotic solution. In vitro assays have shown that infracyanine green induced significantly less toxicity on RPE and retinal ganglion cell lines in comparison to ICG.⁴⁷ This toxicity was more time dependent rather than concentration dependent. When the duration of exposure approached 30 minutes, early apoptotic changes were observed in both cell lines, with no significant difference in apoptotic rates at 2 different concentrations (0.025% and 0.05%).⁴⁷ Several clinical investigations have revealed that infracyanine green assisted ILM peeling during MH repair results in high anatomic and functional success rates.⁴⁸⁻⁵⁰

BBG also has high affinity for the ILM. In animal and in vitro studies, BBG appears to be relatively safe at doses up to 0.25 mg/ml.⁴ BBG is not a fluorescent dye (Figure 6). Therefore there is remote possibility of light toxicity similar to ICG. Contact with the RPE should be avoided since RPE atrophy has been documented following subretinal migration of BBG. In general, BBG appears to be a safer alternative to ICG for ILM peeling. Furthermore, BBG can be beneficial as a neuroprotective agent.⁵¹ In vitro studies have shown that photoreceptors undergo apoptotic cell death when exposed to extracellular ATP through the activation of P2RX7 purinergic receptors. BBG is a P2RX7 antagonist and

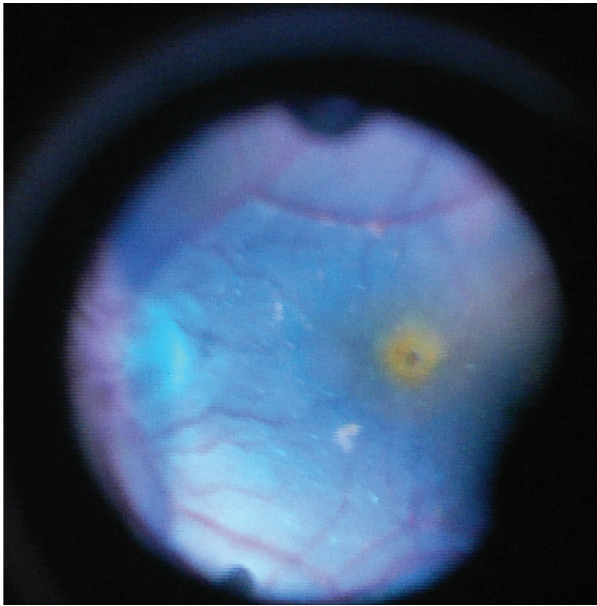


Figure 6. Intraoperative photograph of brilliant blue G staining of the internal limiting membrane in an eye with idiopathic macular hole.

prevents photoreceptor apoptosis as shown in cell culture studies.⁵¹

Identification of Hidden Retinal Breaks

Identification of all retinal breaks is of paramount importance for successful repair of a retinal detachment. On occasion a retinal break is not identified in an eye with a rhegmatogenous retinal detachment. Transretinal injection of TB into the subretinal space with a 41 gauge needle followed by heavy perfluorocarbon liquid injection into the vitreous cavity assists the identification of previously unclear retinal breaks.⁵²

Future Outlooks

At the present time, none of the commercially available staining agents is ideal. The research is persevering and numerous dyes including methyl violet, crystal violet, eosin Y, sudan black B, methylene blue, toluidine blue, indigo carmine, fast green, light green, congo red, bromophenol blue, patent blue and evans blue have been investigated.^{53, 54} An ideal dye should have excellent contrast and high biocompatibility.⁵⁵

German investigators have designed and tested 3,3'-Di-(4-sulfobutyl)-1,1,1',1' tetramethyl-di-1H-benz[e]indocarbocyanine (DSS) with good biocompatibility which can be a proper alternative for ILM staining.⁵⁵ On the other hand, Brazilian investigators argue that natural dyes may be safer alternatives than synthetic dyes.⁵⁶ They have investigated several naturally produced dyes and reported that acai fruit (*Euterpe oleracea*), logwood (*Haematoxylum campechianum*), cochineal (*Dactylopius coccus*) and old fustic (*Maclura tinctoria*) extracts facilitated posterior hyaloid visualization similar to triamcinolone acetate in cadaver eyes. Acai fruit (*Euterpe oleracea*), chlorophyll extract from alfalfa (*Medicago sativa*) and cochineal (*Dactylopius coccus*) extracts stained the ILM well in cadaver eyes.⁵⁶ Time will tell if any of these agents will end up in routine clinical use.

With the recent introduction of ocriplasmin, pharmacological vitreolysis is a reality.⁵⁷ The greatest advantage of enzymatic vitreolysis is that a cleaner cleavage plane between the retina and other tissues of interest may be achieved by enzymatic means as compared to mechanical separation by vitrectomy. In the future it is likely that enzymatic vitreolysis will play an even more significant role in the management of disorders of the vitreoretinal interface.

SUMMARY

Transparent tissues such as the posterior hyaloid, ERMs and the ILM play an important role in several diseases of the posterior pole. Surgical removal of these tissues is a principal objective which can be facilitated by staining with a variety of vital dyes. Several dyes are currently used in routine clinical procedures, however the ideal staining agent has not yet been found and any dye which is injected intravitreally has the potential to become toxic. In general, the lowest concentration of dye that will stain the tissue of interest should be used. The dye should also be placed for the shortest period of time to result in minimal color change as a faint stain is usually sufficient for peeling. Keeping the light pipe as far away as possible from the retinal surface should be encouraged particularly

when fluorescent dyes such as ICG are used. TA highlights the vitreous most ideally, and TB and BBG best stain ERMs and the ILM, respectively.

Conflicts of Interest

None.

REFERENCES

- Sebag J. Anomalous posterior vitreous detachment: a unifying concept in vitreo-retinal disease. *Graefes Arch Clin Exp Ophthalmol* 2004;242:690-698.
- Sebag J. Anatomy and pathology of the vitreo-retinal interface. *Eye (Lond)* 1992;6:541-552.
- Rodrigues EB, Meyer CH, Kroll P. Chromovitrectomy: a new field in vitreoretinal surgery. *Graefes Arch Clin Exp Ophthalmol* 2005;243:291-293.
- Farah ME, Maia M, Rodrigues EB. Dyes in ocular surgery: principles for use in chromovitrectomy. *Am J Ophthalmol* 2009;148:332-340.
- Abrams GW, Topping T, Machemer R. An improved method for practice vitrectomy. *Arch Ophthalmol* 1978;96:521-525.
- Schmidt JC, Chofflet J, Hörle S, Mennel S, Meyer CH. Three simple approaches to visualize the transparent vitreous cortex during vitreoretinal surgery. *Dev Ophthalmol* 2008;42:35-42.
- Fine HF, Spaide RF. Visualization of the posterior precortical vitreous pocket in vivo with triamcinolone. *Arch Ophthalmol* 2006;124:1663.
- Guo S, Tutela AC, Wagner R, Caputo AR. A comparison of the effectiveness of four biostains in enhancing visualization of the vitreous. *J Pediatr Ophthalmol Strabismus* 2006;43:281-284.
- Sousa-Martins D, Maia M, Moraes M, Lima-Filho AA, Rodrigues EB, Chen J, et al. Use of lutein and zeaxanthin alone or combined with Brilliant Blue to identify intraocular structures intraoperatively. *Retina* 2012;32:1328-1336.
- Wilkinson CP. Recurrent macular pucker. *Am J Ophthalmol* 1979;88:1029-1031.
- Grewing R, Mester U. Results of surgery for epiretinal membranes and their recurrences. *Br J Ophthalmol* 1996;80:323-326.
- Shimada H, Nakashizuka H, Hattori T, Mori R, Mizutani Y, Yuzawa M. Double staining with brilliant blue G and double peeling for epiretinal membranes. *Ophthalmology* 2009;116:1370-1376.
- Park DW, Dugel PU, Garda J, Sipperley JO, Thach A, Sneed SR, et al. Macular pucker removal with and without internal limiting membrane peeling: pilot study. *Ophthalmology* 2003;110:62-64.
- Feron EJ, Veckeneer M, Parys-Van Ginderdeuren R, Van Lommel A, Melles GR, Stalmans P. Trypan blue staining of epiretinal membranes in proliferative vitreoretinopathy. *Arch Ophthalmol* 2002;120:141-144.
- Farah ME, Maia M, Furlani B, Bottós J, Meyer CH, Lima V, et al. Current concepts of trypan blue in chromovitrectomy. *Dev Ophthalmol* 2008;42:91-100.
- Melles GR, de Waard PW, Pameyer JH, Houdijn Beekhuis W. Trypan blue capsule staining to visualize the capsulorhexis in cataract surgery. *J Cataract Refract Surg* 1999;25:7-9.
- Haritoglou C, Gandorfer A, Schaumberger M, Priglinger SG, Mueller AJ, Gass CA, et al. Trypan blue in macular pucker surgery: an evaluation of histology and functional outcome. *Retina* 2004;24:582-590.
- Li K, Wong D, Hiscott P, Stanga P, Groenewald C, McGalliard J. Trypan blue staining of internal limiting membrane and epiretinal membrane during vitrectomy: visual results and histopathological findings. *Br J Ophthalmol* 2003;87:216-219.
- Mester V, Kuhn F. Internal limiting membrane removal in the management of full-thickness macular holes. *Am J Ophthalmol* 2000;129:769-777.
- Funata M, Wendel RT, de la Cruz Z, Green WR. Clinicopathologic study of bilateral macular holes treated with pars plana vitrectomy and gas tamponade. *Retina* 1992;12:289-298.
- Fekrat S, Wendel RT, de la Cruz Z, Green WR. Clinicopathologic correlation of an epiretinal membrane associated with a recurrent macular hole. *Retina* 1995;15:53-57.
- Smiddy WE, Maguire AM, Green WR, Michels RG, de la Cruz Z, Enger C, et al. Idiopathic epiretinal membranes. Ultrastructural characteristics and clinicopathologic correlation. *Ophthalmology* 1989;96:811-820; discussion 821.
- Sivalingam A, Eagle RC Jr, Duker JS, Brown GC, Benson WE, Annesley WH Jr, et al. Visual prognosis correlated with the presence of internal-limiting membrane in histopathologic specimens obtained from epiretinal membrane surgery. *Ophthalmology* 1990;97:1549-1552.
- Trese M, Chandler DB, Machemer R. Macular pucker. II. Ultrastructure. *Graefes Arch Clin Exp Ophthalmol* 1983;221:16-26.
- Hisatomi T, Enaida H, Sakamoto T, Kagimoto T, Ueno A, Nakamura T, et al. A new method for comprehensive bird's-eye analysis of the surgically excised internal limiting membrane. *Am J Ophthalmol* 2005;139:1121-1122.

26. Margherio RR, Cox MS Jr, Trese MT, Murphy PL, Johnson J, Minor LA. Removal of epimacular membranes. *Ophthalmology* 1985;92:1075-1083.
27. de Bustros S, Thompson JT, Michels RG, Rice TA, Glaser BM. Vitrectomy for idiopathic epiretinal membranes causing macular pucker. *Br J Ophthalmol* 1988;72:692-695.
28. Poliner LS, Olk RJ, Grand MG, Escoffery RF, Okun E, Boniuk I. Surgical management of premacular fibroplasia. *Arch Ophthalmol* 1988;106:761-764.
29. Bovey EH, Uffer S, Achache F. Surgery for epimacular membrane: impact of retinal internal limiting membrane removal on functional outcome. *Retina* 2004;24:728-735.
30. Eckardt C, Eckardt U, Groos S, Luciano L, Reale E. [Removal of the internal limiting membrane in macular holes. Clinical and morphological findings]. *Ophthalmologie* 1997;94:545-551. [Article in German]
31. Nakamura T, Murata T, Hisatomi T, Enaida H, Sassa Y, Ueno A, et al. Ultrastructure of the vitreoretinal interface following the removal of the internal limiting membrane using indocyanine green. *Curr Eye Res* 2003;27:395-399.
32. Terasaki H, Miyake Y, Nomura R, Piao CH, Hori K, Niwa T, et al. Focal macular ERGs in eyes after removal of macular ILM during macular hole surgery. *Invest Ophthalmol Vis Sci* 2001;42:229-234.
33. Tadayoni R, Paques M, Massin P, Mouki-Benani S, Mikol J, Gaudric A. Dissociated optic nerve fiber layer appearance of the fundus after idiopathic epiretinal membrane removal. *Ophthalmology* 2001;108:2279-2283.
34. Mitamura Y, Ohtsuka K. Relationship of dissociated optic nerve fiber layer appearance to internal limiting membrane peeling. *Ophthalmology* 2005;112:1766-1770.
35. Mitamura Y, Suzuki T, Kinoshita T, Miyano N, Tashimo A, Ohtsuka K. Optical coherence tomographic findings of dissociated optic nerve fiber layer appearance. *Am J Ophthalmol* 2004;137:1155-1156.
36. Clark A, Balducci N, Pichi F, Veronese C, Morara M, Torrazza C, et al. Swelling of the arcuate nerve fiber layer after internal limiting membrane peeling. *Retina* 2012;32:1608-1613.
37. Haritoglou C, Gandorfer A, Kampik A. NFL appearance after peeling. *Ophthalmology* 2006;113:1690; author reply -1.
38. Pournaras CJ, Emarah A, Petropoulos IK. Idiopathic macular epiretinal membrane surgery and ILM peeling: anatomical and functional outcomes. *Semin Ophthalmol* 2011;26:42-46.
39. Chang S. Controversies regarding internal limiting membrane peeling in idiopathic epiretinal membrane and macular hole. *Retina* 2012;32:S200-S203.
40. Gandorfer A, Haritoglou C, Scheler R, Schumann R, Zhao F, Kampik A. Residual cellular proliferation on the internal limiting membrane in macular pucker surgery. *Retina* 2012;32:477-485.
41. Kifuku K, Hata Y, Kohno RI, Kawahara S, Mochizuki Y, Enaida H, et al. Residual internal limiting membrane in epiretinal membrane surgery. *Br J Ophthalmol* 2009;93:1016-1019.
42. Carpentier C, Zanolli M, Wu L, Sepulveda G, Berrocal MH, Saravia M, et al. Residual internal limiting membrane after epiretinal membrane peeling: results of the Pan-American Collaborative Retina Study Group. *Retina* 2013;33:2026-2031.
43. Burk SE, Da Mata AP, Snyder ME, Rosa RH Jr, Foster RE. Indocyanine green-assisted peeling of the retinal internal limiting membrane. *Ophthalmology* 2000;107:2010-2014.
44. Wollensak G. Biomechanical changes of the internal limiting membrane after indocyanine green staining. *Dev Ophthalmol* 2008;42:82-90.
45. Uemura A, Kanda S, Sakamoto Y, Kita H. Visual field defects after uneventful vitrectomy for epiretinal membrane with indocyanine green-assisted internal limiting membrane peeling. *Am J Ophthalmol* 2003;136:252-257.
46. Rodrigues EB, Meyer CH. Meta-analysis of chromovitrectomy with indocyanine green in macular hole surgery. *Ophthalmologica* 2008;222:123-129.
47. Balaiya S, Brar VS, Murthy RK, Chalam KV. Comparative in vitro safety analysis of dyes for chromovitrectomy: indocyanine green, brilliant blue green, bromophenol blue, and infracyanine green. *Retina* 2011;31:1128-1136.
48. Lanzetta P, Polito A, Del Borrello M, Narayanan R, Shah VA, Frattolillo A, et al. Idiopathic macular hole surgery with low-concentration infracyanine green-assisted peeling of the internal limiting membrane. *Am J Ophthalmol* 2006;142:771-776.
49. Rivett K, Kruger L, Radloff S. Infracyanine-assisted internal limiting membrane peeling in macular hole repair: does it make a difference? *Graefes Arch Clin Exp Ophthalmol* 2004;42:393-396.
50. Ullern M, Dubreuil F, Nourry H, Poisson F, Baudouin C. [Macular hole surgery with and without infracyanine-green-guided removal of the internal limiting membrane]. *J Fr Ophthalmol* 2007;30:53-57. [Article in French]

51. Notomi S, Hisatomi T, Kanemaru T, Takeda A, Ikeda Y, Enaida H, et al. Critical involvement of extracellular ATP acting on P2RX7 purinergic receptors in photoreceptor cell death. *Am J Pathol* 2011;179:2798-2809.
52. Jackson TL, Kwan AS, Laidlaw AH, Aylward W. Identification of retinal breaks using subretinal trypan blue injection. *Ophthalmology* 2007;114:587-590.
53. Rodrigues EB, Penha FM, Farah ME, de Paula Fiod Costa E, Maia M, Dib E, et al. Preclinical investigation of the retinal biocompatibility of six novel vital dyes for chromovitrectomy. *Retina* 2009;29:497-510.
54. Rodrigues EB, Penha FM, de Paula Fiod Costa E, Maia M, Dib E, Moraes M Jr, et al. Ability of new vital dyes to stain intraocular membranes and tissues in ocular surgery. *Am J Ophthalmol* 2010;149:265-277.
55. Haritoglou C, Kernt M, Laubichler P, Langhals H, Eibl K, Varja A, et al. Synthesis, staining properties, and biocompatibility of a new cyanine dye for ILM peeling. *Graefes Arch Clin Exp Ophthalmol* 2012;250:829-838.
56. Chen J, Ferreira MA, Farah ME, de Carvalho AM, Alves Ferreira RE, de Moraes Filho MN, et al. Posterior hyaloid detachment and internal limiting membrane peeling assisted by anthocyanins from acai fruit (*Euterpe oleracea*) and 10 other natural vital dyes: experimental study in cadaveric eyes. *Retina* 2013;33:89-96.
57. Stalmans P, Benz MS, Gandorfer A, Kampik A, Girach A, Pakola S, et al. Enzymatic vitreolysis with ocriplasmin for vitreomacular traction and macular holes. *N Engl J Med* 2012;367:606-615.