

Can bone marrow aspirate concentrate change the mineralization pattern of the anterior maxilla treated with xenografts? A preliminary study

ANDRÉ ANTONIO PELEGRINE, MARCELO LUCCHESI TEIXEIRA, MARCELO SPERANDIO, THIAGO SOUSA ALMADA, KARL ERIK KAHNBERG¹, PAULO JOSÉ PASQUALI, ANTONIO CARLOS ALOISE

Abstract

Objective: To evaluate bony reconstruction of the atrophic anterior maxilla using particulate grafts with or without autologous bone marrow aspirate concentrate (BMAC). **Materials and Methods:** Eight patients with atrophy of the anterior maxilla due to teeth loss were selected and split into groups according to the type of material used: Control Group (CG) ($n = 4$) - particulate xenograft only and Test Group (TG) ($n = 4$) - a combination of particulate xenograft and BMAC. Both groups received a collagen membrane to cover the xenograft. After 4 months, during implant placement, a sample of bone was removed from the graft area using a 2 mm diameter trephine bur. The specimens were fixed and preserved for histomorphometric evaluation, which included the following parameters: Mineralized tissue (MT) and non-MT (NMT). Cone beam computed tomography was performed at 3 time intervals to measure bone thickness: (1) Before grafting, (2) 4 months and (3) 8 months postgrafting, using localized bone gain (mm) as the outcome variable. **Results:** Tomographic analysis revealed bone gain in CG of 3.78 ± 1.35 mm and 4.34 ± 1.58 mm at 4 and 8 months, respectively. TG showed an increase of 3.79 ± 0.52 mm and 4.09 ± 1.33 mm after 4 and 8 months, respectively. Histomorphometric analysis revealed that, for CG, MT- and NMT-related values were $52.3\% \pm 16.78\%$ and $47.70\% \pm 5.55\%$, respectively, whereas for TG, they were $65.04\% \pm 20.98\%$ and 34.96 ± 10.38 , respectively. **Conclusion:** Although radiographic bone gain appeared similar between the groups, the use of BMAC obtained via the BMAC[®] method revealed an increased mineralization trend in the anterior maxilla. It must be highlighted, however, that this is a preliminary study with a relatively small sample population and further studies with larger sample sizes are needed to verify these results.

Keywords: Bone marrow, bone regeneration, stem cells

Introduction

Bone loss in the edentulous anterior maxilla is a common occurrence, with a 35% bone resorption rate expected within 6 months of teeth extraction.^[1] Loss of bone thickness precedes loss of height, which explains why appositional approaches aimed at thickness augmentation are the most prevalent.^[2] In appositional bone reconstructions, autologous bone grafts would be considered the gold standard.^[3] The morbidity associated with autologous bone grafting is, however, the main limitation of this technique for both the professionals, due to technical difficulties, and the patients, who remain reluctant

to undergo more invasive surgical procedures.^[2-4] On the other hand, the use of bone marrow as the source of cells in bony tissue engineering represents an alternative to traditional autologous bone grafting, since, in addition to showing good regenerative results, the risk of complications related to aspiration is 10 times lower than observed with the classic iliac crest grafts. At last, when complications do occur using the former approach, they are much less severe than the latter.^[5]

There are only very few studies in the literature reporting anterior maxillary reconstructions using particulate bone grafts, which hinders decision making by the surgeon in terms of the type of graft to use. Xenografts, which are available in a particulate form, are becoming a more viable option than autologous grafts, despite their inability to promote osteogenesis and osteoinduction, a frequent criticism regarding this approach.^[6]


A series of studies in experimental models attempted to associate particulate xenografts with cell therapy, aiming

Department of Implantology, São Leopoldo Mandic Institute and Research Center, Campinas, Brazil, ¹Department of Oral Surgery, University of Gothenburg, Gothenburg, Sweden

Correspondence: Prof. André Antonio Pelegrine,
Rua das Areias, 37, CEP 13024-530, São Paulo, Brazil.
E-mail: pelegrineandre@gmail.com

This is an open access article distributed under the terms of the Creative Commons Attribution-NonCommercial-ShareAlike 3.0 License, which allows others to remix, tweak, and build upon the work non-commercially, as long as the author is credited and the new creations are licensed under the identical terms.

For reprints contact: reprints@medknow.com

Access this article online	
Quick Response Code: 	Website: www.contempclindent.org
	DOI: 10.4103/0976-237X.177112

How to cite this article: Pelegrine AA, Teixeira ML, Sperandio M, Almada TS, Kahnberg KE, Pasquali PJ, *et al.* Can bone marrow aspirate concentrate change the mineralization pattern of the anterior maxilla treated with xenografts? A preliminary study. *Contemp Clin Dent* 2016;7:21-6.

to achieve osteogenesis and osteoinduction. The authors concluded that the bone marrow was the ideal source of cells, particularly in its concentrated form.^[6,7]

Therefore, the aim of the current study was to evaluate human bone reconstruction in the atrophic anterior maxilla, using particulate grafts with or without autologous bone marrow aspirate concentrate (BMAC).

Materials and Methods

This study was performed in the outpatient clinic of the Department of Implant Dentistry, São Leopoldo Mandic Dental School (Campinas, SP, Brazil), following approval by the research ethics committee (838.635/2014). Free and informed consent was obtained from all patients.

The inclusion criteria were patients lacking the four upper incisors, yet presenting both canines, who presented with no more than 3 mm of remaining alveolar ridge and needed anterior, maxillary implants. The patients committed to attending follow-up appointments and maintaining adequate oral hygiene. Patients with a history of neoplastic disease treated with radio or chemotherapy, pregnant or breastfeeding women, systemic diseases or treatments affecting bone homeostasis, allergy to components of the materials used, sinus pathologies, and smokers were excluded from the study.

Alveolar ridge thickness was measured using cone-beam computed tomography (CBCT, i-CAT Classic, Imaging Sciences International, Hatfield, PA, USA) in cross-sectional cuts of the generated images (Digital Imaging and Communications in Medicine-based data sets) at a resolution of 96 dpi, 14 bits grayscale, and 0.25 mm voxel size. The computed tomography (CT) unit was set at 120 kVp, 5 mA, and 20 s exposure.

Eight patients with a mean age of 52.4 ± 2.2 years were included in this study. All patients presented with an atrophic anterior maxilla for grafting before implant placement. The patients were randomly distributed using a web-based software available at www.randomization.com into two groups according to material used: Control Group (CG) ($n = 4$) particulate bone xenograft only (Bio-Gen granules 500–1000 μm Bioteck, Vicenza, Italy), and Test Group (TG) ($n = 4$) with particulate bone xenograft combined with bone marrow concentrate obtained via the BMAC method. Following the principles of guided bone regeneration (GBR), collagen membranes (Biocollagen Bioteck, Vicenza, Italy) were placed over the bone grafts in all maxillary augmentation procedures in both groups.

At the end of the study, all patients were dentally rehabilitated using osseointegrated implants and fixed prostheses.

Bone marrow aspirate concentrate method

According to the manufacturer's instructions, bone marrow was harvested and processed in the operating room using the BMAC system (Bone Marrow Procedure Pack; Harvest Technologies, Plymouth, MA, USA). Briefly, in an outpatient setting and using local anesthesia (2% xylocaine without a vasoconstrictor), 30 mL of bone marrow aspirate was obtained from all patients via a puncture 2 cm laterocaudally from the upper posterior iliac crest, using a bone marrow needle (included in the pack) and heparinized 30 mL syringes (1 mL of 5.000 U/mL heparin).

The 30 mL bone marrow-filled syringe was connected to a filter bag, to which 8 mL of Anticoagulant Citrate Dextrose (ACD-A) anticoagulant was added. Following homogenization, a new syringe was attached and the filtered 30 mL removed. The bone marrow aspirate was then transferred into specific process disposables, which were placed in a SmartPreP2 centrifuge. After 14 min of centrifugation, two phases were obtained within the tube, i.e., the plasma supernatant and the precipitated bone marrow cell concentrate [Figure 1a and b]. The plasma was removed using specific syringes provided in the kit; the cell concentrate was suspended and approximately 4 mL aspirated.

Surgical procedure

All patients were treated under local anesthesia (Mepiadre 2%, DFL, São Paulo, Brazil), and a full thickness flap was raised to provide access to the resorbed alveolar ridge. A carbide burr (Ar N 701 21 mm Jota Rotatory Instruments, Ruthi, Switzerland) was used for decortication with the aim of enhancing vascularization [Figure 2].

In both groups, the particulate bone graft was spread over the bone to cover the entire exposed area evenly, to achieve sufficient thickness [Figure 3].

In TG, the bone graft was mixed with bone marrow before placement at the site of the defect [Figure 4]. Both groups were covered with an equine collagen membrane. The flaps were repositioned to completely cover the grafts and subsequently sutured with interrupted single 4–0 nylon sutures.

Computed tomography analysis

All patients were scanned at three different intervals: (1) Baseline, or immediately before grafting; (2) 4 months after grafting; and (3) 8 months after the grafting procedure. For every CT slice, one tagged image file (TIF) image was generated. Assessment of the TIF images was performed using dedicated software (ImageJ; NIH, Bethesda, MD, USA) [Figure 5a-c].

Thickness was measured in three points (apical, middle, and coronal), and an average was made per site. All measurements were performed twice by a single experienced blinded

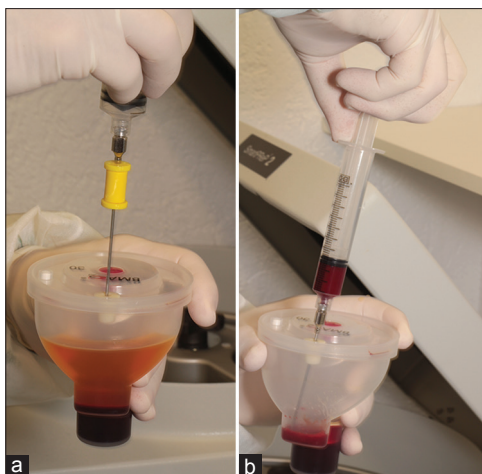


Figure 1: (a) Bone marrow after centrifugation (note the plasma supernatant being discarded); (b) aspiration of concentrated bone marrow cells

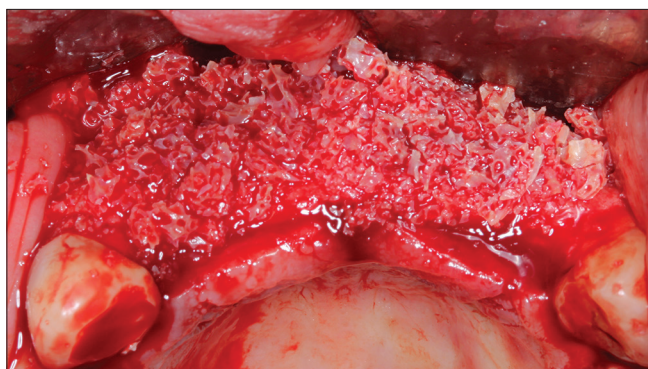


Figure 3: Graft in position

examiner andré antonio pelegrine (AAP), with a 15-day interval in between.

Bone biopsies: Clinical procedure and evaluation

Dental implant placement was performed 4 months after grafting [Figure 6a and b].

During the procedure, a cylindrical biopsy was retrieved from the implant placement site of each patient, using a trephine bur (2 mm internal Ø). The biopsies were routinely fixed, decalcified, dehydrated, embedded in paraffin, and sectioned. Four 7 µm sections were stained using Masson's Trichrome for histological and histomorphometrical analysis, representing the central aspect of each cylindrical biopsy. The relative quantity (%) of mineralized tissue (MT) and non-MT (NMT) were measured using the ImageJ software (NIH, Bethesda, MD, USA) [Figures 7a and b]. All histomorphometric analyses were performed twice by a single experienced blinded examiner antonio carlos aloise (ACA), with a 15-day interval in between.

Statistical analysis

Commercially available software (GraphPad Prism 6.0 for Windows, GraphPad Software Inc., La Jolla, CA, USA) was

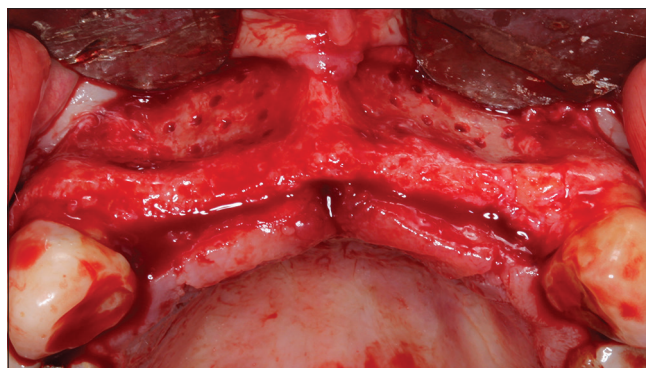


Figure 2: Surgical site following flap elevation and decortication



Figure 4: Xenograft combined with bone marrow aspirate concentrate

used to compare all assessed parameters and to create charts. Due to the small sample size, data were considered not conforming to a normal distribution. The Wilcoxon test was therefore used, at a significance level of $P < 0.05$.

Results

A minimum of two implants was placed in each previously grafted sites, all of which were osseointegrated and loaded after a 4-month healing period. At that point, the CT showed a gain in bone thickness of 3.78 ± 1.35 mm and 3.79 ± 0.52 mm for the CG and TG, respectively. After 8 months, the same areas recorded 4.34 ± 1.58 mm and 4.09 ± 1.33 mm for CG and TG, respectively [Table 1].

Regarding the histomorphometric analysis, CG showed values for MT and NMT of $52.3\% \pm 16.78\%$ and $47.70\% \pm 5.55\%$, respectively. TG showed values for MT and NMT of $65.04\% \pm 20.98\%$ and 34.961 ± 10.38 , respectively [Table 2].

Discussion

Alveolar bone atrophy is a common finding in the edentulous anterior maxilla,^[1,8] consequently generating a high demand

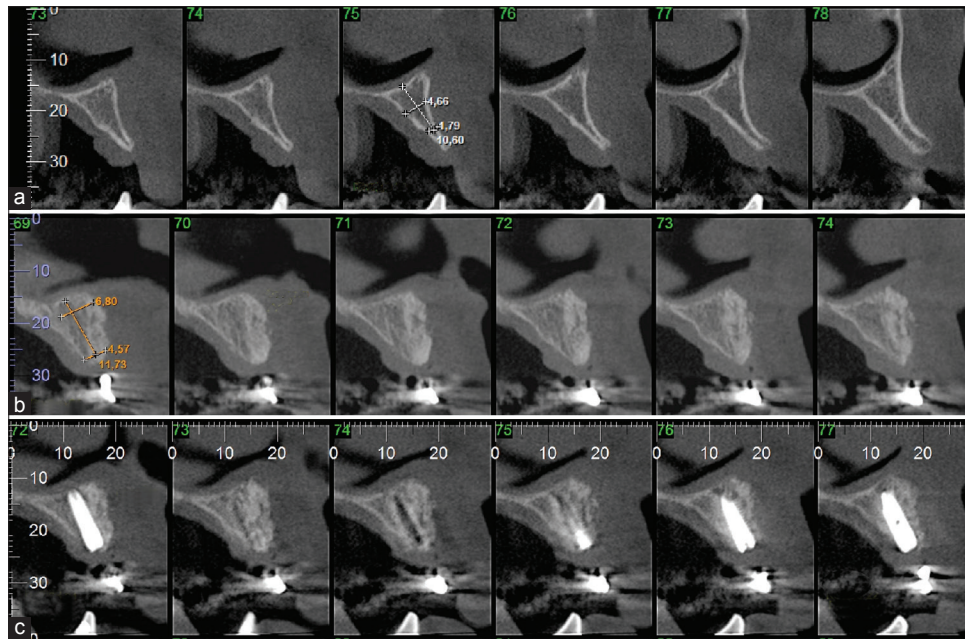


Figure 5: (a) Computed tomography image before treatment; (b) computed tomography image 4 months after treatment; (c) computed tomography image 8 months after treatment

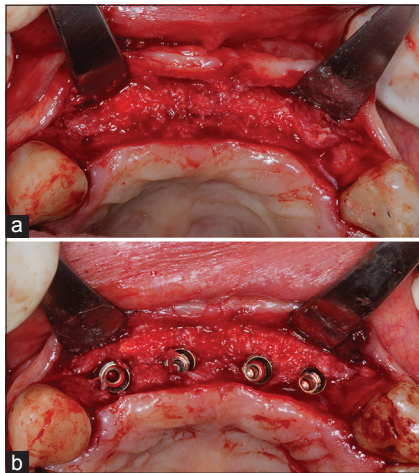


Figure 6: (a) Grafted site 4 months after reopening; (b) transoperative view, immediately after implant placement

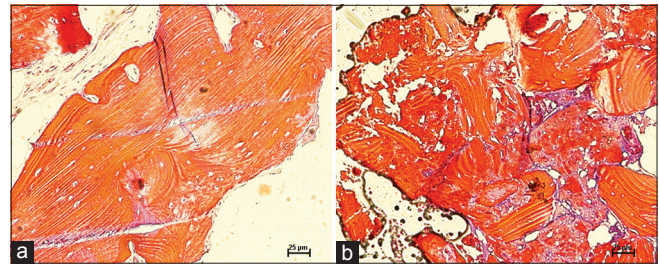


Figure 7: (a) Photomicrograph of a histological section stained with Masson's Trichrome, from the Control Group ($\times 100$); (b) photomicrograph of a histological slide stained with Masson's Trichrome from the Test Group ($\times 100$)

for bone reconstruction in this area prior to osseointegrated implant placement.^[9]

In the present study, all patients had an anterior maxillary bone thickness of < 3 mm and both groups presented a thickness gain of approximately 4 mm, which was confirmed using CT. This level of bone gain is comparable to other studies that focused on reconstruction of the anterior maxilla.^[10,11]

Some studies have evaluated the potential for bone regeneration using a combination of bone substitutes with GBR techniques. The latter technique was used in the present study since over the years, the use of membranes or tissue barriers has been shown to prevent the transfer of unwanted cells derived from adjacent soft tissues during the healing process.^[12-14]

CT analysis, both before (4 months after grafting) and after implant placement (8 months following grafting), revealed

Table 1: Bone thickness gain measured by computed tomography (in mm)

Group	4 months	8 months
Control group	3.78 \pm 1.35	4.34 \pm 1.58
Test group	3.79 \pm 0.52	4.09 \pm 1.33

Table 2: Histomorphometric analysis (%)

	CG	TG	P
MT	52.30 \pm 16.78	65.04 \pm 20.98	0.13
NMT	47.70 \pm 5.55	34.96 \pm 10.38	0.18

CG: Control group; TG: Test group; MT: Mineralized tissue; NMT: Nonmineralized tissue

no volumetric loss between these time intervals ($P > 0.05$). There was, in fact, a numeric gain between 4 and 8 months, which most likely occurred secondary to the expanding characteristic of the macro-engineering of the implants used.

Regarding the histomorphometric findings, no significant difference was observed in either NMT or MT levels between the groups ($P > 0.05$); however, a trend was observed for higher MT and lower NMT levels in TG. This could be justified by the presence of potentially osteogenic cells and growth factors with osteoinducing potential in the bone marrow, as reported by Pelegrine *et al.*^[6] and Aloise *et al.*^[15] According to Hermann *et al.*,^[16] the use of the closed BMAC system revealed findings similar to, or even better than those of more elaborate methods such as the isolation of mononuclear cells from the bone marrow using the FICOLL method. Sauerbier *et al.*^[17] stated that the closed BMAC system was an appropriate substitute for the open FICOLL system for bone regeneration procedures. Rickert *et al.* (2011)^[18] reported that the BMAC system could be used as an alternative to autologous bone grafting, therefore justifying its use in daily clinical practice. However, despite the fact of the low complications rate regarding bone marrow harvest, especially when compared to the autogenous bone graft harvest,^[5] it is important to consider that the use a xenograft without mixing it with the BMAC has, obviously, no complication related to a donor site. Therefore, the use of BMAC system associated to a xenograft has the advantage of achieving a higher mineralization pattern but still demands an invasive tissue harvest that may have repercussion in a routine clinical use.

In the present study, only the total MT was considered in detriment of the amount of vital and nonvital mineralized tissue. This decision was made based on the difficulty to distinguish between them in photomicrographs [Figure 7a and b]. Two factors may have contributed to this: (1) The staining method (Masson's Trichrome) not allowing such distinction based solely on difference in color, thus confusing the newly formed bone with residual graft particles; (2) the newly formed bone, which is normally disorganized and contains nucleated cell, and the residual graft particles, which show a lamellar pattern and do not contain any cell nuclei, did not match the histological images. The photomicrographs revealed images compatible with lamellar bone containing nucleated cells, which could relate to the presence of native bone within the trephine biopsy whereas the disorganized bone with no cell nuclei could be an artifact from tissue preparation. Such features hinder accurate segregation between vital and nonvital mineralized tissue.

Despite a trend showing higher MT when using the BMAC system, one must highlight that this is a preliminary study with a small study population and that there are not several studies investigating biomaterials combined with the

techniques described. Despite the fact that further larger studies are needed to validate such findings, it is important to state that the safety and efficacy of the procedure are proven and established in maxillofacial surgery, especially in areas of residual alveolar ridge resorption prior to implantation.^[19]

Conclusion

Although radiographic bone gain appeared similar between the groups, the use of concentrated bone marrow aspirate obtained via the BMAC system revealed a higher MT trend in maxillary reconstructions. It must be highlighted, however, that this is a preliminary study based on a small sample population and larger studies are needed to verify these results.

Acknowledgment

The authors wish to thank Dr. Adriana Zardo João, for harvesting the bone marrow used in this study.

Financial support and sponsorship

Nil.

Conflicts of interest

There are no conflicts of interest.

References

1. Pelegrine AA, da Costa CE, Correa ME, Marques JF Jr. Clinical and histomorphometric evaluation of extraction sockets treated with an autologous bone marrow graft. *Clin Oral Implants Res* 2010;21:535-42.
2. Jensen SS, Terheyden H. Bone augmentation procedures in localized defects in the alveolar ridge: Clinical results with different bone grafts and bone-substitute materials. *Int J Oral Maxillofac Implants* 2009;24 Suppl: 218-36.
3. Esposito M, Grusovin MG, Felice P, Karatzopoulos G, Worthington HV, Coulthard P. The efficacy of horizontal and vertical bone augmentation procedures for dental implants – A Cochrane systematic review. *Eur J Oral Implantol* 2009;2:167-84.
4. Garaicoa-Pazmiño C, Suárez-López del Amo F, Monje A, Catena A, Ortega-Oller I, Galindo-Moreno P, *et al.* Influence of crown/implant ratio on marginal bone loss: A systematic review. *J Periodontol* 2014;85:1214-21.
5. Hernigou P, Desroches A, Queinnee S, Flouzat Lachaniette CH, Poignard A, Allain J, *et al.* Morbidity of graft harvesting versus bone marrow aspiration in cell regenerative therapy. *Int Orthop* 2014;38:1855-60.
6. Pelegrine AA, Aloise AC, Zimmermann A, de Mello E Oliveira R, Ferreira LM. Repair of critical-size bone defects using bone marrow stromal cells: A histomorphometric study in rabbit calvaria. Part I: Use of fresh bone marrow or bone marrow mononuclear fraction. *Clin Oral Implants Res* 2014;25:567-72.
7. de Mello e Oliveira R, Pelegrine AA, Aloise AC, Ferreira LM. Xenograft impregnated with bone marrow mononuclear fraction for appositional bone regeneration in rabbit calvaria: A clinical and histomorphometric study. *Int J Oral Maxillofac Implants* 2014;29:962-8.
8. Lekovic V, Camargo PM, Klokkevold PR, Weinlaender M, Kenney EB, Dimitrijevic B, *et al.* Preservation of alveolar bone in extraction sockets using bioabsorbable membranes. *J Periodontol* 1998;69:1044-9.

9. Donos N, Kostopoulos L, Tonetti M, Karring T. Long-term stability of autogenous bone grafts following combined application with guided bone regeneration. *Clin Oral Implants Res* 2005;16:133-9.
10. Nissan J, Mardinger O, Calderon S, Romanos GE, Chaushu G. Cancellous bone block allografts for the augmentation of the anterior atrophic maxilla. *Clin Implant Dent Relat Res* 2011;13:104-11.
11. da Costa CE, Pelegrine AA, Fagundes DJ, Simoes Mde J, Taha MO. Use of corticocancellous allogeneic bone blocks impregnated with bone marrow aspirate: A clinical, tomographic, and histomorphometric study. *Gen Dent* 2011;59:e200-5.
12. Brugnami F, Then PR, Moroi H, Kabani S, Leone CW. GBR in human extraction sockets and ridge defects prior to implant placement: Clinical results and histologic evidence of osteoblastic and osteoclastic activities in DFDBA. *Int J Periodontics Restorative Dent* 1999;19:259-67.
13. Buser D, Brägger U, Lang NP, Nyman S. Regeneration and enlargement of jaw bone using guided tissue regeneration. *Clin Oral Implants Res* 1990;1:22-32.
14. Carpio L, Loza J, Lynch S, Genco R. Guided bone regeneration around endosseous implants with anorganic bovine bone mineral. A randomized controlled trial comparing bioabsorbable versus non-resorbable barriers. *J Periodontol* 2000;71:1743-9.
15. Aloise AC, Pelegrine AA, Zimmermann A, de Mello E Oliveira R, Ferreira LM. Repair of critical-size bone defects using bone marrow stem cells or autogenous bone with or without collagen membrane: A histomorphometric study in rabbit calvaria. *Int J Oral Maxillofac Implants* 2015;30:208-15.
16. Hermann PC, Huber SL, Herrler T, von Hesler C, Andrassy J, Keyv SV, *et al.* Concentration of bone marrow total nucleated cells by a point-of-care device provides a high yield and preserves their functional activity. *Cell Transplant* 2008;16:1059-69.
17. Sauerbier S, Stricker A, Kuschnierz J, Bühler F, Oshima T, Xavier SP, *et al.* *In vivo* comparison of hard tissue regeneration with human mesenchymal stem cells processed with either the FICOLL method or the BMAC method. *Tissue Eng Part C Methods* 2010;16:215-23.
18. Rickert D, Sauerbier S, Nagursky H, Menne D, Vissink A, Raghoobar GM. Maxillary sinus floor elevation with bovine bone mineral combined with either autogenous bone or autogenous stem cells: A prospective randomized clinical trial. *Clin Oral Implants Res* 2011;22:251-8.
19. Sauerbier S, Rickert D, Gutwald R, Nagursky H, Oshima T, Xavier SP, *et al.* Bone marrow concentrate and bovine bone mineral for sinus floor augmentation: A controlled, randomized, single-blinded clinical and histological trial – Per-protocol analysis. *Tissue Eng Part A* 2011;17:2187-97.