

POSTER PRESENTATION

Open Access

Linear scleroderma en coup the sabre, progressive facial hemiatrophy and Rasmussen encephalitis : a single disease spectrum?

M Morren^{1*}, C Despontin², C Wouters³

From 18th Pediatric Rheumatology European Society (PReS) Congress Bruges, Belgium. 14-18 September 2011

Background

Progressive hemifacial atrophy (PFH) and linear scleroderma en coup de sabre (LSCS) may be accompanied by neurologic symptoms and other extra-cutaneous manifestations.

Aim

To investigate and compare clinical/immune characteristics of patients with LSCS and PFH.

Methods

Retrospective study of 12 patients presenting at 2 pediatric dermatology clinics with linear scleroderma and/or hemifacial atrophy

Results

9 patients presented with LSCS, followed in 5 of them by progressive hemifacial atrophy (PFH) within 2 years.

3 patients presented with PFH, all 3 had additional scleroderma lesions. Their median(range) age at presentation was 8(4-17)yrs.

Extracutaneous manifestations were equally found in LSCS and PFH+LSCS patients. They comprised asymmetry of tooth arches/missing teeth(1), ophthalmologic problems (eyelid ptosis, enophthalmia, bilateral anterior uveitis and renal papillary asymmetry)(4), epileptic seizures with hyperintense signals on MRI and hypoperfusion on SPECT in 1 LSCS (fig) and 1 PFH patient, severe migraine attacks(2), polyarthritis(2), vitiligo(1), celiac disease(1).

ANA were found in 3 LSCS, 2 PFH+LSCS patients. Distinct oligoclonal IgG bands were found in CSF (not in blood) in patients with PFH and seizures. A skin biopsy in a PFH lesion showed fibrosis associated with a lymphocytic infiltrate, IgM and IgG deposits. A brain biopsy in one PFH patient with epilepsy was consistent with Rasmussen encephalitis.

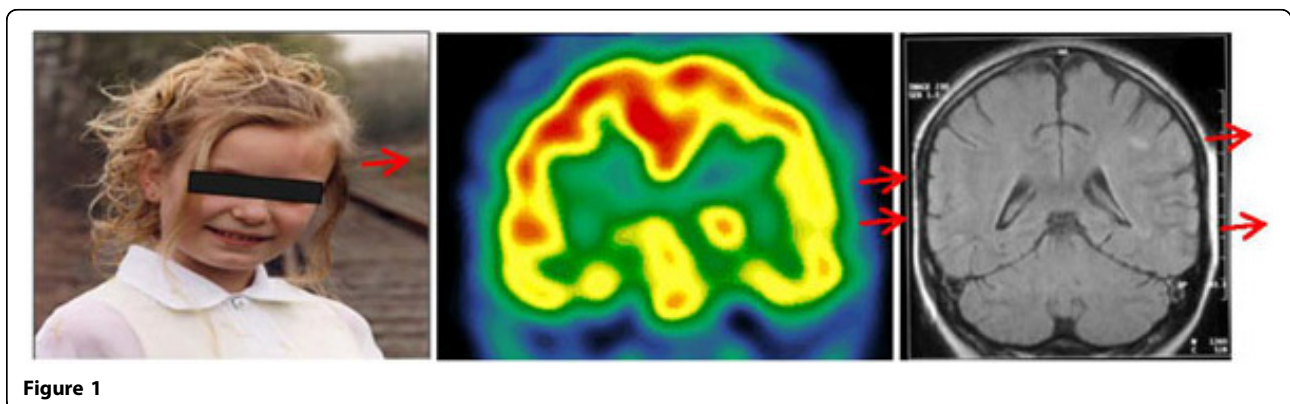


Figure 1

¹Dept of Pediatric Dermatology, Leuven University Hospital, Belgium
Full list of author information is available at the end of the article

In patients with severe skin +/- neurological lesions, treatment with steroids/high-dose MTX resulted in improvement/stabilization of clinical and MRI abnormalities

Conclusion

Our case series endorses the concept of a single disease spectrum encompassing LSCS and PFH, with a common immune-inflammatory pathogenesis. A possible relationship with RE is suggested as well.

Author details

¹Dept of Pediatric Dermatology, Leuven University Hospital, Belgium. ²Dept of Pediatric Dermatology, Children's Hospital Luxembourg. ³Pediatric Rheumatology, Leuven University Hospital, Belgium.

Published: 14 September 2011

doi:10.1186/1546-0096-9-S1-P79

Cite this article as: Morren *et al.*: Linear scleroderma en coup de sabre, progressive facial hemiatrophy and Rasmussen encephalitis : a single disease spectrum? *Pediatric Rheumatology* 2011 **9**(Suppl 1):P79.

Submit your next manuscript to BioMed Central
and take full advantage of:

- Convenient online submission
- Thorough peer review
- No space constraints or color figure charges
- Immediate publication on acceptance
- Inclusion in PubMed, CAS, Scopus and Google Scholar
- Research which is freely available for redistribution

Submit your manuscript at
www.biomedcentral.com/submit

